



Original Research Article

Computed tomographic study of sphenoid sinus and its septations

Kuldeep Kumar¹, Pooja Gautam^{2,*}, A P Mishra³, C S Ramesh Babu⁴¹Dept. of Anatomy, Government Medical College, Kannauj, Uttar Pradesh, India²Dept. of Anatomy, Autonomous State Medical College, Basti, Uttar Pradesh, India³Dept. of Radiology, Rama Mediacal University, Uttar Pradesh, India⁴Dept. of Anatomy, Muzaffar Nagar Medical College, Muzaffarnagar, Uttar Pradesh, India

ARTICLE INFO

Article history:

Received 02-07-2019

Accepted 21-08-2019

Available online 12-10-2019

Keywords:

Sphenoid sinus

Morphometric study

Pattern

Septations

ABSTRACT

Introduction: Knowledge of sphenoid sinus anatomy and its variations is of prime importance in trans-sphenoidal endoscopic skull base surgery.**Aim:** The aim of the present study was to measure the bilateral sphenoidal sinus parameters [depth, width, and height] and determine the number and pattern of attachments of intra-sphenoid sinus septations in 52 subjects by computed tomography.**Materials and Methods:** Cranial computed tomographic images of 52 normal subjects were included in our study. Four cases in whom the septations were absent were excluded from the measurement of dimensions of the sinus. The depth, width, and height in 48 sphenoidal sinuses were measured electronically. The coronal and axial sections were taken and subsequently examined.**Results:** The mean depth, width, and height of sphenoid sinus in males on right side are 2.2458cm, 1.555cm, 1.9044 cm and on left side are 2.3877cm, 1.6519cm, 1.8613cm and in females on right side are 2.0475cm, 1.6258cm, 2.05cm and on left side are 2.066cm, 1.2891cm and 1.7941 cm respectively. We noted single septum in 75 % cases, double septa in 11.53 % case, multiple septa in 5.76% cases and absence of septa in 7.69% cases.**Conclusion:** Anatomical knowledge of sphenoid sinus and its variations in size, pneumatization, intra-sphenoid sinus septations and its relationship with the surrounding vital structures is prime importance before performing any endoscopic/open surgery involving skull base via trans-sphenoidal approach. Thus preoperative CT is mandatory to avoid injuries to the closely related structures of the walls of the sinus.

© 2019 Published by Innovative Publication.

1. Introduction

Right and left sphenoid sinuses are usually asymmetrical and lie within the body of sphenoid bone posterosuperior to the nasal cavity and separated by a bony septum which is generally not in the midline. Each sinus drains anteriorly into sphenoidal recess of the nasal cavity.¹ The development of sphenoid sinus starts between 3rd and 4th month of fetal development. Between birth and 3 years of age, the sphenoid sinus is merely a pit in the

sphenoidal recess.^{2,3} Pneumatization of sphenoid starts at the age of 3 years and extends towards sella turcica by the age of 7 years, and reaches its final

form by the age of 14 years.³ Relations of the sinus are surgically important specially during trans-sphenoidal hypophysectomy. The anterior part of the roof, the jugum sphenoidale, is related to the optic chiasma while the posterior part of the roof, the sella turcica, is related to the pituitary gland. Each lateral wall is related to the cavernous sinus, internal carotid artery, maxillary nerve, and Vidian nerve (nerve of pterygoid canal).¹ The sphenoid sinus shows multitude of variations in degree of pneumatization, size and pattern of septations leading to differences in its segmentation.^{4,5} Intra-sphenoid sinus septations (intersinus septa) which can be absent, single or multiple, complete or incomplete, thin or thick divide the sphenoid sinuses into two or more compartments.^{6,7} The number of septa

* Corresponding author.

E-mail address: drkuldeep15579@gmail.com (P. Gautam).

varies from one to nine and in this study multiple septa were noted in 78.04 % cases.⁸ These septations are often deviated to one side attaching to the bony wall covering various vital structures.⁹ Preoperative knowledge of septal attachment especially to posterolateral bony walls covering vital structures is of utmost importance for a safe trans-sphenoidal approach for various surgical procedures involving skull base.^{10,11} The accurate knowledge of surrounding structures and anatomical variations of size, septations and pneumatization of sphenoid sinus is a necessary requisite during transsphenoidal endoscopic skull base surgery. The aim of the our research work was to measure the maximum depth, width, height of the sinus in both coronal and axial images of computed tomography and observe the number and type of attachment of the septa to the wall of sinus.

2. Materials and Methods

The cranial computed tomographic study was conducted on 52 subjects (39 males and 13 females) between the age of 25 to 65 years, in the Department of Anatomy, Government Medical college Kannauj (UP) and Study data taken from Radiodiagnosis center of Rama Dental College and hospital, Lakhanpur- Kanpur. Individuals with previous surgery involving skull base or sphenoid sinus, fractures around skull base or space occupying lesions around skull base or sphenoid sinus were excluded from the study. In four cases in which the septa were absent, bilateral size measurements of those sinuses were not done.

Depth {Antero-posterior diameter (APD)}, Width {Transverse diameter (TD)}, Height {Cranio-caudal diameter (CCD)} were measured electronically with a computed tomography machine (model Somatom Emotion, Max.kvp130,max.mA/Max.mAs180 and ID- G-XL-95033). The maximum Cranio-caudal diameter (CCD) diameter is measured in coronal sections (Figure 1) and Antero-posterior diameter (APD) and Transverse diameter (TD) are measured in axial sections (Figure 2). We also analysed the CT images for the number of intrasinus septations and their attachment to the wall of sinus. The axial and coronal sections were taken at the interval of 1.5 mm.

In coronal images maximum height measured from roof to bottom of the sinus and in axial images, maximum antero-posterior diameter measured from anterior and posterior inner bony walls of the sinus and maximum width by media l and lateral inner bony walls of the sinus.

3. Results

In the current study, the mean depth, width and height in females are found to be marginally less in comparison to males and are given in Table 1. We observed a single intersinus septum (complete and incomplete) in 75 % cases, double septa (one complete & one incomplete and both

incomplete) in 11.53 % cases, more than two septa in 5.76% cases and absence of septum in 7.69 % cases (Table 2). We did not observe any case having both complete septa or case having more than three septa. Double septa were found in 6 cases out of which in 3 cases one complete and one incomplete septum were seen. In 3 cases both septa were incomplete. Out of the three complete septa, two were attached to the right posterolateral wall and one to the posterior wall. Of the incomplete septa, 3 were attached to the right posterolateral wall, 3 to the left lateral wall, 2 to the left posterolateral wall and 1 to the right lateral wall (Figure 4). In 3 cases multiple septa (more than 2) were found, out of which 3 complete and 6 incomplete septa were noted. Three septa were attached to left lateral wall, 3 to the right lateral wall, 2 to the right postero-lateral wall and 1 septum attached to posterior wall of the sinus. The pattern of attachment of the single inter-sinus septum found in 39 cases is compiled in Table 3. In majority of the cases (38.46 %) the septum is attached to the posterior wall.

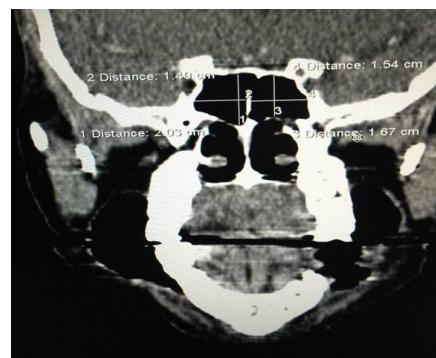


Fig. 1:

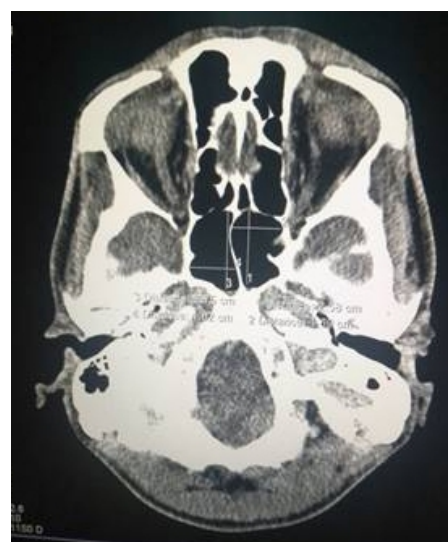

Fig. 2:

Table 1: Mean depth, width and height of sphenoid sinus in males and females

| Parameter | Male (n=36) | | Female (n=12) | |
|--------------|-------------|--------|---------------|--------|
| | Mean | SD | Mean | SD |
| Right Depth | 2.245cm | 0.5316 | 2.047cm | 0.8025 |
| Left Depth | 2.387cm | 0.6632 | 2.006cm | 0.5182 |
| Right Width | 1.555cm | 0.3240 | 1.625cm | 0.515 |
| Left Width | 1.652cm | 0.4950 | 1.289cm | 0.3784 |
| Right Height | 1.904cm | 0.4281 | 2.05 cm | 0.2987 |
| Left Height | 1.861cm | 0.4281 | 1.794cm | 0.3235 |

Table 2: Showing the number of sphenoid sinus septations and their percentage

| Number of Septations | Number of cases (N=52) (%) |
|--|----------------------------|
| Single and complete | 27 (51.92%) |
| Single and incomplete | 12 (23.07%) |
| Double and complete | 00 (0%) |
| Double septa (one complete and the other one incomplete) | 03 (5.76%) |
| Double septa (both incomplete) | 03 (5.76%) |
| More than two septa | 03 (5.76%) |
| Absent | 04(7.69%) |

Table 3: Showing the pattern of attachment of single septum to sphenoid sinus wall

| Type of attachment to the wall of sphenoid sinus | Number of Subjects (N= 39) (%) |
|--|--------------------------------|
| Posterior wall | 15 (38.46%) |
| Right posterolateral wall | 08 (20.51%) |
| Left postero lateral wall | 04 (10.25%) |
| Right lateral wall | 05 (12.82%) |
| Left lateral wall | 07 (17.94%) |

Table 4: Showing comparative differences of parameters of our study with that of others

| Parameter | Present study (n=48) (Mean \pm SD) cm | | Hasan & Faruqi 13 (Mean \pm SD) cm | Sareen et al 14 (Mean) cm |
|--------------|---|--------------------|---|---------------------------|
| | Male | Female | | |
| Right depth | 2.245 \pm 0.5316 | 2.047 \pm 0.8025 | 2.25 \pm 0.72 | 2.5 |
| Left depth | 2.387 \pm 0.6632 | 2.006 \pm 0.5182 | 1.90 \pm 0.98 | |
| Right width | 1.555 \pm 0.3240 | 1.625 \pm 0.5150 | 1.10 \pm 0.43 | 2.8 |
| Left width | 1.651 \pm 0.4950 | 1.289 \pm 0.3784 | 0.75 \pm 0.23 | |
| Right height | 1.904 \pm 0.4281 | 2.05 \pm 0.298 | 1.25 \pm 0.65 | 2.2 |
| Left height | 1.861 \pm 0.4281 | 1.794 \pm 0.3235 | 1.01 \pm 0.63 | |

4. Discussion

The sphenoid bone consists of a body and paired greater and lesser wings and pterygoid processes. Sphenoid sinus is formed in the body of sphenoid bone and is located at the skull base at the junction of anterior and middle cranial fossae. It separates the cavernous sinuses, the cavernous segments of internal carotid arteries and the oculomotor, trochlear, abducent and trigeminal nerves. In addition, it separates the pituitary gland from the nasal cavity.²⁰

An essential prerequisite for successful performance of endoscopic surgeries of skull base by trans-sphenoidal approach is accurate anatomical knowledge of sphenoid sinus variations in its size, intra-sphenoid septations, degree of pneumatization, relationship with the surrounding neurovascular structures and pituitary gland.¹⁰ Computed

tomography is considered as the gold standard for evaluation of paranasal sinuses. Preoperative analysis of the sphenoid sinus, its septations and their attachments especially to bony walls related to neurovascular structures like internal carotid artery, optic nerve, Vidian nerve and maxillary nerve, protrusions and bony dehiscence exposing the neurovascular structures to risk of injury will greatly help in proper planning to avoid the surgical complications.

In our study we measured the size of sphenoid sinus (depth, width and height) and observed the number of septa and their pattern of attachments to the sinus wall. Only few authors have done cadaveric and radiological morphometric study of sphenoid sinus. In our study all the dimensions of the sphenoid sinus in females is less than that of the males. In males the mean depth, width and height of the sphenoid

Table 5: Showing comparison of septation pattern of sphenoid sinus observed in various studies

| Author | Number of cases | Modality of study | Absent septum | Single septum (Complete+ Incomplete) | Double septa (Complete+ Incomplete) | Multiple septa (Complete+ Incomplete) |
|---------------------------------------|-----------------|-------------------|---------------|--------------------------------------|-------------------------------------|---------------------------------------|
| Wani et al (2019) ¹² | 591 | NCCT | 5.9% | 79.7% | 11% | 3.4% |
| Lokwani et al (2018) ¹³ | 260 | CT | 2.3% | 79.6 1 % | 18.1% | - |
| Wiebracht Zimmer (2014) ¹⁴ | 90 | HRCT | 4% | 75% | 3% | - |
| Hamid et al (2008) ⁷ | 296 | CT / MRI | 10.8% | 71.6% | 10.8% | 6.8% |
| Sareen et al (2005) ¹⁵ | 20 | Cadaveric | - | 20% | - | 80% |
| EL Kammash et al (2014) ¹⁶ | 182 | CT /MRI | 13.2 % | 59.89 % | 7.14 % | 5.49 % |
| Dundar et al (2014) ¹⁷ | 218 | CT | 2.2 % | 90.7 % | 6.8 % | - |
| Kashyap et al (2017) ¹¹ | 80 | CT | 5.0 % | 67.5 % | 21.25 % | 6.25 % |
| Battal et al (2014) ¹⁸ | 314 | CT | 1.3 % | 64.3 % | 20.1 % | 14.0 % |
| Ngubane et al (2018) ¹⁹ | 40 | Cadaveric | 7.5 % | 65.0 % | 22.5 % | - |
| Banna & Olutola (1983) ⁶ | 70 | Cadaveric | 11.4 % | 61.0 % | 14.0 % | 12.8 % |
| Present study (2019) | 52 | CT | 7.69% | 75% | 11.53% | 5.76% |

Table 6: Showing comparative differences of attachment of septations to sphenoid sinus wall and their percentage

| Type of attachment to the wall of sphenoid sinus | Our study (N = 39) (%) | Wani AH et al 17 Number of individuals (N = 591) (%) |
|--|------------------------|--|
| Posterior wall(sellar) | 15(38.46%) | 284 (51.0%) |
| Right posterol-ateral wall(post. wall & Right ICA) | 08(20.51%) | 21 (3.8%) |
| Left postero-lateral wall(post. wall & let ICA) | 04(10.25%) | 45 (8.1%) |
| Right lateral wall(right ICA) | 05(12.82%) | 36 (6.5%) |
| Left lateral wall(left ICA) | 07(17.94%) | 128 (23.0%) |
| Lateral wall | - | 23 (4.1%) |
| Lateral wall and carotids | - | 17 (3.1%) |
| Optic nerve | - | 2 (0.4%) |

sinus on the right side were 2.24 cm, 1.55 cm and 1.90 cm and on the left side were 2.38 cm, 1.65 cm and 1.86 cm respectively. The same measurements in females on the right side were 2.04 cm, 1.62 cm and 2.05 cm and on the left side were 2.00 cm, 1.28 cm and 1.79 cm respectively (Table 1). Other authors did not separately measure the sphenoid sinus in males and females.^{15,21} The comparative data is given in Table 4. Awadalla et al (2015) in their radiological study indicated that the mean length (depth) in the upperpart of the sinus was 1.39 cm and lower part was 2.59 cm and mean vertical height in the anterior part was 1.89 cm and posterior part was 1.21 cm.²²

We studied the number of septa, complete and incomplete, present in the sphenoid sinus dividing it into

compartments. Single inter-sinus septum was seen in 39 cases (75.0%), double septa in 6 cases (11.53%), more than two septa in 3 cases (5.76%). Absence of septa was observed in 4 cases (7.69%). Incidence of a single inter-sinus septum as reported in the literature is highly variable with a low of 20% cases reported by Sareen et al (2005)¹⁵ and a high of 90.7 % reported by Dundar et al (2014).¹⁷ Values of single septum quoted by Wani et al (2019),¹² Lokwani et al (2018),¹³ Wiebracht et al (2014),¹⁴ Hamid et al (2008)⁷ are similar to our study. Slightly lesser incidence of single septum was observed by EL Kammash et al (2014),¹⁶ Kashyap et al (2017),²⁰ Battal et al (2014),¹⁸ Ngubane et al (2018)¹⁹ and Banna et al (1983).⁶ Absence of inter-sinus septum was observed only in 1.3 % cases by

Battal et al (2014)¹⁸ in contrast to this EL Kammash et al (2014)¹⁶ noted it in 13.2 % cases. These comparative data are compiled in Table- 5.

We compared the attachments of the septa to the wall of sinus with the study of *Wani*) In our study we have made an attempt to provide useful information about the variations in size, number of septations and their attachment pattern to the wall of sinus and show how this information is useful prior and during endoscopic/open surgery involving skull base via trans-sphenoidal approach to an endoscopic neurosurgeon.

5. Conclusion

Variability in the morphology and number and pattern of intrasphenoidal

septations of the sphenoidal sinus has practical significance during or prior surgical procedures conducted by endoscopic neuro surgeon. Thus a thorough preoperative assessment of relevant surgical anatomy of sphenoid sinus by computed tomography is necessary to avoid damage of vital structures lying around the sinus.

6. Source of funding

None.

7. Conflict of interest

None.

References

- Hopkins C. Nose, nasal cavity and paranasal sinuses. In Standring S. In: Anatomy G, editor. The Anatomical basis of clinical practice. Elsevier ; 2016., p. 567–567.
- Aoki S, Dillon WP, Barkovich AJ, Norman D. Marrow conversion before pneumatization of the sphenoid sinus: Assessment with MR imaging. *Radiol*. 1989;172(2):373–375.
- Budu V, Mogoant CA, Fnu B, Bulescuthe I. Anatomical relations of the sphenoid sinus and their implications in sphenoid endoscopic surgery. *Rom J Morphol Embryol*. 2013;54(1):13–16.
- Simonetti G, Meloni F, Teatini G, Salvolini U, Rovasio S, et al. Computed tomography of the ethmoid labyrinth and adjacent structures. *Annals Otol Rhinol Laryngol*. 1987;96(3):239–259.
- Yune HY, Holden RW, Smith JA. Normal variations and lesions of the sphenoid sinus. *Am J Roentgenol*. 1975;124(1):129–138.
- Banna M, Olutola PS. Patterns of pneumatization and septation of the sphenoidal sinus. *J Canad Assoc Radiol*. 1983;34(4):291–293.
- Hamid O, L EF, Hassan O, Kotb A, Fiky SE. Anatomic variations of the sphenoid sinus and their impact on trans-sphenoid pituitary surgery. *Skull Base*. 2008;18(01):9–15.
- Jaworek-Troc, Zarzecki M, Mroz I. The total number of septa and antra in the sphenoid sinuses - evaluation before FESS. *Folia Medica Cracoviensia*. 2018;LVIII(3):67–81.
- Abdullah BJ, Arasaratnam S, Kumar G, Gopala K. The sphenoid sinuses: computed tomographic assessment of septation, relationship to the internal carotid arteries, and sidewall thickness in the Malaysian population. *J HK Coll Radiol*. 2001;4:185–188.
- Shah NJ, Navnit M, Deopujari CE, Mukerji SS. Endoscopic pituitary surgery-a. beginners guide. *Indian J Otolaryngol Head Neck Surg*. 2004;56(1):71–78.
- Kashyap SK, Purohit JP, Selvaraj S. Anatomical variations of sphenoidal inter-sinus septa in terms of number and attachment- A CT finding. *J Evol Med Dent Sci*. 2017;6(12):955–959.
- Wani AH, Sheikh Y, Parry AH, Qayoom Z. Anatomical variations of intra-sphenoid sinus septations in a sample of Kashmiri populations: a non-contrast computed tomography study. *Int J Res Med Sci*. 2019;7(5):1445–1449.
- Lokwani MS, Patidar J, Parihar V. Anatomical variations of sphenoid sinus on multi-detector computed tomography and its usefulness in trans-sphenoidal endoscopic skull base surgery. *Int J Res Med Sci*. 2018;6(9):3063–3071.
- Wiebracht ND, Zimmer LA. Complex anatomy of the sphenoid sinus: a radiographic study and literature review. *J Neurol Surg B Skull Base*. 2014;75(6):378–382.
- Sareen D, Agarwal AK, Kaul JM, Sethi A. Study of sphenoid sinus anatomy in relation to endoscopic surgery. *Int J Morphol*. 2005;23(3):261–266.
- Kammash TH, Enaba MM, Awadalla AM. Variability in sphenoid sinus pneumatization and its impact upon reduction of complications following sellar region surgeries. *Egyptian J Radiol Nuc Med*. 2014;45:705–714.
- Dundar R, Kulduk E, Soy FK. Radiological evaluation of septal bone variations in the sphenoid sinus. *J Med Updates*. 2014;4:6–10.
- Battal B, Akay S, Karaman B. The relationship between the variations of sphenoid sinus and nasal septum. *Gulhane Tip Derg*. 2014;56:232–237.
- Ngubane NP, Rennie LL, Satyapal CO, KS. The septation of the sphenoidal air sinus. A cadaveric study. *Int J Morphol*. 2018;36(4):1413–1422.
- Endoscopic pituitary and skull base surgery: Anatomy and surgery of the endoscopic endonasal approach. Germany: Endo Press ; 2016., p. 12.
- Hasan SA, Faruqi NA. A morphometric study of sphenoidal sinus. *Indian J Otolaryngol*. 1984;36(1):23–25.
- Awadalla A, Hussein Y, Kammash E, TH. Anatomical and radiological parameters of the sphenoid sinus among Egyptians and its impact on sellar region surgery. *Egyptian J Neurosurg*. 2015;30(1):1–12.

Author biography

Kuldeep Kumar Assistant Professor

Pooja Gautam Assistant Professor

A P Mishra Professor

C S Ramesh Babu Associate Professor

Cite this article: Kumar K, Gautam P, Mishra AP, Ramesh Babu CS. Computed tomographic study of sphenoid sinus and its septations. *Indian J Clin Anat Physiol* 2019;6(3):325-330.