

Extra pulmonary tuberculosis: An anatomical perspective

Mani Kathapillai

Associate Professor, Shri Sathya Sai Medical College and Research Institute, Sri Balaji Vidyapeeth Deemed To Be University, Tamil Nadu, India

***Corresponding Author: Mani Kathapillai**

Email: mani@sssmcri.ac.in

Received: 14th February, 2019

Accepted: 22nd February, 2019

Abstract

Introduction: Extra-pulmonary Tuberculosis (EPT) amounts to about forty percent (40%) of the total epidemiology of Tuberculosis (TB). Detailed data of various systems and organ involvement of EPT is the objective of this article.

Materials and Methods: Data of the EPT were collected from Indian Journal of Tuberculosis (IJT) since 2010-2016 for a period of 7 years. Details of age, side of lesion, affected sex and immune status were recorded in an excel sheet. The data were analyzed using Microsoft Excel 2007, SPSS version 23 software.

Results: Total cases reported were 428, between 3-84 years. Females (220) were affected more than the males (186); genders of 22 cases were not specified. Genitourinary system was predominantly affected by EPT (213cases). Patients aged between 21- 40 were affected in highest percentage (69.39%) versus genitourinary system with a significant p-value of 0.000. Females were affected by EPT more than males with predominant involvement of the left side with a significant p-value of 0.000. Conclusion: This study provides significant information about the EPT with respect to the number of cases reported in a specified period and their age, gender, most common side of the disease. This study also highlights the predominant system involved by EPT and also the affected rare organs like tongue, clavicle, conjunctiva and breast.

Keywords: Extra-pulmonary tuberculosis, Systems involved, Rare organs.

Introduction

The Extra-Pulmonary Tuberculosis as the name indicates involves other than the substance of the lung. Tuberculosis is a disease caused by Mycobacterium Tuberculosis, Mycobacterium Bovis.¹ It is a fatal contagious disease that can affect almost all organs of the body. In Europe during 19th century, 25% of deaths were caused by this disease. It is used to be called as the "White death" as opposed to the "Black death" caused by Plague. The death toll began to fall during the early 20th century because of the introduction of effective medicines.

However, more people are affected now than there were in 1950; about 3 million people are expected to die in this era because of this disease especially in poorly developed countries. It is estimated that at any one time, one of the world's population is affected by this disease. EPT is more prevalent among, urbanized, homeless, intravenous drug abusers, population with malnutrition, poor general healthy. People at risk are alcoholics, HIV positive individuals, health care workers, hostellers, prisoners, immigrants from areas of HIV infection.²⁻⁴

Pulmonary T.B. is acquired through droplets where they are exposed to air for hours from an infected person by coughing, sneezing, singing, speaking. However the TB bacteria are killed when exposed to ultraviolet light including sunlight. Infected milk and dairy products are responsible for the gastro-intestinal and reproductive system infections of both men and women.

Disease process starts after the inhalation of tuberculosis bacteria it reaches the lung within 6 weeks. A subtle infection develops which hardly gives any signs and symptoms. This is called a Primary infection or Ghon focus,

after this the infection is disseminated through blood to other organs. People with good immunological status are not usually affected by the disease instead it remains dormant for years without harming the body. It can get reactivated when the person's immune system begins to get deteriorated. Lungs are the favourite habitat for the disease to progress.

Signs and symptoms depend upon the organ which is involved. Chronic cough, persistent cough with sputum production, blood stained in chronic cases, fever, fatigue, weight loss, appetite loss, night sweats. Other non TB bacteria (Atypical Mycobacterium) cause diseases in susceptible patients with history of cystic fibrosis, chronic lung damage, alcoholism and immune-suppression (by disease or drugs). Tuberculosis commonly presents as disease of the lungs. It can spread through blood to brain, meninges, pleura, male and female genitourinary tract, intestine and skin. It can affect other systems as well.

Materials and Methods

Data of the EPT were collected from Indian Journal of Tuberculosis (IJT) since 2010-2016 for a period of 7 years. Details of age, side of lesion, affected sex and immune status were recorded in an Excel sheet. The data were analyzed using Microsoft Excel 2007, SPSS version 23 software.

Results

The result of this study is given in the form of Excel derived bar diagrams. Among the total number of 428 reported cases, males were 186, females 220 and 22 were with unspecified sex. (Fig. 1). Total of 53 were less than 20 years

of age, 297 were between 21-40 years of age, 55 cases were between 41-60 years of age and 23 were above 60 years of age. (Fig. 2). The number of involved nervous system cases were 11, cardiovascular 12, dental 2, endocrine 2, genitourinary 213, intestinal 80, lymphatic 30, musculoskeletal 57, respiratory 9 and skin and soft tissue 12. (Fig. 3). Within 20 years of age 22 were male, 20 were female and 11 belonged to unspecified sex. Between 21 to 40 years of age 123 were male, 171 were female and 3 were with unspecified sex. Between 41 to 60 years of age 31 were male, 23 were female and 1 was unspecified. In the above 60 years of age group 10 were male, 6 were female and 7 were with unspecified sex. (Fig. 4). Among 186 male cases affected by EPT, 3 were with bilateral involvement, 10 with left side involvement and 5 with right side involvement 168 were uniorgan. Among 220 female cases 8 were with bilateral, 15 with left side and 14 with right sided EPT and 183 were uniorgan. Among 22 unspecified cases none are with bilateral involvement, 5 belonged to left side, 6 belonged to right side and 11 were uniorgan. (Fig. 5).

Discussion

Organs with high oxygen tension are more susceptible to TB infection including lung and kidney⁵ Females were more affected by EPT than males including unspecified number 22 cases as per this study (Fig. 1). The predominant age group affected by EPT in this study was 21-40 (Fig. 2). In this study the reported EPT of kidney was 75, and pleura was 9. Moreover the genitourinary system was the most affected one in this study (Fig. 3). EPT of the temporomandibular joint (TMJ) also has been reported.^{6,7} In the present study, no TMJ EPT was reported. TB is more prevalent in infants, children, adolescents, elders and in individuals who have immunosuppressive diseases.^{6,8} In this present study 18.69% of the reported cases were immune compromised. Primary TB is 90% asymptomatic and most commonly affects lungs. Secondary TB occurs when the progressive pulmonary disease spreads to other organ systems through self inoculation via infected sputum, blood or the lymphatic system.⁹ Extra pulmonary lesions (EPT) may be ulcerative, but granulomatous disease is more common.¹⁰ Females were more commonly affected and left side was predominantly affected by EPT (Fig. 4, 5).

Prime organ affected in the urinary system is kidney. In the male genital tract, prime site of infection is epididymis followed by seminal vesicle, prostate, vas-deferens and testis.¹¹ The present study reports 3.50% (15) of prostate involvement. Most frequent complication of prostate TB is infertility due to destruction of glandular tissue and reduction of ejaculatory volume of semen. Prostatic abscess should be considered as a possible aetiology for pyrexia of unknown origin in 5th and 6th decades of life.¹² Tracheal and bronchial compression leads to pneumonia and atelectasis; atelectasis of middle and lower lobes and pulmonary fibrosis respectively.^{13,14}

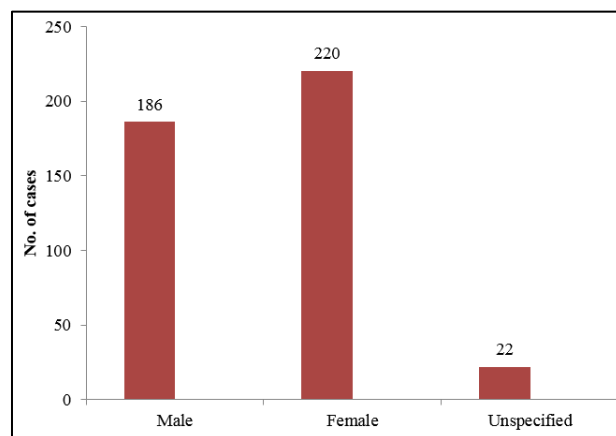


Fig. 1: Bar diagram showing sex wise distribution of EPT

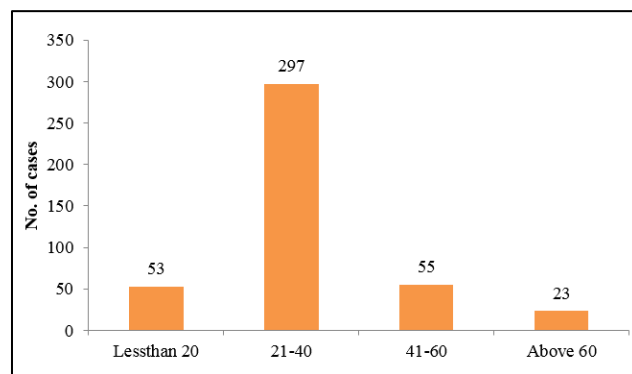


Fig. 2: Bar diagram showing age wise distribution of EPT

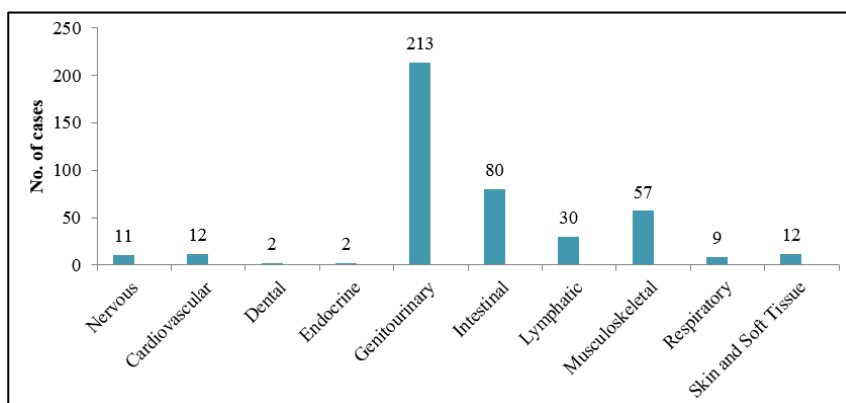


Fig. 3: Bar diagram showing system wise involvement

There are approximately 200 cases of thyroid tuberculosis reported in medical literature.¹⁵ This study reports only one case of thyroid EPT (0.23%). Thyroid dysfunction is rare with tuberculosis of thyroid and very few cases of thyrotoxicosis or hypothyroidism due to destruction of thyroid gland are reported in literature.¹⁶ FNAC is an effective way of pre-operative diagnosis of Thyroid Tuberculosis.¹⁷ In this study FNAC was positive for 7.24% of patients. Apart from Tuberculosis, epitheloid cells in thyroid can be seen in sub-acute granulomatous thyroiditis, autoimmune thyroiditis, sarcoidosis and other infective causes of granulomatous diseases.¹⁸

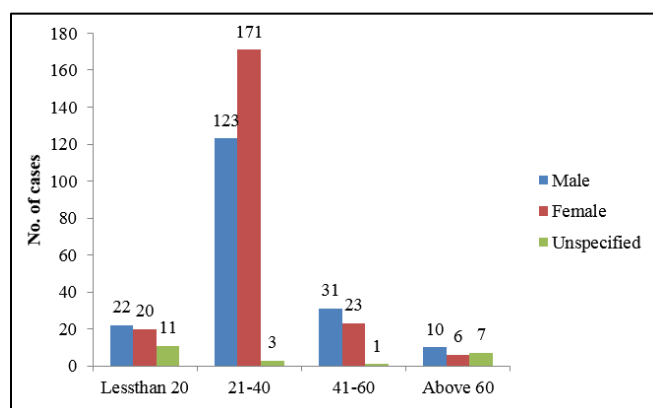


Fig. 4: Bar diagram showing age versus sex distribution

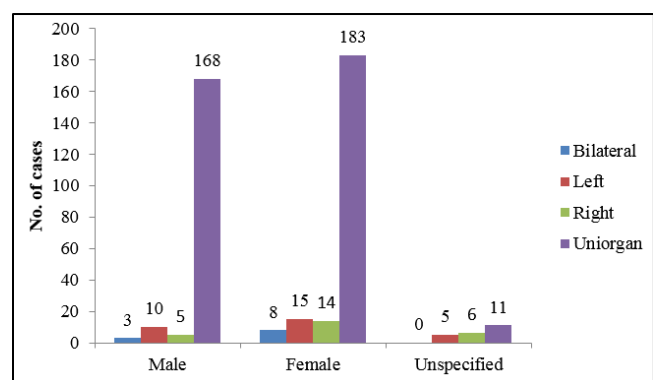


Fig. 5: Bar diagram showing side versus sex distribution

Skeletal involvement of Extra-Pulmonary Tuberculosis is common and knee joint is the third most common joint involved after spine and hip joint.¹⁹ This study reports maximum number of spine involvement of 33 cases. Differential diagnosis of lesions in patella includes tumors (chondroblastoma, osteoblastoma, infected aneurysmal bone cyst to metastatic lesions), tumor like conditions (eg. Brown tumour) and inflammatory lesions (eg. gout, pyogenic and osteomyelitis).²⁰ Imaging studies especially MRI are of great interest for the diagnosis and to assess the extent of TB (Patella). An osteolytic lesion with a sequestrum is usually suggestive of infective pathology and absence of sclerosis and location in the para-articular region suggests Tuberculosis.^{20,21} This study reports a single case of Patella EPT diagnosed by MRI with other investigations (X-ray,

histopathology, Mantoux test, ESR, CRP. Adrenal Tuberculosis is the most common cause of adrenal insufficiency (Addison's disease).²²

Adrenal Tuberculosis manifests as unilateral or bilateral enlargement, central necrosis and calcifications.²³ This study reports a case of Adrenal EPT. EUS-FNAC has proved to be an excellent tool for the cytological diagnosis of pancreatic and peri-pancreatic masses. A definitive cytological diagnosis is possible by EUS-FNAC in 80-95% of cases. This study reports a case of pancreatic EPT. Giovannini et al reported accuracy of 79% of EUS guided biopsy in diagnosis of pancreatic masses,²⁴ whereas Faigel et al reported accuracy of 96%.²⁵ According to WHO, one third of world's population is infected with TB.²⁶ Ross and Somasundaram²⁷ reported forty one out of forty two HIV infected patients developed disseminated Tuberculosis. In the present study 21.50% of the EPT cases underwent HIV test of which 3.30% were HIV positive.²⁸

Conclusion

This study gives an overall view of the organs of our body affected by Extra Pulmonary Tuberculosis. This study provides significant information about the EPT with respect to the number of cases reported in a specified period and their age, gender, most common side of the disease. This study also highlights the predominant system involved by EPT (genitourinary) and also the affected rare organs like tongue, clavicle, conjunctiva and breast. This study also proved that EPT affects any organ which has got its blood supply. The Mission 2025 TB plan (TB free India) by the Ministry of Health and Family Welfare decided to concentrate on exclusively EPT and its prevention. This initiative would take care of the incidence and prevalence of ETB within safe limits.

Conflict of Interest: None.

References

1. Tuberculosis global facts 2011/2012. Geneva, World Health Organization 2012. (<http://www.int/tb/publications/2011/factsheettb2011.pdf>. assessed 06.08.2012)
2. Mistr SK. Tuberculosis available at: <http://www.Emedicine.com/Oph/topic458.htm>. Accessed March 9, 2008.
3. Johnson DW and Herzig KA. Isolated tuberculous pyomyositis in a renal transplant patient. *Nephrol Dial Transplant* 2000;15:743.
4. Ahmed J and Homans J. Tuberculous Pyomyositis of the soleus muscle in a fifteen years old boy. *Pediatr Infect Dis J* 2002;21:1169-71.
5. Puttick MPE, Stein HB, Chan RMT, Elwood RK, How AR, Reid GD. Soft tissue tuberculosis: a series of eleven cases. *J Rheumatol* 1995;22(7):1321-25.
6. LTC Robert G. Hale, CPT David I, Tucker Head and Neck manifestations of Tuberculosis. *Oral Maxillofac Surg Clin N Am* 2008;20:635-42.
7. Soman D Davies SA. Suspected case of Tuberculosis of the Temporomandibular Joint. *Br Dent J* 2003;194(1):23-4.
8. Jerant AF, Bannon M, Rittenhouse S. Identification and management of Tuberculosis. *Am Fam Physician* 2000;61(9):2667-82.

9. Serban Tovar, Mariana Costache, Andrea Sardella, Milan Italy. Primary Oral Tuberculosis: A case series from Bucharest, Romania. *Oral Surg, Oral Med, Oral Pathol, Oral Radiol, Oral Endol* 2008;105:e41-e5.
10. Jigar Dhuwad, Brijesh Patel, Sonal Madan, Mukesh Dhuwad. Orofacial Tubercular Lesions. *Indian J Tuberc* 2014;61:325-30.
11. Gupta Nitin, Mandal AK., Singh SK. Tuberculosis of the prostate and urethra: a review. *Indian J Urol* 2008;24(3):388-91.
12. Vithiya G. et al. Tubercular Prostate abscess in an immunocompetent patient. *Indian J Tuberc* 2007;62:110-3.
13. Faller WH, Kelly TR, Krabil WS, Intrathoracic Goiter. *An Surg* 1965;142:238-47.
14. Rackowrer J, Rrayal P. Bronchiectatic destroyed lobe as a complication of Intrathoracic Goiter. *AMA Arch Intern Med* 1959;103:113-5.
15. Gosh A, Saha B, Battacharya B, Chattopadya S. Primary Tuberculosis of Thyroid gland: A case report. *Am J Otolaryngol* 2007;28:267-70.
16. Choudhary A, Nayak B, Guleria S, Arora R, Gupta R, Sharma MC. Tuberculosis of Thyroid presenting as Multi nodular goiter with Hypothyroidism: A rare presentation. *Indian J Pathol Microbiol* 2010;53:579-81.
17. Mondal A, Patra DK. Efficacy of Fine needle aspiration cytology in the diagnosis of the Tuberculosis of the Thyroid gland, A study of 18 cases. *J Laryngol Otol* 1995;73:187-91.
18. Sirish S Chandanwale, Archana C. Buch, Shruti S, Vima and Punita Sachdeva. Thyroid Tuberculosis: Presenting symptom of Mediastinal Tuberculous Lymphadenitis - An unusual case. *Indian J Tuberc* 2014;61:84-7.
19. Tuli SM. Tuberculosis of Skeleton System. New Delhi. Jaypee Brothers Medical Publishers 1993.
20. Roop Singh, Rakesh Gupta. Tuberculosis of the Patella - A case report. *Indian J Orthop* 2004;38(3):189-90.
21. Shah P, Ramakantan R. Tuberculosis of the Patella. *BP. J Radiol* 1990;63:3634.
22. Patnaik MM, Deshpande AK. Diagnosis – Addison's disease secondary to Tuberculosis of the Adrenal glands. *Clin Med Res* 2008;6(1):21.
23. Engin G, Acunas B, Acunas G, Tunaci M. Imaging of Extra Pulmonary Tuberculosis. *Radiographics* 2000;20:471-88.
24. Giovannini M, Seitz JF, Mongess F, Perrier H, Rabbiah I. Fine needle aspiration cytology guided by Endoscopic Ultrasonography: results in 141 patients. *Endosc* 1995;27:171-7.
25. Faigel Dio, Ginsberg GG, Bentz JS, Gupta PK, Smith DB, Kochman ML. Endoscopic Ultrasound guided real time Fine needle aspiration biopsy of the Pancreas in cancer patients with pancreatic lesions. *J Clin Oncol* 1997;15:1439-43.
26. Pattnaik Lolly, Sarangi Rachita, Mahapatra Satyasundar. Ophthalmic manifestations of Central nervous system Tuberculosis- Two case reports. *Indian J Tuberc* 2011;58:196-98.
27. Rosa Hill et al. Disseminated Tuberculosis in the acquired immunodeficiency era. Department of medicine Pathology, Radiology and Scientific Academic Computing Center State University of New York 1991; 1164-70.
28. Andres SG, Tan-Alora A. A case series of disseminated Tuberculosis. *Phil J Microbiol Infect Dis* 2001;30(1):29-35.

How to cite this article: Mani K. Extra pulmonary tuberculosis: An anatomical perspective. *Indian J Clin Anat Physiol* 2019;6(2):186-9.