

A study on various positions of vermiform appendix in adult human cadavers

K. Lavanya devi¹, V. Lokanayaki^{2,*}

¹Assistant Professor, ²Associate Professor, Institute of Anatomy, Madras Medical College, Chennai, Tamil Nadu, India

*Corresponding Author: V. Lokanayaki

Email: lokanayakiashok@gmail.com

Received: 28th September, 2018

Accepted: 1st November, 2018

Abstract

Introduction: Aim was to know various positions of Vermiform appendix. Acute appendicitis is the most common general surgical emergency. Obstruction of its lumen is the most common cause of acute appendicitis. The severity of appendicitis along with its various positions may lead to different clinical presentations. Knowledge of positions of appendix is essential for surgeons and physicians to arrive an accurate diagnosis and proper management of appendicitis.

Materials and Methods: This study was carried out in fifty adult human cadavers in the Institute of anatomy, Madras Medical College over a period of one year from 2017-2018. The appendix was examined in all the specimens to recognise its various positions.

Result: In the present study, Vermiform appendix was retrocaecal in 31 specimens, then pelvic in 16 specimens. The least common positions were post ileal in 2 specimens and subcaecal in 1 specimen.

Conclusion: The knowledge of various anatomical positions of appendix is must for surgeons to make proper diagnosis and management of various clinical and pathological conditions related to appendix.

Keywords: Vermiform appendix, Appendicectomy.

Introduction

The vermiform appendix (vermis- worm like) is a blind intestinal diverticulum, varying in length commonly about 6-9 cm. It arises from the posteromedial wall of caecum inferior to ileocaecal junction. It belongs to the large intestine but without any sacculations and appendices epiploicae. It lies in the right iliac fossa, in relation to the surface of the abdomen its base lie on the of the way up the oblique line that joins the right anterior superior iliac spine to the umbilicus. It has three parts-base, body and tip. The position of it base is constant in relation to the caecum, the tip is highly mobile and may point in any direction, giving rise to variety of positions. It may be:

1. Posterior to the caecum or proximal part of ascending colon, or both, in a retrocaecal or retrocolic position. It may extended upto right kidney or liver. This position is the commonest.
2. Suspended over the pelvic brim against right sided pelvic wall in a pelvic or descending position. In females it is related to ovary and the right fallopian tube. This position is next in order of frequency.
3. Projecting upward along the side of the caecum in a paracolic position.
4. Below the caecum in a subcaecal position.
5. Anterior / Posterior to the terminal ileum, in a pre ileal / post ileal position
6. The tip is directed towards sacral promontory inguinal ligament, in a promontoric / mid inguinal position.

Its position is generally likened to the hands of the clock. It may present a 11 o' clock position paracolic, 12 o' clock position retrocaecal, 2 o' clock position ileal, 3 o' clock position promontoric, 5 o' clock position pelvic, 6 o' clock position mid inguinal.

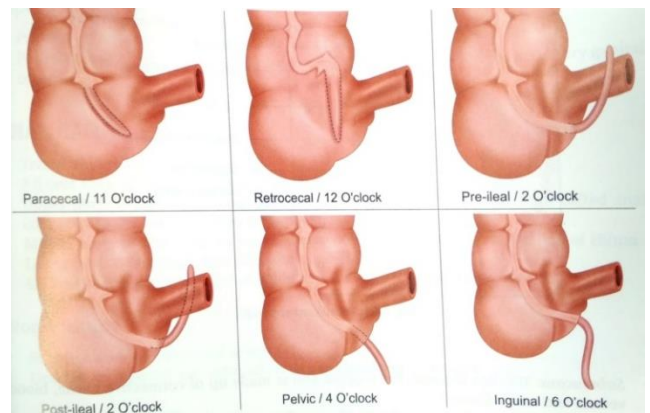


Fig. 1: Various positions of appendix

The three taenia of the caecum merge into complete longitudinal muscle layer of appendix. It has irregular narrow lumen due to numerous lymphoid masses in its submucosa. The lumen of its opens into the caecum by an orifice below and little behind the ileocaecal opening. This lumen is wider in the young age and may be obliterated in elderly. This orifice sometimes guarded by a valve, formed by a mucosal fold. The appendix has its own mesentery, the mesoappendix, a triangular fold of peritoneum from the left layer of mesentery of the terminal ileum. It contains the appendicular vessels and nerves. The appendix is supplied by an end artery, a branch of inferior division of ileocolic artery which is the branch of superior mesenteric artery. The appendicular vein follows the course of the artery, drains into ileocolic vein which is in turn into superior mesenteric vein. The lymphatics from this organ drains into ileocolic group of lymphnodes. Sympathetic nerve supply from superior mesenteric plexus and parasympathetic from both vagi.

The inflamed condition of appendix is known as appendicitis. The predisposing factors responsible for this conditions are: It is a blind tube, possibility stasis of colonic contents. It is supplied by an end artery, in appendicitis it gets thrombosed with subsequent ischaemia leads to gangrene of appendix. Presence of many lymphoid tissues in its wall and due to ineffective valve of its orifice.

Superficial tenderness in appendicitis varies according to its various position:

1. Rigidity on the right iliac fossa is due to peritoneal irritation.
2. In pre ileal position is dangerous, in which appendix lies in the peritoneal cavity as there is chance of rupture leads to general peritonitis.
3. Post ileal type of appendicitis is also dangerous as tenderness and rigidity may be minimum or absent.
4. Pelvic type of appendicitis may rarely associated with haematuria and frequency of micturition.

Appendicitis in different positions mimic different clinical conditions. The knowledge of various positions of appendix will be helpful to identify the site of origin of pain during appendicitis. Since variations involving the appendix are very common, a thorough knowledge of anatomy of the appendix is importance for an accurate diagnosis and management of the condition.

Materials and Methods

The sample size taken was fifty embalmed adult human cadavers, from Institute of Anatomy, Madras Medical College, Chennai. All the specimens were taken at the time of routine dissection.

Abdomen was opened by a cruciate incision. A longitudinal incision was made from the midline, extended from the xyphisternum to the pubic symphysis. A transverse incision was made and extended both sides from the umbilicus. Abdominal wall reflected into four flaps and the peritoneal cavity was opened. The greater omentum was lifted over the costal margin along with transverse colon. Transverse mesocolon was identified which is extended from the colon to the posterior abdominal wall. Loops of jejunum and ileum were turned towards the left side to recognise ascending colon, caecum, appendix and terminal ileum and ileocaecal junction. The colon was identified by haustrations, taeniae and appendices epiploicae. Caecum was found as a blind sac at the proximal end of large intestine. The appendix was identified as narrow diverticulum with the guidance of anterior taenia coli. The position of the appendix was noted in relation to caecum, colon and ileum. The peritoneal fold of appendix was identified and its extent was noted. The Caecum, Appendix, terminal ileum and the part of ascending colon were separated from the adjacent structures by two strings, one was applied on the terminal ileum 5 cm from ileocaecal junction and another string was applied 10 cm from the ileocaecal junction on the ascending colon. The caecum and appendix were removed en mass. All the specimens were photographed and the observations were documented. The specimens were preserved in 10% formalin solution.

Results

The following observations were made. The percentage of various positions of appendix were as follows: Retrocaecal 62%, pelvic 32%, post ileal 4% and subcaecal 2%. When the different positions were compared the most common position was retrocaecal. Not come across other positions like preileal, mid inguinal, promonteric and ectopic variety.

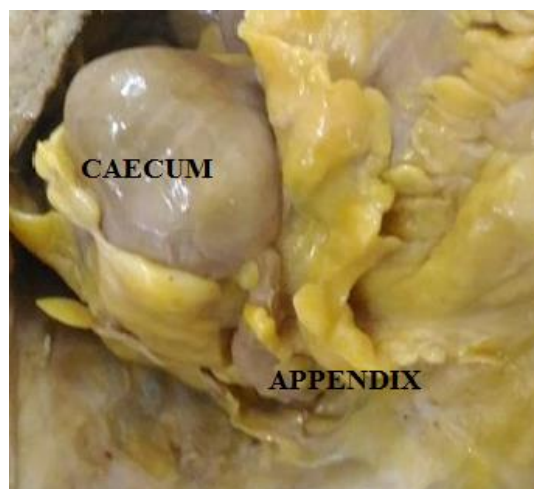


Fig. 2: Retrocaecal position of appendix

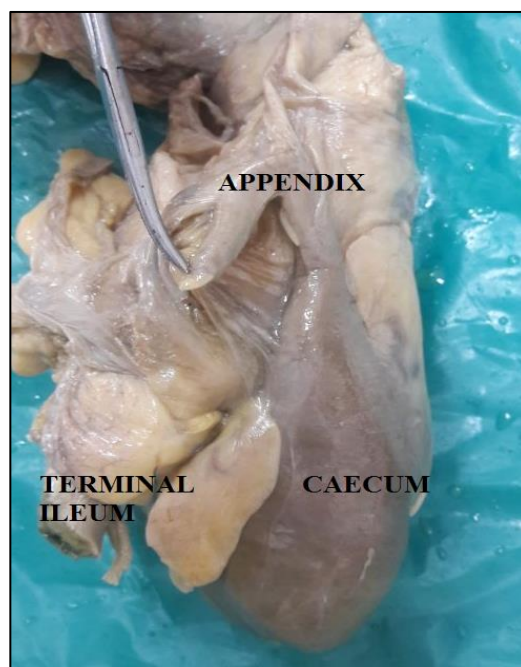


Fig. 3: Retrocaecal position of appendix

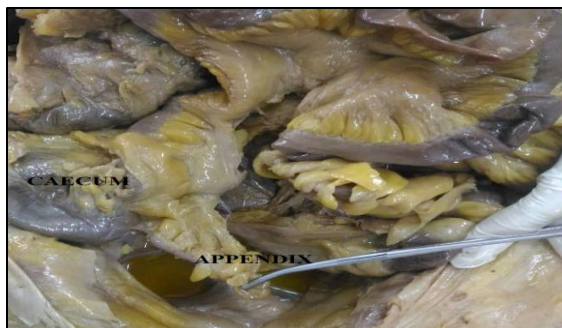

Fig. 4: Pelvic position of appendix

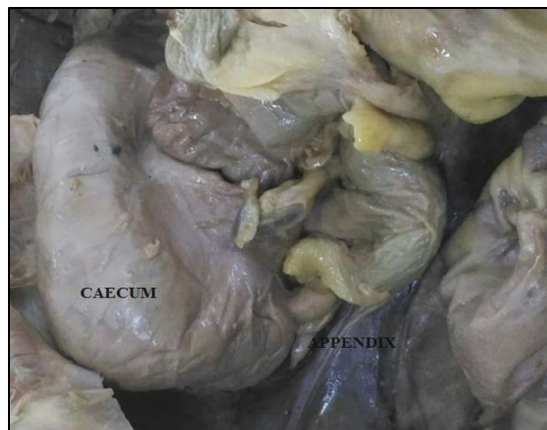


Fig. 6: Subcaecal position of appendix

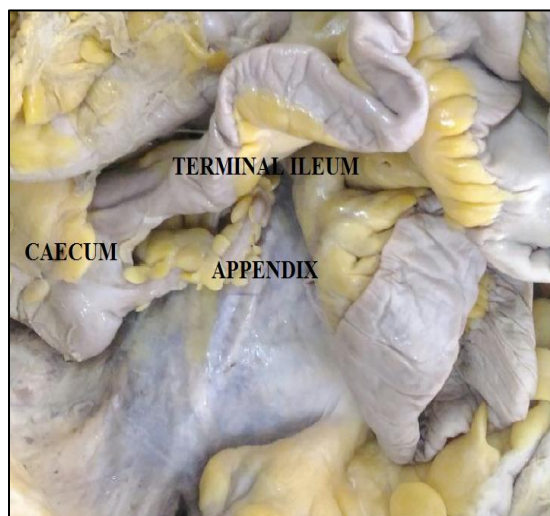


Fig. 5: Post ileal position of appendix

Discussion

The various position of appendix has great surgical and pathological importance. In the present study, the incidence of retrocaecal position of appendix was highest accounting for 62% of cases studied. This findings were similar to the findings of Wakely et al⁹ (1933), Clegg Lamptey et al³ (2006), Chaudhari Manisha et al² (2013), Nilesh Ashok Salwe et al⁷ (2014) and Naveena Swargam et al⁶ (2016).

Katzurskj et al⁵ (1979) in Zambia, Varshney S et al⁸ (1996), Golalipour et al⁴ (2003) in Iran, Ahmed Ghorbani et al¹ (2014) in Iran mentioned pelvic position was the commonest than the retrocaecal. In the present study it was the second common position with the frequency of 32%.

In the present study post ileal position 4% was comparable with Wakely et al⁹ (1933), Clegg Lamptey et al³ (2006), Nilesh Ashok Salwe et al⁷ (2014) and Naveena Swargam et al⁶ (2016).

Subcaecal position (2%) comparable with Wakely et al⁹ (1933). Pre ileal and paracaecal positions were mentioned by some authors, but in present study no such position noted.

It seems the ultimate position of appendix was influenced by many factors including race, dietary life styles and changes in the geographical conditions.

Table 1: Position of appendix in present study

Position of appendix	Retrocaecal	pelvic	Subcaecal	Post ileal
Specimens	31	16	2	1
Percentage	62 %	32 %	4 %	2 %

Table 2: Position of appendix in present study and other similar studies

Name	Specimens	Retrocaecal	Pelvic	Subcaecal	Preileal	Postileal	Subhepatic	Paracaecal	Ectopic
Wakely et al.	10,000	62 %	31 %	2 %	1 %	4 %	Nil	Nil	Nil
Golalipur M J et al.	117	32.4 %	33.3 %	12.8 %	18.8	2.6 %	Nil	Nil	Nil
Varshney S et al.	600	19 %	53 %	7 %	2 %	1 %	Nil	18 %	Nil
Clegg Lamptey et al.	1358	67.3 %	21.6 %	Nil	4.4 %	3.8 %	0.5 %	2.4 %	Nil
Chaudari Manisha et al.	200	55.5 %	23.5 %	6.5 %	Nil	9 %	0.5 %	5 %	Nil
Nilesh Ashok et al.	60	56.6 %	25 %	Nil	15 %	3.4 %	Nil	1.92 %	Nil
Ahmed Ghorbani et al.	200	12.5 %	55.8 %	19 %	1.5 %	Nil	Nil	Nil	4.2 %
Naveena Swargam et al.	50	44 %	24 %	18 %	Nil	4 %	Nil	10 %	Nil
Present study et al.	50	62 %	32 %	2 %	Nil	4 %	Nil	Nil	Nil

Conclusion

Anatomically appendix can vary in its positions. Appendicitis in variable positions may mimic different clinical conditions. Hence knowledge of these positions is important for an accurate diagnosis and management of the condition. In the present study dissection was carried out in fifty adult cadavers and the various positions of appendix was studied in detail. The results obtained were compared with the findings of other similar studies. This study determined the position of appendix, retrocaecal appendix was highest in 62% cases, then pelvic in 32% of cases. Least common positions were post ileal in 4% cases and subcaecal in 2% of cases. Since variations involving the appendix are very common, a thorough knowledge of anatomy of the appendix is of significant importance during surgical and radiological procedures, to avoid complications.

Conflict of Interest: None.

References

- Ahmad Ghorbani, Mehdi Forouzesh, and Amir Mohammad Kazemifar. Variation in Anatomical Position of Vermiform Appendix among Iranian Population". *Int J*, 2014;(10):1155-1159.
- Chaudhari manisha L, Kapadia Divyesh M, Kanani Sanjay D, Patel Jitendra P, Shah Ritesh K, Nirvan Ashok B, "A study of morphology of vermiform appendix in 200 Cases". *Int J Med Res Health Sci* 2013;2(4):780-785.
- Clegg-Lamprey JN, Armah H, Naaeder SB, Adu-Aryee NA. 'Position and susceptibility to inflammation of vermiform appendix in Accra, Ghana'. *East Afr Med J* 2006;83:670-673.
- Golalipour MJ, Aray B, Azarhoosh R, Jahanshahi M. 'Anatomical variations of vermiform appendix in South East Caspian sea (Gorgan Iran)'. *J Anat Soc India* 2003;52(2):141-143.
- Katzarski M, Gopal Rao VK, Brady K. 'Blood Supply and position of the vermiform appendix in Zambians'. *Med J Zambia* 1979;13:32-4
- Naveena swargam, Ashok kumar Malvai, Seema Madan. "A study of variations in caeco appendicular position". *Sch J App Med Sci* 2015;3(3E):1376-1379.
- Nilesh Ashok Salwe, Kulkarni P.G and Sinha R. A study of Morphological variations of vermiform appendix and caecum in cadavers of western Maharashtra region'. *Int J Adv Physiol Allied Sci* 2014;2:31-41.
- Varshney S, Jhonson CD, Rangnekar GV. Retrocaecal appendix appears to be less prone to infection. *Br J Surg* 1996;83:223-224.
- Wakely CPG. The position of the vermiform appendix as described by analysis of 10,000 cases. *J Anat* 1933;67:277.

How to cite this article: K. Lavanya devi, V. Lokanayaki. A study on various positions of vermiform appendix in adult human cadavers. *Indian J Clin Anat Physiol* 2019;6(1):61-64.