

Morphometry of proximal end of femur in population of Telangana state and its clinical application

K. Sreenivasa Reddy^{1,*}, P. David Anand Kumar²

¹Associate Professor, ²Assistant Professor, Dept. of Anatomy, Mediciti Institute of Medical Sciences, Telangana, India

*Corresponding Author: K. Sreenivasa Reddy

Email: sreenivasareddykonadhula@gmail.com

Received: 3rd October, 2018

Accepted: 29th November, 2018

Abstract

Introduction: Fracture proximal end of femur is frequent in our busy life using more vehicles and resulting in more accidents and also because of increased geriatric population where the fracture occurs due to osteoporosis.

Aim: to standardize various parameters of femur.

Materials and Methods: The length of the femur was measured using a wooden board fixed with a tape and a mobile wooden piece. The angle between the axis of neck and the axis of shaft of femur was determined based on procedure given by Singh and Bhasin.⁵ The axis of neck was determined by colored thread used to divide the anterior surface of neck into two equal halves. The width and length of neck of femur are measured using digital vernier calipers.

Results: The length of femur was 43.55cms (SD=2.283), neck shaft angle was 125.35° (SD= 7.883°), length of neck anteriorly 26.51mm (SD=3.369), length of the neck posteriorly 30.846 mm (SD=3.9mm), width of the neck 30.68mm anteroposteriorly (SD=4.359mm), and 29.94 super inferiorly (SD=3.599).

Conclusion: Femoral measurements in this study show that there is a significant difference between our population and other populations studied; there is a need to explore options for customizing implants according to anthropometric measurement corresponding to local population.

Keywords: Femur, Fracture, Dimensions, Implants, Morphometry.

Introduction

Fracture of proximal end of femur involving neck and trochanter are quite common. Internal Fixation with implants is a must for speedy recovery of patients. These implants are designed and produced according to western measurements. Most of our Indian orthopedic surgeons are of opinion that these implants are of large sized for our population and should be modified to suit our population.

The usage of those oversized implants affects the wound healing and end result of the surgery. So we studied the femur, its length, neck-shaft angle, length of the neck anteriorly and posteriorly, and width of neck anteroposteriorly and superio inferiorly in order to standardize the measurements of femur.

Materials and Methods

A total of 366 femora were collected from various colleges of telangana area as follows. 90 femurs from MIMS Ghanpur, 80 femur from Siddipeta, 80 Femure from RIMS Adilabad, and 116 femur from Gandhi medical college and the measurements are taken as follows. The length of the femur was measured using a wooden board fixed with a tape and a mobile wooden piece (Fig. 1). The angle between the axis of neck and the axis of shaft of femur was determined based on procedure given by Singh and Bhasin.¹

The axis of neck was determined by colored thread used to divide the anterior surface of neck into two equal halves. The axis of the femur is marked along a thread suspended from the upper end of greater-trochanter to the lateral condyle of the femur. The angle between axis of neck and axis of femur was measured using a goniometer (Fig. 2).

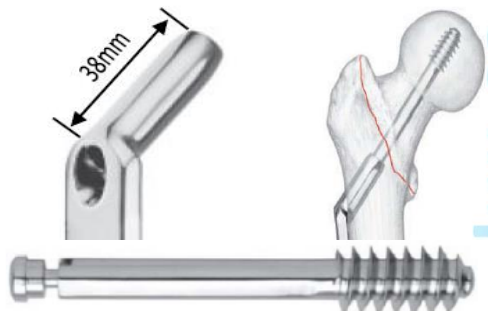
The length of the neck is measured anteriorly between the base of the head and midpoint of intertrochanteric line (Fig. 4). Posteriorly the length is measured between the base of head and midpoint of intertrochanteric crest (Fig. 5). The width of neck is measured supero inferiorly (Fig. 6) and anteroposteriorly. The results are represented in table 2, and these measurements are compared with dimensions of the presently available implants in table 3.



Fig. 1: Measuring length of femur



Fig. 2: Measuring neck-shaft angle of femur



Thread Diameter 12.5mm
 Thread Length 22.0mm
 Shaft Diameter 8.0mm
total length of screw 50 mm

Fig. 3: DHS implant size



Fig. 4: Length of neck anteriorly



Fig. 5: Length of neck posteriorly



Fig. 6: Width of neck supero inferiorly

Results

The statistical analysis was done using SPSS 15.0. The descriptive statistics (frequency, range, mean and standard error) for the variables are presented in Table 2.

Table 1: Dimensions of orthopedic implants commonly used for treatment of proximal fractures of femur

Implant: DHS/DCS	Dimensions
Thread diameter	12.5mm
Thread length	22mm
Shaft diameter	08mm
Barrel angle	125 -130°
Barrel diameter	12.6mm
Barrel thickness	15.8mm
Barrel width	19mm
AO SCREWS	
Thread diameter	6.5mm
Shaft diameter	4.5mm
BLADE PLATE	
Blade length	35mm
Blade thickness	02mm

Table 2: Descriptive statistics

Variable	Number of femurs	Mean ± SD
Length of femur (cms)	366	43.55 ± 2.283
Neck-shaft angle (degrees)	366	125.35 ± 7.883
Length of neck (mm)		
Anteriorly	366	26.51 ± 3.369
Posteriorly	366	30.846 ± 3.900
Width of neck (mm) Anteroposteriorly		
Supero inferiorly	366	29.94 ± 3.599

Table 3: Comparison between dimensions of Indian femurs and foreign implants

Variable	Present Study	Dimension of Implant (11)
Neck-shaft angle	125.35°	125° - 155°
Neck length		
Anteriorly	26.5mms	22mms
Posteriorly	30.8mms	22mms

	Present Study	Width of compact bone (18)	Dimensions of Implant	Cancellous bone
Neck width antero-posteriorly	30.68 mm	4mm	19 mm barrel diameter	7.68 mm/2=3.84
Neck width supero-inferiorly	29.94 mm	4.5mm	15.8 mm barrel thickness	9.64mm/2=4.82

Discussion

The femur’s neck is a very important structure for erect position of human body. According to large number of Anatomists the average neck-shaft angle in human beings is 125° (range 110° to 144°) and in fetuses is 140°. The angle between the axis of the neck and axis of the shaft of femur was studied by many workers previously namely Parson P.G (1914)¹ Hashimoto M (1938),² Humphry WH (1958),³ Kate BR (1967),⁴ Singh P (1968).⁵

The average angle in the present study (n= 366) is found to be 125.35° (range 105°-142°), standard error being 7.88°. Very few Indian studies are available with respect to the dimensions of the proximal femur. Kate measured neck shaft angle of 1000 femora and found the average as 128.4° degrees in the year 1968.⁴ Siwach measured neck shaft angle in 75 pairs of femora and found average to be 123.5°.⁶

In 2008 Saikia KC worked on the North Eastern population and found the average neck shaft angle to be 139.5°.⁷ In 1993 Isaac B found that the average neck shaft angle was 127.5° (8). Toogood et al, in the year 2009 studied the proximal femoral anatomy and concluded the average neck shaft angle as 129.23°.⁹

Minakshi et al¹² in their study of morphometry of proximal femur in Indian population (the bones collected in north India got femur length as 42.82± 2.87 cm, neck length as 44.75 mm ± 8.097, width of neck as 24.01 ± 3.05 mm and neck shaft angle as 128.9 ± 5.52°, when compared to our study the length of femur is very near to our values, the neck shaft angle is a little higher and the length and width of neck of femur are very high compared to our study. This signifies that the values are differing for people of various ethnic groups.

Aparnagullapalli¹³ et al in their study of femoral neck shaft angle followed Billing¹⁴ and Norman¹⁵ method to measure the neck shaft angle in which the axis of the neck is represented by a line drawn from the centre of the femoral head to the center of the femoral neck at the narrowest part of the neck and a line drawn from the middle of the femoral condyles to the middle of the greater trochanter is taken as axis of shaft of femur. But in Bhasim et al⁵ method which we followed the axis of neck was determined by colored thread used to divide the anterior surface of neck into two equal halves. The axis of the femur is marked along a thread suspended from the upper end of greater-trochanter to the lateral condyle of the femur. They observed the neck shaft

angle as 121°, this may be because of the procedure used to determine the neck shaft angle by them.

Our results are almost similar to that of Siwach and Isaac but differs a little with the studies of Toogood et al, and largely from that of Saikia et al.

The mean length of neck in the present study is 26.5 mm anteriorly and 30.8 mm posteriorly, average 28.7mm and the standard error is 0.0133. According to Siwach (2003) maximum and minimum effective neck length are 37.2 mms and 22.6 mms and mean is 29.9 mms. In our study the average neck width is 30.31 mms (SE 0.073). So we get the higher value than Siwach who got it as 24.9 mm (width).

Dr. Ravichandran¹¹ and others in their study at VMKV medical college Salem collected about 560 unpaired femora from various colleges of Madras state and studied various dimensions their results are as follows average neck shaft angle is 126.55°, neck length as 31.18 mm, width 30.99 mm. These results are almost consistent with our results. Ravichandran et al in their study proved that the implants available at present are not suitable for our Indian Patients as they are prepared according to the sizes of western population.

Ravi G.O¹⁶ et al in their study on south Indian femora got the average length of femur as 44.71, length of neck of femur as 36.3 mm, and neck shaft angle as 136.8° and these measurements are consistent with our results..

Amith R, Beena N¹⁰ and others in their study of south Indian femora by computer assisted image analysis method got the neck shaft angle as 121.2°. This is far less than most of the studies conducted on south Indian bones.

A comparison between the dimensions found in our study and dimensions of the available orthopaedic implants shows that these implants are oversized for Indian skeleton and sufficient bone stock is not available for effective fixation. Use of such implants not only effect the functional end result but also negates the very purpose of internal fixation and early rehabilitation. The D H S dynamic hip screw is the implant of choice for stable trochantric fracture and dynamic condyle screw is for unstable trochantric fracture.

High angle implants (as DHS barrel angle 135°) causes malunion in valgus and that with lower angle (as DHS barrel angle 95°) causes malunion in varus thus altering biomechanics at both hip and knee joints leading greater risk of secondary arthritis to the patient.

Insertion of the screws with large thread diameter needs

removal of cancellous bone leading to loss of cancellous bone needed for repair of fracture.

As an example DHS/DCS has a thread diameter of 12.5 mm and barrel diameter of 12.6 mm, insertion of this screws needs reaming upto 11.5mm and tapping upto 13.5 mm, thus removing large cancellous bone from the neck of femur. There by delaying the healing process. It is clear that the proximal femoral geometry varies among different ethnic groups. Therefore usage of implants designed exclusively for Western bones will not be suitable for other ethnic groups.

The dimensions found in our study are lesser than the measurements of the orthopedic implants. These implants are bigger in size for the Indian femora and therefore bone stock is not available for an effective fixation. These bigger implants result in failure of the surgery. The Dynamic Hip Screw (DHS) is used for stable trochanteric fractures & Dynamic Condylar Screw (DCS) / Condylar Blade is used for unstable trochanteric fractures (14, 15) higher angle implants (eg. DHS barrel angle: 135°) causes malunion in valgus & that with lower angle (DCS & Condylar Blade plate 95°degrees) causes malunion in varus. The thread diameter of the DHS / DCS is 12.5 mm and barrel diameter is 12.6 mm (Table 1).

In 2003 Siwach has measured the neck width as 2.49 cm and neck length as 3.18cm. The width of the neck in our study is only 3.097 cm. Therefore these implants (Fig. 3) are bigger in size and cause arrest of circulation resulting in non-union and avascular necrosis.

In 2009 Mishra AK et al¹⁷ in his study concluded that these western implants are bigger and not suitable for Indians. He found a need to design these implants suitable for Indian bones stresses that the fracture implant designs should be specific for Indians.

Conclusion

The present study shows the neck shaft angle and the length and width of the neck of the femur in our people is far less than the Western people. So the implants prepared according to western people dimensions are far bigger than our femora. So there is a need to prepare implants according to our study to be useful for our people.

Sources of Funding: Nil.

Conflicts of Interest: None.

References

1. Parson P.G The characteristics of the English thigh bone, *J Anat Physio* 1914;48:238-267.
2. Hasimoto M, ethnologic studies of Chinese, *J Oriental Med* 1938;29:32-34.
3. Hmphrey W.H. The angle of neck with shaft of femur at different periods of life and under different circumstances. *J Anat Physio* 1958;23:273
4. Kate B.R. The angle of the femoral neck in Indians Eastern *Anthropol* 1967;20:54-60.
5. Singh P.I, Bhasin M.L. Anthropometry 1st Edn; Delhi, Educational Publishers and Booksellers ; 1968, pp 142
6. Siwach RC, Dahiya S. Anthropometric study of proximal femur geometry and its clinical application. *Indian J Orthop*

- 2003;37(4):247-251.
7. Saikia KC, Bhuyan SK, Rongphar R. Anthropometric study of the hip joint in Northeastern region population with computed tomography scan. *Indian J Orthop* 2008;42:2606.
8. Isaac B. Neck Shaft Angle of Femur (thesis). Vellore: Tamil Nadu Dr. MGR Medical University; 1993.
9. Toogood PA, Skalak A, Cooperman DR. Proximal Femoral Anatomy in the Normal Human population. *Clin Orthop Relat Res* 2009;467(4):876-885.
10. Amith R, Beena N, Vinay K.V Morphometry of femoral neck shaft angle in dry femora of south India by computer assisted image analysis method. *Int J Anat Res* 2017;5(2.1):3753-58.
11. D. Ravichandran, N. Muthukumarvel, Proximal femoral geometry in Indians and its clinical application. *J Anat Soc India* 2011;60(1):6-12.
12. Minaks HI Verma. Morphometry of Proximal femur in Indian population. *J Clin Diagn Res* 2017;11(2):Aco1-Aco4.
13. Aparnagullapali, Anilkumarinuganti, Morphometric study of Femoral neck shaft angle and its clinical significance. *Int J Anat Res* 2017;5(3-2):4261-4264.
14. Biling L. Roentgen examination of the proximal femur end in children and adolescents, *Acta Radial* 1954 suppl 110
15. Nomano. Matning a v collumante versions vinkeln, Enprincipiell diskusjon, *Nord Med* 1969;75:318.
16. Ravi G O, Sheik Hussain Saheb, Abraham Ratna Joseph N A morphometric study of femur and its clinical importance. *Int J Intg Med Sci* 2016;3(7):341-44.
17. Mishra AK, Chalse P, Singh R.P, Shah R.K. The proximal femur a second look at rational implant design. *Nepal Med Coll J* 2009;11(4):278-280.
18. Encyclopedia Britannica.

How to cite this article: Reddy KS, Kumar PDA. Morphometry of proximal end of femur in population of Telangana state and its clinical application. *Indian J Clin Anat Physiol* 2019;6(1):57-60.