

## Size of coronoid process and ramus as novel parameters in determination of mandibular sex

Mouna Subbaramaiah<sup>1,\*</sup>, S.R. Jagannatha<sup>2</sup>

<sup>1</sup>Assistant Professor, Dept. of Anatomy, Kempegowda Institute of Medical Sciences, Bangalore, Karnataka,

<sup>2</sup>Associate Professor, Dept. of Forensic Medicine, Kempegowda Institute of Medical Sciences, Bangalore, Karnataka, India

**\*Corresponding Author:**

Email: mounagowda123@rediffmail.com

Received: 23<sup>rd</sup> January, 2018

Accepted: 13<sup>th</sup> April, 2018

### Abstract

**Introduction:** The mandibular coronoid process is derived from a Greek word 'korone' and described as a triangular piece of flattened bone which projects upwards from the anterior part of the mandibular ramus. However it exists in various shapes and sizes. Recently it is being widely harvested as a graft material by surgeons in many reconstructive surgeries due to easy accessibility and membranous nature. It is also used as a useful anthropological marker in determination of species, sex and age. The present study was undertaken to determine the size of the coronoid process existing in south Indian adult population on both sides and to assess the feasibility of using this knowledge in identification of sexing the afore said population.

**Materials and Methods:** The study includes 30 male and 30 female mandibles which were collected from various medical colleges. The size of the process was assessed by measuring the height and widths of the coronoid process at its base. Total length of the ramus at the coronoid process was also measured. Results were tabulated and statistically analysed using student paired T test with  $p \leq 0.05$ .

**Results:** The height of coronoid process and the length of the ramus at the coronoid process have significant differences on right and left sides in male and female mandibles and can thus be used as a novel parameter in determination of sex.

**Keywords:** Coronoid, Mandible, Size, Sex determination, Height, Width.

### Introduction

The mandible is the second bone to ossify after clavicle. It is robust and sturdy, being the only movable bone present in the face. It has a slow resorption rate and as such it is a frequent entity found in long standing human skeletal remains and forms an important marker in identification. It has a U shaped arched body with two ascending rami. Each ramus ends in two processes namely the condylar posterior and coronoid processes anteriorly. The shape of mandibular ramus is very specific for each species amongst primates. In carnivores the process is extensively massive with its upper part being slightly bent backwards. In ungulates the process is far smaller in size. The ruminants tend to have long and more strongly posteriorly curved coronoid while non ruminants have a short and not so curved form. The ramus shape in humans very closely resembles that of a chimpanzee. It is relatively slender in appearance (particularly at its tip). It is relatively shorter in height and is separated from the condylar process behind by a very deep massetric notch. Several other primates' including gorillas tend to have a relatively wide coronoid process separated from the condylar process by a very shallow mandibular notch.<sup>2</sup>

The coronoid process (processus coronoideus) derived from a Greek word 'korone' (meaning crow's beak/crown) is a flattened piece of bone which projects upwards from the anterior end of the mandibular ramus. It receives the insertion of the temporalis on its medial surface, anterior margin, apex and masseter on its lateral surface. These are important muscles of

mastication and are functionally and morphologically dependant on each other<sup>1</sup>. The development of the coronoid process much depends on the activity of these two muscles<sup>1</sup>. Several authors like Isaac, Narayana and M Subbaramaiah have recently described various forms of coronoid process that are evident in human mandibles. The different shapes can be classified as triangular, rounded, hook shaped, rectangular and flattened.<sup>3-5</sup>

The various shapes or forms of coronoid process and mandibular ramus help in determination age and sex to a large extent.<sup>4-7</sup> The form of the coronoid process is highly variable in different ages. It is bulky and higher than the level of condyle at birth. Gradually with the growth of the neck of the mandible, condyles almost reach the same height as coronoid process at adulthood. With further progress in age and associated resorption of the alveolar processes the coronoid process once again becomes taller.<sup>1</sup>

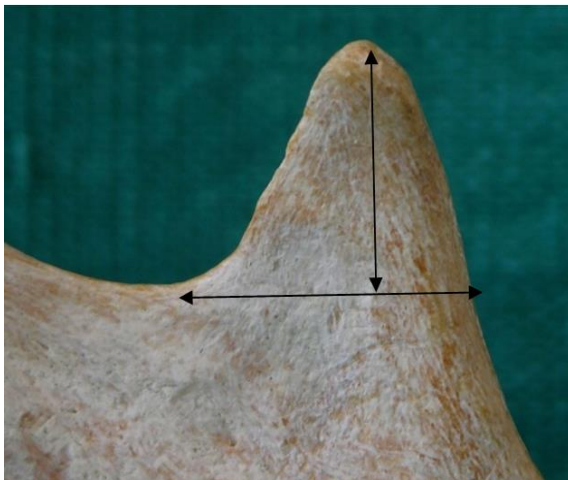
The clinical applications of coronoid morphology in the field of craniofacial reconstructive surgery have already been well documented in literature. The coronoid process of the mandible is gaining vital importance and being harvested as graft material in various aspects of reconstructive craniomaxillofacial surgeries like alveolar defects repair, orbital floor reconstruction, maxillary/paranasal augmentation and temporomandibular joint ankylosis due to its close proximity, slow resorption rate and easy accessibility.<sup>8-10</sup> It is also used as a useful anthropological marker in determination of species, sex and age to a certain

extent.<sup>2</sup> The present study was under taken to determine the size of the coronoid process as well as ramus existing in south Indian adult population on both sides and to assess the feasibility of using this knowledge of coronoid morphometry in identification of sex.

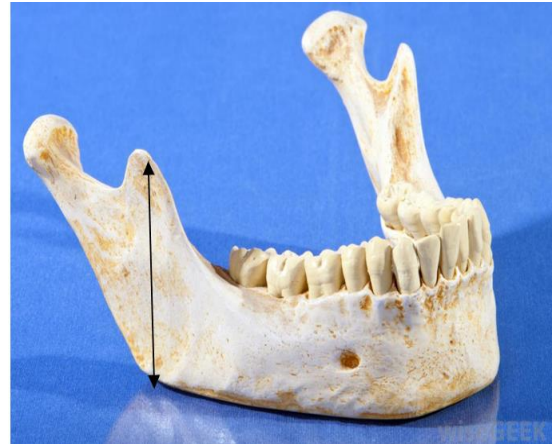### Materials and Methods

The mandibles were collected from departments of anatomy in and around Bangalore. 30 male and 30 female mandibles were retrieved during routine cadaver dissection for undergraduate M.B.B.S students, and studied regarding the size of the coronoid process on right and left sides. Mandibles of adult age group were included in the study. The mandibles in which the coronoid process was damaged or pathologically deformed were excluded from the study.

The mandibles were placed on a horizontal plane and the basal point of mandibular notch was marked as a reference point. The maximum width of coronoid process was measured from the reference point (base). The height of coronoid process was measured by dropping a tangent from the tip of coronoid process to the base. Total distance between tip of coronoid process and angle of the ramus was also measured. Measurement was taken using the vernier callipers (Fig. 1 and 2). Results were tabulated. The data was statistically analysed for the purpose of comparison and correlation by calculating the mean, range and standard deviation of width, height of coronoid process and size of ramus at coronoid process. Student's paired t-test with two-tailed distribution was applied for comparison of the different parameters on the right and left sides in male and female mandibles. P-value  $\leq 0.05$  was considered as statistically significant.



**Fig. 1: Photograph showing measurement of height (a) and width (b) of coronoid process**



**Fig. 2: Photograph showing measurement of ramus-distance between coronoid process and angle (c)**

### Results

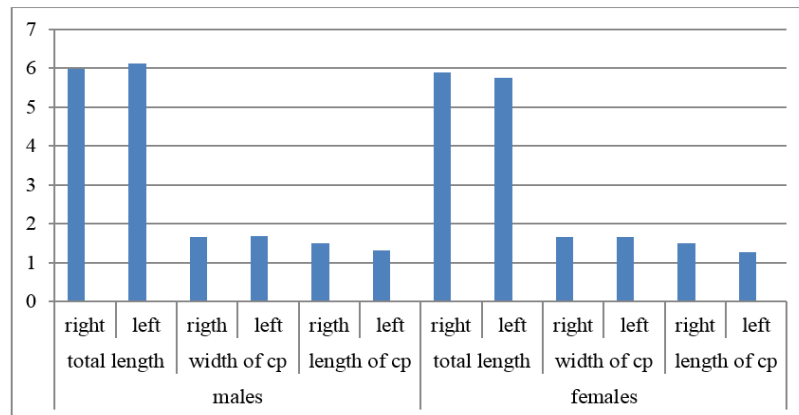
From the present study it was noted that the length of the ramus at the coronoid process and the height of coronoid process from its base have significant differences on right and left sides in males and female mandibles. The results of the present study are tabulated (ref; table and graph).

1. Coronoid height-Average height of coronoid process in south Indian population was  $1.39 \pm 0.34$ cm (0.6-2.2cm). Average height of coronoid process was greater on right side by 0.21cm. Difference is statistically significant (p-value 0.046). No significant variation in height of coronoid process was noted between male and female mandibles. However when side was taken into consideration female mandibles showed higher variation between the two sides.
2. Coronoid width-Average width of coronoid process in south Indian population was  $1.67 \pm 0.23$ cm (1.1-2.2cm). No significant variation in width of coronoid process was noted between male and female mandibles on right and left sides. However when sex was taken into consideration male mandibles showed slight higher variation between right and left sides.
3. Distance between angle tip of coronoid process-Average size of ramus at coronoid process in south Indian population was  $5.89 \pm 0.51$ cm (4.4-7.1cm). Average values were greater on left side. Significant variation was seen in measurements between male and female mandibles (p-value 0.038). When side was taken into consideration male mandibles showed greater length on left side.

Thus from the present study it was noted that the length of the ramus at the coronoid process and the height of coronoid process have significant differences with respect to laterality and sex of the mandible.

**Table 1: Showing the measurements of coronoid process (CP)**

	Right (n=60)			Left (n=60)		
	RAMUS AT CP in cm	CP Width in cm	CP Height in cm	RAMUS AT CP in cm	CP Width in cm	CP Height in cm
Male(n=30)	5.98±0.51	1.66±0.20	1.49±0.37	6.11±0.53	1.70±0.22	1.31±0.34
Female(n=30)	5.70±0.46	1.67±0.26	1.51±0.29	5.73±0.53	1.66±0.22	1.26±0.34
Total(n=60)	5.84±0.52	1.67±0.23	1.50±0.33	5.93±0.53	1.68±0.22	1.29±0.34

**Graph 1: Showing difference in measurements between male and female mandibles**

X axis-showing different variables; Y axis-showing values in cm

## Discussion

Determination of sex by morphological assessment of dry bones has remained one of the time tested approaches in forensic anthropology and medico-legal examinations. The method may vary and depend on the available bones and their conditions. When entire adult skeleton is available for analysis, sex can be determined up to 100% accuracy. However when only fragmented bones are found, sex determination is tried using various parameters from the available material. Though not accurate it becomes essential for identification especially in cases of mass fatalities<sup>11</sup>.

The coronoid process (processus coronoideus) derived from a Greek word 'korone' (meaning crow's beak/crown) is a triangular piece of flattened bone which projects upwards from the anterior part of the mandibular ramus<sup>1</sup>. The mandible develops from first brachial arch cartilage (Meckel's cartilage) at sixth week of intrauterine life ossification takes place in membrane covering the ventral end of the cartilage and each half is formed from separate centres. The initial development of coronoid process begins on the 55<sup>th</sup> day of intrauterine life (24mm stage) in membranous form. At about the 70<sup>th</sup> day of intrauterine life (43mm stage) two bony processes begin to appear namely the condylar and the coronoid processes. At about the 13<sup>th</sup> week of intrauterine life, an extra strip of cartilage appears along the anterior border of preformed coronoid process which is later displaced by the membrane bone. This secondary cartilage usually disappears before birth however sometimes it can persist as subcoronoid sutures. Further development of

coronoid process is associated with much variation in morphology and morphometry of the coronoid process. This can be attributed to various factors like-

1. The social and cultural background of a person largely determines the chewing and dietary habits. Sometimes occupation of the individuals has a direct or indirect affect on the size of the temporalis muscle which in turn alters the size and shape of the coronoid process eg. People who use their mouth extensively like the basket weavers tend to have bigger coronoid process.
2. The nature of diet as we know has a vital role in affecting the muscular pull on the bony process thereby altering the final shape and size of the process. Harder the diet the process tends to be bigger and vice versa.<sup>12,13</sup>
3. Masseter-Temporalis (M-T) component is very active in vertical thrust during chewing. The functional factors necessitate the right coronoid process to be longer than the left as most people tend to chew on the right side. Lateralization of the masseter - temporalis component effect largely depends upon the individual masticatory behaviour. This is also reflected in the shape of the coronoid process. More the stress the coronoid is remodelled as triangular with pointed tip, lesser the stress the process appears rounded and further less stress results in hooked coronoid process.
4. Male hormonal impact on muscle growth, bone remodelling and psychology probably lead to enhanced functional stress on the mandible during mastication as compared to that of females.<sup>14</sup>

5. Genetic impact also plays a vital role in remodelling of the coronoid process.<sup>13</sup> Hook shaped coronoid process goes in favour of female mandibles.<sup>5</sup> Also samples taken from different population may lead to variation in size and form of the process.

The final form/shape and size of coronoid process as well as ramus depends on all the above factors. According to S. Nayak et al. The coronoid process was found to be approximately 1.5 mm longer on the right side than on the left side. Triangular coronoid process was found to be the longest followed by round and then hook shaped.<sup>15</sup> A study conducted by Kambylafka et al. concluded that the evaluation of total ramal height is reliable, and an asymmetry of more than 6% is an indication of a true asymmetry using panoramic radiograph.<sup>7</sup> A study conducted by Saini, et al. showed that coronoid height possessed the best potential for sex determination on Indian people with the accuracy of 74.1%, and the combination of it with minimum ramus breadth, maximum ramus breadth, and/or mandibular ramus length will show significant sexual dimorphism with an overall accuracy of 80.2%.<sup>6</sup> A study by Samatha K. et al. mandibular ramus height found to be the best parameter with statistically significant with  $P = 0.005$ .<sup>16</sup>

The findings of the present study are consistent with most other previous studies done,<sup>7,15-18</sup> the size of the right coronoid process being greater than the left. This difference was even more marked when sex was taken into consideration. However the actual height, width of the coronoid process and size of ramus at coronoid showed variation which could be due to any of the above factors or due to sample variation.

### Conclusion

From the present study it was noted that the size of the ramus at the coronoid process and the height of coronoid process from its base have significant differences on right and left sides in males and female mandibles. The coronoid process is a membranous bone showing less resorption and remains unaltered for a long time and can serve as a very useful anthropological marker. The data of size of the mandibular coronoid process as seen from the study can be utilised in future for comparison of anthropometric results from different population or species. The data will also be of help to the dental and craniomaxillo-facial surgeons in planning coronoid graft implants in facial reconstructive surgeries.

**Conflict of Interest:** Nil

### References

1. Susan Stranding ed. Gray's Anatomy: The Anatomical basis of clinical practice 40th Ed. Churchill Livingstone, Elsevier; 2008, 530-533.
2. Rak Y., Ginsbing A., Geffen E. Gorilla like anatomy of Australopithecus afarensis mandible Au. Afarensis link to

- robust australopiths. *PNAS* April 17, 2007. 104 (16) 6568-6572; <https://doi.org/10.1073/pnas.0606454104>
3. Isaac B. and Holla S. J. Variations in the shape of coronoid process in the adult human mandible. *Journal of Anatomical Society of India*. 2001;50(2):137-139.
4. Prashanthi N., Narayana K., and Nayak S. R.; Morphology of lingula, coronoid process and the mandibular notch in Indian dry mandibles. *Folia Anatomica, Belgrade*. 2004;31(1):13-16.
5. Subbaramaiah M, Bajpe R, Jagannatha SR. Jayanthi KS. A Study of Various Forms of Mandibular Coronoid Process in Determination of Sex. *Indian Journal of Clinical Anatomy and Physiology*. 2015;2(4):199-203.
6. Saini V, Srivastava R, Rai RK, Shamal SN, Singh TB, Tripathi SK. Mandibular ramus: An indicator for sex in fragmentary mandible. *J Forensic Sci*. 2011;56 Suppl.1:S13-6.
7. Kambylafka P, Murdock E, Gilda E, Tallents RH, Kyrkanides S. Validity of panoramic radiographs for measuring mandibular asymmetry. *Angle Orthod*. 2006;76(3):388-93.
8. Mintz S. M., Ettinger A, Schmakel T and Gleason M. J.; Contralateral coronoid process bone grafts for orbital floor reconstruction- an anatomic study and clinical study. *Journal of Oral and Maxillofacial Surgery*, 1998;56(10):1140-1144.
9. Choung PH., Kim SG.; The coronoid process for paranasal augmentation in the correction of midfacial concavity *Oral Surg Oral Med Oral Pathol Oral Radiol Endod*. 2001Jan;91(1):28-33.
10. Egitto Vasconcel B.C., Gabriel Granja Porto, Ricardo Viana, Bessa Nogvelira; Temporo mandibular joint ankylosis. *Revista Brasileira Otorrinolaringologia*. Feb. 2008;74(1):34-38.
11. Raj JD, Ramesh S. Sexual dimorphism in mandibular ramus of South Indian population. *Antrocom Online J Anthropol*. 2013;9:253-8.
12. Avis. V; The relation of the temporal muscle to the form of coronoid process. *Am J of Phys Anthropol*. 1959;17:99-104.
13. Meopi N Syropoulos; The morphogenetic relationship of the temporalis muscle to the coronoid process in human embryos and fetuses. *Am J Anat*. April 1977;150(3):395-409.
14. Coronoid-condylar index in assessing of mandibular coronoid hyperplasia: *Advances in Medical Sciences*; Vol. 58(2);2013:429-433. DOI: 10.2478/ams-2013-0005
15. S. Nayak, S. Patra, G. Singh, C. M. Study of the Size of the Coronoid Process of Mandible. *IOSR Journal of Dental and Medical Sciences (IOSR-JDMS)*. 2015;14(6) 66-69.
16. Samatha K, Byahatti SM, Ammanagi RA, Tantradi P, Sarang CK, Shivpuje P. Sex determination by mandibular ramus: A digital orthopantomographic study. *Journal of Forensic Dental Sciences*. 2016;8(2):95-98.
17. Kasat PA, Bhuiyan PS. A study on coronoid process of the dry adult human mandibles. *Journal of the Anatomical Society of India*. 2016 Jun 30;65(1):9-14.
18. Bakirci S, Ari I, Kafa IM. Morphometric characteristics and typology of the coronoid process of the mandible. *Acta Med. Mediter*. 2013;29:683-686.

**How to cite this article:** Subbaramaiah M, Jagannatha SR. Size of coronoid process and ramus as novel parameters in determination of mandibular sex. *Ind J Clin Anat Physiol*. 2018;5(3):402-405.