

Morphological and morphometric study of insular cortex in human cadaveric brains

Jaya Kadam¹, Vandana Sharma^{2,*}, Sonia Baweja³, Deepak Sharma⁴

¹PG Student, ²Associate Professor & HOD, ³Associate Professor, ⁴Demonstrator, Dept. of Anatomy, Gandhi Medical College, Bhopal, Madhya Pradesh, India

*Corresponding Author:

Email: vsanatomy@gmail.com

Received: 10th February, 2018

Accepted: 12th February, 2018

Abstract

Introduction and Aim: The insular cortex is hidden 5th lobe of brain with variable gross anatomical patterns. Insula is situated in operculoinsular compartment of sylvian cistern.

Materials and Methods: 58 human formalin fixed cerebral hemispheres were studied for the gyri and sulci variations of insular cortex and their lengths were recorded using digital vernier caliper. This study was done in department of Anatomy, Gandhi medical college Bhopal.

Result: The morphological normal and variable pattern, discontinuous sulci and joined gyri were observed. Out of the (85/406) 21% variable pattern we observed (44/406) 10.3% Bifid, (31/406) 7.63%, Hypoplastic Gyri and (10/406) 2.46% Trifid. The Bifid pattern was most commonly seen in Anterior Short Gyrus 18/44 (41%). The Hypoplastic pattern was most commonly seen in Middle Short Gyri 18/31 (58%). There was presence of Transverse Gyri in 13/58 (22.41%) and Accessory gyri in 39/58 (65.51%) cerebral hemispheres. Transverse gyrus & Accessory gyrus both were absent in 19/58 (32.76%) cerebral hemispheres in insular cortex. Total number of gyri in every insula and Mean lengths of gyri were Anterior short=24.54mm, Middle short=25.04, Posterior short=34.08mm, Anterior long=36.87mm, Posterior long=37.1mm measured. The Mean lengths of all insular sulci were Central Insular=35.3mm, Superior Periinsular=52.48mm, Anterior Periinsular=24.5mm, Inferior Periinsular=26.4mm, Posterior Periinsular=12.81mm measured.

Conclusion: Variation in morphological pattern of gyri are Bifid, Trifid and Hypoplastic. The Transverse and Accessory gyri were present in anterior lobule, but not observed in each insula. There was variation in number of gyri because of presence of transverse and accessory gyrus. Total number of gyri are more in anterior lobule so it is larger than Posterior lobule. The gyri of anterior lobule are shorter than gyri of Posterior lobule. Such morphological features and variations are important for surgeries.

Keywords: Morphology, Morphometric, Insular cortex gyri and sulci.

Introduction

Insular cortex is called hidden 5th lobe of brain with paralimbic and somatosensory, viscerosensory functions.¹ Pathology in this integrated cortical area results in many disorders in body.² So anatomical basis of these disorders are very important in early diagnosis and treatment. Trans-sylvian and trans-insular approach are very common in neurosurgeries, it demands detailed knowledge of normal gross anatomy and variations to reduce post-operative complications.³

Insular cortex was considered to be asymmetric pyramid or triangle with three peripheral sulci or peri-insular sulci or limiting sulci (anterior, superior and inferior).⁴ However, later the radiological and cadaveric studies conducted on insula described it to have a trapezoid structure. The posterior periinsular sulcus was differentiated from inferior periinsular sulcus and these two sulci have two different axis separated by an angle.⁵ The Insula is a trapezoid shaped cortical structure with its apex directed anteriorly and inferiorly toward the limen insulae. The limen is located at the junction of sphenoidal and operculoinsular compartments of the sylvian fissure.^{5,6} There are four periinsular sulci, cited superiorly and posteriorly in a radial manner from the apex at the limen insulae.^{5,6}

The central insular sulcus, the main and the deepest sulcus of the insula, courses obliquely across the insula, and extends uninterrupted from the limen insula to the superior peripheral sulcus. It divides the insula into two unequal zones: the larger anterior insula, and the smaller posterior insula.⁷

The larger anterior lobule of insula is composed of three principal short insular gyri (anterior, middle and posterior). Sometimes accessory and transverse gyri are also present. The anterior, middle and posterior short insular gyri are separated by the short insular sulcus and the pre-central insular sulcus respectively.⁸ Precentral gyrus of insula is posterior short gyrus term used by Nagao M.⁹ The Anterior Long Gyrus and Posterior Long Gyrus form the smaller posterior lobule and are separated by the post-central insular sulcus.⁸

Materials and Methods

This study was done in 29 formalin fixed brains (58 right and left cerebral hemispheres) with intact arachnoid matter, all segments of sylvian fissure, gyri and sulci of insular cortex. The study was approved by Scientific Review and Institutional Ethics Committee, Gandhi Medical College, Bhopal (M.P.).

The formalin fixed brains satisfying inclusion criteria were dissected and studied. In order to expose and visualize the insular region, the arachnoid and piamater over the sylvian fissure and middle cerebral artery branches in specially operculoinular compartment were removed. Following standard dissecting procedure, structures under study were observed and recorded. Morphometry was done with the help of Digital Vernier caliper (sensitivity 0.1mm). Statistical analysis of results and comparisons among right and left hemispheres was done and Mean, SD, p value, Unpaired T test, Degree of freedom, SED, and r value Pearson correlation coefficient were analyzed and recorded.

Inclusion criteria: Undamaged specimens of both right and left sided cerebral hemispheres cadaveric brains with intact Insula and sylvian fissure, middle cerebral artery branches of this particular area of concern.

Exclusion criteria: Damaged brain specimens. Infant and Pediatric age group cadaveric brains.

Morphology: The morphological normal and variable patterns as Hypoplastic, Bifid, Trifid gyri, discontinuous sulcus and some joined gyri were observed. Total number of gyri in every insula were also recorded. There was variation in number of gyri because of presence of transverse and accessory gyrus.

Morphometry: According to method of Kaneko et al (2012),⁵ the four points on the angles were marked as Anterosuperior insular point (ASIP), Posterosuperior insular point (PSIP), Anteroinferior insular point (AIIP), Posteroinferior insular point (PIIP). Morphometric measurements were done by using Digital Vernier Caliper and all curved, irregular measurements by using thread and recorded systematically.

- Superior peripheral sulcus- from Anterosuperior insular point to Posterosuperior insular point.
- Inferior peripheral sulcus- from Anteroinferior insular point to Posteroinferior insular point.
- Anterior peripheral sulcus- from Anterosuperior insular point to Anteroinferior insular point.
- Posterior peripheral sulcus- from Posterosuperior insular point to Posteroinferior insular point.
- Central insular sulcus- from superior peripheral sulcus to inferior peripheral sulcus, parallel to Posterior short gyrus and anterior long gyrus exactly between them.

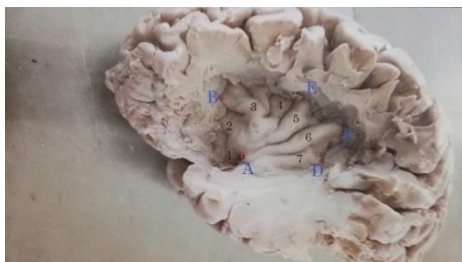

Fig. 1: Insular cortex gyri: 1-transverse gyrus, 2-accessory gyrus, 3-anterior short gyrus, 4- middle

short gyrus, 5-posterior short gyrus, 6-anterior long gyrus, 7-posterior long gyrus

Points: B-Anterosuperior insular point (ASIP), C- Posterosuperior insular point (PSIP), A-Anteroinferior insular point (AIIP), D-Posteroinferior insular point (PIIP). E- Upper central insular point (UCIP).

Insular cortex sulci:

Central insular sulcus (CIS) = from superior peripheral sulcus to inferior peripheral sulcus, parallel to Posterior short gyrus and Anterior long gyrus exactly between them.

Superior peripheral sulcus (SPS) = from Anterosuperior insular point to Posterosuperior insular point.

Anterior peripheral sulcus (APS) = from Anterosuperior insular point to Anteroinferior insular point.

Inferior peripheral sulcus (IPS) = from Anteroinferior insular point to Posteroinferior insular point.

Posterior peripheral sulcus (PPS) = from Posterosuperior insular point to Posteroinferior insular point.

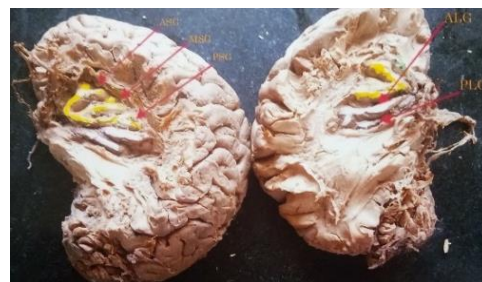

Fig. 2: Left side insular cortex: anterior short gyrus, middle short gyrus, Posterior short gyrus, All 3 Short gyri BIFID. Right side insular cortex: anterior long gyrus BIFID, Posterior long gyrus hypoplastic

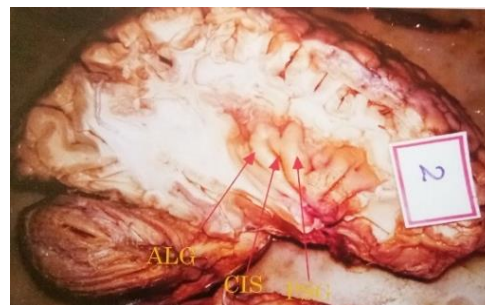


Fig. 3: Discontinuous Central insular sulcus & joined Posterior short gyrus and anterior long gyrus (specimen No. 2 right).

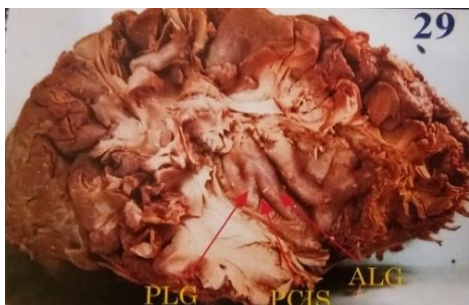


Fig. 4: Discontinuous Post central insular sulcus & joined Posterior long gyrus and Anterior long gyrus (specimen no. 29 right)

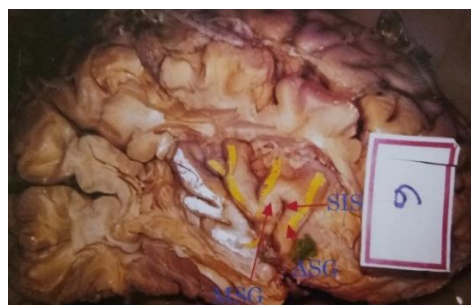

Fig. 5: Discontinuous Short insular sulcus & joined Anterior and Middle short gyrus (specimen No. 6 right).

Observation and Result

Table 1(a): Insular cortex gyri morphology

S. No.	Gyrus		Normal gyrus	Bifid gyrus	Hypoplastic gyrus	Trifid gyrus	Total Gyrus
1	Anterior Short Gyrus	Rt	18	08	0	03	29
		Lt	17	10	0	02	29
2	Middle Short Gyrus	Rt	11	06	11	01	29
		Lt	19	03	07	0	29
3	Posterior Short Gyrus	Rt	24	04	0	01	29
		Lt	24	04	0	01	29
4	Anterior Long Gyrus	Rt	22	06	0	01	29
		Lt	25	03	0	01	29
5	Posterior Long Gyrus	Rt	20	0	09	0	29
		Lt	25	0	04	0	29
	Total	Rt	95	24	20	6	145
		Lt	110	20	11	4	145

Table 1(b):

S. No.	Morphological Parameter	Number (No.)			Percentage (%)		
		Rt.	Lt.	Total	Rt.	Lt.	Total
1	Bifid Gyri	24	20	44	11.82% (24/203)	9.85% (20/203)	10.3% (44/406)
2	Trifid Gyri	06	04	10	02.95% (6/203)	01.97% (4/203)	02.46% (10/406)
3	Hypoplastic Gyri	20	11	31	09.85% (20/203)	05.41% (11/203)	07.63% (31/406)

We observed 58 rights and left cerebral hemispheres. There were a total of 7 gyri present in a cerebral hemisphere. So that 58 x 7 = 406 gyri were observed.

In which 85(20.39%) variable patterns and 321(79.61%) normal pattern were observed. Out of the 21% variable pattern we observed (44/406) 10.3% Bifid, (10/406) 2.46% Trifid and (31/406) 7.63% Hypoplastic Gyri.

Table 2: Transverse and accessory gyri

S. No.	Morphological Parameter	Left side Insula	Right side insula	Total
1	Transverse Gyri present	6/29 (20.68%)	7/29 (24.13%)	13/58 (22.41%)
2	Accessory Gyri present	19/29 (65.51%)	20/29 (68.96%)	39/58 (67.24%)

Table 3: Insular cortex gyri morphometry

S. No.	Gyri	Side	Minimum (mm)	Maximum (mm)	Mean (mm)	SD (mm)
1	Anterior Short Gyrus	Rt.	16.31	34.12	23.87	4.21
		Lt.	19.10	33.02	25.22	3.78
2	Middle Short Gyrus	Rt.	14.11	34.31	24.70	4.98
		Lt.	16.32	34.48	25.39	4.76
3	Posterior Short Gyrus	Rt.	19.21	43.21	33.57	4.46
		Lt.	25.82	44.91	34.60	4.43
4	Anterior Long Gyrus	Rt.	31.13	48.31	36.70	3.64
		Lt.	28.32	47.31	37.05	4.66
5	Posterior Long Gyrus	Rt.	31.64	49.11	38.50	4.65
		Lt.	20.12	47.80	35.31	6.37

Table 4: Insular cortex (SULCI) morphometry

S. No.	Sulci	Side	Minimum (mm)	Maximum (mm)	Mean (mm)
1	Central Insular – Sulcus(CIS)	Rt.	29.8	44.94	35.22
		Lt.	29.08	45.69	35.38
2	Superior Periinsular sulcus (SPS)	Rt.	45.32	63.32	53
		Lt.	46.34	83.91	53.61
3	Anterior Periinsular sulcus (APS)	Rt.	17.28	32.11	23.53
		Lt.	18.13	34.04	25.47
4	Inferior Periinsular sulcus (IPS)	Rt.	22.57	35.56	27.75
		Lt.	16.78	33.72	25.06
5	Posterior Periinsular Sulcus (PPS)	Rt.	10.89	16.89	12.95
		Lt.	8.32	15.82	12.69

Discussion

Insular Cortex- Morphology

Joined Gyri: In joined gyri pattern, there was discontinuous Central insular sulcus so Posterior short gyrus and Anterior long gyrus were joined (specimen No. 2 right). In another insula discontinuous Post central insular sulcus was there and Posterior long gyrus and Anterior long gyrus were seem to be joined (specimen no. 29 right). One insula with discontinuous short insular sulcus was found with joined Anterior and Middle short gyrus (specimen No. 6). Similar type of joined gyri were also reported in radiological study done by Thomas P. Naidich and Kang et al (2004).⁷

Bifid Gyri: In our study 44 Bifid gyri were observed. The Bifid pattern of gyrus was most commonly seen in Anterior Short Gyrus 18 /44 (41%) followed by Middle short gyri 9/44 (20.5%), Posterior short gyri 8/44 (18.0%) and Anterior long gyri 9/ 44 (20.5 %). None of the Posterior long gyrus was bifid. Our study is similar and correlates with radiological study done by Thomas P. Naidich and Kang et al (2004).⁷

Hypoplastic Gyri: In our study 31 Hypoplastic gyri were observed. The Hypoplastic pattern was most commonly seen in Middle Short Gyri 18/31(58%). Hypoplastic pattern was also observed in some Posterior long gyri 13/31(42%). Thomas P. Naidich and Kang et al., (2004) also found in their radiological study that the

Middle short gyri and posterior long gyri were often hypoplastic on sagittal MR images. None of the Anterior short gyrus, Posterior short gyrus or Anterior long gyrus was hypoplastic in our study and same result was reported in the study done by Thomas et al (2004).⁷

Transverse Gyri and Accessory Gyri

In our study total 58 cerebral hemispheres, were observed, out of which there was presence of Transverse Gyri in 13/58 (22.41%) cerebral hemispheres and Accessory gyri in 39/58(65.51%) cerebral hemispheres. The transverse and accessory gyri are present in anterior lobule of insular cortex. Transverse gyrus & Accessory gyrus both were absent in 19/58 (32.76%) cerebral hemispheres in insular cortex & therefore a total no of 5 gyri were found in them. Presence of Accessory gyri but absence of Transverse gyrus was observed in 26/58 (44.82 %) cerebral hemispheres in insular cortex & therefore total no of 6 gyri were found in these hemispheres. Our observation is similar to Thomas et al. (2004), Rhoton et al (2003), regarding presence of transverse and accessory gyri.^{7,4}

Insular Cortex Gyri - Morphometry

In present study the lengths of all the gyri namely Transverse gyrus, Accessory gyrus, Anterior short gyrus, Middle short gyrus, Posterior short gyrus and Anterior long gyrus, Posterior long gyrus were measured which can be of great clinical significance.

Insular Cortex Sulci Morphology

Peripheral sulci - Asymmetric pyramid or Triangle Shape Insula

Thomas P. Naidich and Grant et al., (2004), Oppenheimer and Martin et al., (1996), Ture, Yasargil et al (1999), Feng Wang et al (2011), and Zhang Y et al (2014) considered insular cortex to be asymmetric pyramid or triangle.^{7,10-13}

Rhoton and Tanriover et al (2003), Guenot M (2004) also mentioned it as triangle shaped. So 3 peripheral sulci or peri-insular sulci or limiting sulci were measured (anterior, superior and inferior).^{4,15.}

Peripheral sulci - Trapezoid Shape Insula

Radiological and cadaveric study conducted by Kaneko et al (2012) and cadaveric study conducted by Afif et al (2011) and Jeremy jones (2016) described insula as a trapezoid structure. They differentiated posterior periinsular sulcus from inferior periinsular sulcus and stated that the 2 sulci have two different axis separated by an angle.^{5,6,16} Our study finding coincides with presence of 4 periinsular sulci (anterior, superior, inferior, posterior) clarify trapezoid shape of insular cortex.

Table 5: Comparison of lengths insular cortex sulci morphometry

S. No		CIS	SPS	APS	IPS	PPS	AC	Old IPS
1	Ture et al (1999)		57.6	28.4				49.2
2	Feng Wang et al (2011) ¹¹	32.53	51.61	23.15				46.31
3	Kaneko et al (FFB) (2012) ⁵	34.4	53.1	28.9	31.9	15.9	44.5	
4	Kaneko et al (MRI) (2012) ⁵	34.4	56	29.3	33.5	15.9	45.9	
5	Zhang (Rt) et al (2014) ¹⁰	31.52	51.56	22.5				18.5
6	Zhang (Lt) et al (2014) ¹⁰	31.36	52.05	22.6				48.18
7	Present Study (2017)	35.38	52.48	24.5	26.4	12.81	37.96	

Table 6: Comparison of lengths of insular cortex sulci morphometry (Zhang & Feng Weng)^{10,11} & present study

S. No.	Insular Cortex (Sulci)	Feng Weng (2011) (mm)	Zhang Y (2014) Right (mm)	Zhang Y (2014) Left (mm)	Present study (2017) Right (mm)	Present study (2017) Left (mm)
1	Anterior Periinsular sulcus (APS)	23.15 ±0.47	22.5 ±1.57	22.6 ±3.30	23.53 ±3.55	33.43 ±4.18
2	Superior Periinsular Sulcus (SPS)	51.61 ±1.48	51.56 ±2.90	52.05 ±3.30	51.36 ±4.23	53.61 ±6.75
3	Central Insular Sulcus (CIS)	32.53 ±0.68	31.52 ±2.53	31.36 ±2.68	35.22 ±3.35	35.38 ±4.29
4	Inferior Periinsular Sulcus (CIS)	46.31 ±3.12	48.4 ±3.34	48.18 ±3.34	27.75 ±3.87	25.06 ±4.33
5	Posterior Periinsular Sulcus (PPS)				12.95 ±1.43	12.67 ±1.87

Table 7: Comparison of lengths of insular cortex sulci morphometry kaneko et al 2012 and present study

S. No.		Side	CIS (Kane-ko et al)	CIS (Present study)	SPS (Kane-ko et al)	SPS (Present study)	APS (Kan-ko et al)	APS (Present study)	IPS (Kane-ko et al)	IPS (Present study)	PPS (Kane-ko et al)	PPS (Present study)
1	Min	Rt	27.6	29.8	46.5	45.34	25.7	17.28	29	22.57	12.7	10.89
2	Max	Rt	40.8	44.94	64.3	63.32	31.4	32.11	33.2	35.56	18.3	16.89
	Mean	Rt	35.9	35.22	52.8	53	28.9	23.53	31.4	27.75	16.2	12.95
1	Min	Lt	26	29.08	48.8	46.74	27	18.13	28.2	16.78	12.5	8.32
2	Max	Lt	39.4	45.69	60.1	83.91	32.2	34.04	34.7	33.72	17	15.82
	Mean	Lt	32.9	35.38	53.4	53.61	28.9	25.47	32.4	25.06	15.5	12.67
1	Min	Rt & Lt	26	29.44	46.5	46.04	27	17.05	28.2	19.67	12.5	9.6
2	Max	Rt & Lt	40.8	45.3	64.3	73.6	32.2	33.1	34.7	34.6	18.3	16.4
	Mean	Rt & Lt	34.4	35.3	53.1	52.48	28.9	24.5	31.9	26.4	15.9	12.81

Conclusion

Insular cortex has trapezoid shape with 5 to 7 gyri & sulci. Variation in morphological pattern of gyri are Bifid, Trifid, and Hypoplastic. The Transverse and Accessory gyri are present in anterior lobule, but not

observed in each insula and total number of gyri in anterior lobule depends on their presence. Total number of gyri are more in anterior lobule so it is larger than Posterior lobule. The gyri of anterior lobule are shorter than gyri of Posterior lobule. Posteroinferior insular point PIIP (D) and Upper central insular point UCIP (E)

are important surface landmarks of surgical significance. The corticospinal tract in posterior limb of internal capsule is in posterior relation with this area of insular cortex.

Conflicts of Interest

All authors have none to declare.

References

1. Penfield Wilder and Herbert Jasper. Epilepsy and the Functional Anatomy of the Human Brain Vol.119, Issue 3097pp. 645-6.
2. C Stephani, G .Fernandez _Baca Vaca. Functional neuroanatomy of the insular lobe. Brain structure function .2.11 jun; 216(2);137-49.
3. Matthew B. Potts, Edward F. Chang, Michael T. ,Transsylvian –Transinsular Approaches to the Insula and Basal Ganglia ; Operative Techniques and Results with Vascular Lesions .Neurosurgery.2012 Apr;70(4);824-834.
4. Albert Rhoton; Cranial anatomy and Surgical Approaches, Neurosurgery. Rhoton's Anatomy volume 53 part 2, October 200,page 26–156.
5. Kaneko ,Nobuyuki MD ,Boling ;Delineation of the Safe Zone in Surgery of Sylvian Insular Triangle ; Morphometric Analysis and Magnetic Resonance Imaging Study. Neurosurgery;june 2012 volume 70.
6. Afif, Mertens P Description of sulcal organization of the insular cortex. Surg Radiol Anat. June 20, volume 32, issue 5,pp 491-98.
7. Thomas naidich, Kang E, (2004) The insula; anatomic study and MR imaging display at 1.5 T. Am J Neuroradiol 25(2)222-32.
8. Tanriover N, Kawashima M. Rhoton Jr A et al. Microsurgical anatomy of the insula and sylvian fissure. J Neurosurg. 2004-may 100(5):891922
9. Nagao M, Takeda K, Komori T, Isozaki E, Hiraj S. Apraxia of speech associated with an infarct in the precentral gyrus of the insula. Neuroradiology 1999;41:356-7.
10. Zhang Y, Wang H, Qian D .Anatomical study of insula and its relationship with the adjacent structures. J Craniofac Surg.2014 sept;25(5);1895.
11. Feng Wang,Tao Sun ,He chun.Microsurgical and tractographic anatomical study of insular and transsylvian transinsular approach. Neurol Sci 2011 Oct 32 (5);865-74.
12. Ture U,Yasargil DCH, AI-Mefty O, Yasargil MG. Topographic anatomy of the insular region. J Neurosurg 1999;90:720-33.
13. Oppenheimer SM. Kedem G. Martin WM. Left-insular cortex lesions perturb cardiac autonomic tone in humans. Clin Auton Res 1996;6:131-40.
14. Yasargil DCH, AI-Mefty O, Yasargil MG, Ture U. Topographic anatomy of the insular region. J Neurosurg 1999; 90:720-33.
15. M Guenot Isnard J Sindow M. Surgical anatomy of insula .Adv Tech Stand Neurosurgery 2004,29.265-88.
16. Dr. Yair Glick and Dr Jeremy Jones;Insular cortex /Radiological Reference Article / Radiopaedia 23 sept 2015 [https:// radiopaedia .org](https://radiopaedia.org)