

Study of anatomic variations of human gall bladder and its clinical importance

Suman Tiwari

Associate Professor, Dept. of Anatomy, MVJ Medical College & Research Hospital, Bangalore, India

Running title: Study of Anatomic Variations of Human Gall bladder and its Clinical Importance

Corresponding Author:

E-mail: sumanravi80@gmail.com

Abstract

Introduction: One of the most important and commonly performed surgeries in the abdominal region is the surgery of gall bladder. Hence it is desirable for the surgeons who are operating in the region of gall bladder and biliary tract to know the possible variations in the anatomy of gall bladder that can be confronted. The present study describes the anatomic variations of gall bladder and its clinical importance. **Materials and Methods:** 50 gall bladder specimens procured from embalmed human adult cadavers of both sexes available in Anatomy Department of MVJ Medical College, Bangalore were studied. The different parameters studied were the measurements of gall bladder which included its length & breadth, shape, position & external variations.

Results: The mean length and breadth of the gall bladder was found to be 6.79 cm & 2.81 cm respectively. The various shapes of the gall bladder noted were pear shaped (52%), flask shaped (28%), cylindrical (12%), irregular (4%) and hour-glass (4%). In 49(98%) specimens, the position of gall bladder was beneath the right lobe of the liver. Gall bladder was intrahepatic in position in 1 (2%) specimen. The external variations of gall bladder observed in 9(18%) specimens were in the form of folding of the neck, folded fundus (phrygian cap) & Hartmann's pouch.

Conclusion: The knowledge of the possible anatomic variations of the gall bladder is of utmost significance to radiologists who should detect them preoperatively using special radiological procedures and to surgeons during laparoscopic cholecystectomy to reduce the incidence of post-operative complications.

Keywords: Gall Bladder, Hartmann's pouch, Morphology, Phrygian cap, Variations.

Received: 13th July, 2017

Accepted: 03rd November, 2017

Introduction

The gallbladder is a flask-shaped, blind-ending diverticulum having a fundus, body and neck. In life, its colour is grey-blue and has a capacity of 30-50 ml. Its length measures between 7-10 cm and has a maximum breadth of 3 cm. It is situated obliquely in a non peritoneal fossa on the under surface of the right lobe of the liver. The neck of the gall bladder which is continuous with the cystic duct drains into the right side of the common hepatic duct.

Gall bladder varies greatly in its size and shape. It may be duplicated, bifid or sometimes absent. A variation seen in the fundus of the gall bladder is phrygian cap. This variation is seen as septum within a normal gall bladder on ultrasound examination.¹

The gall bladder and biliary tract are the structures in close connection with the adjacent organs and may show various anomalies and anatomic variations which become crucial during surgical settings.²

A rudimentary gall bladder may be associated with other congenital anomalies such as tracheo-oesophageal fistula or imperforate

anus.³ Some other anatomic variations include double & triple gall bladder, irregular gall bladder, longitudinally divided or constricted gall bladder.

Gall bladder also varies in its position. Some of the abnormal positions include intrahepatic, retro hepatic, suprahepatic, retroperitoneal, anterior epigastric, floating and transverse position.⁴

One of the most frequent sites of operative intervention is biliary tract, with an estimated 850,000 biliary tract procedures performed every year in our country. The most common operative procedures performed on biliary tract is cholecystectomy.⁵

Anatomic variations of gall bladder & biliary tract are important during any operative procedures because failure to recognize them may lead to inadvertent ductal ligation, biliary leaks and strictures after laparoscopic cholecystectomy.⁶ The present study describes the different anatomic variations of human gall bladder and its clinical importance.

Materials and Methods

The study was done on fifty specimens of gall bladder available in Anatomy Department of MVJ Medical College, Bangalore. The specimens of gall bladder were procured from embalmed human adult cadavers of South Indian population irrespective of their sex. The abdominal cavity was opened and the peritoneal cavity exposed. All the specimens of gall bladder were numbered and different parameters were measured. The different parameters studied are measurements of gall bladder which includes its length & breadth, shape, position & external variations. Length (cm) and breadth (cm) of the gallbladder wall was measured with a Vernier caliper. To obtain the length of the gallbladder, it was measured from fundus to neck. The maximum breadth of the bladder was measured. The shape of the gall bladder was noted in all the specimens. Its position and any external variations if present, was also noted. The data obtained was entered in Microsoft excel and analyzed using SPSS 16th version. Mean and standard deviation was calculated. The obtained results were compared with that of previous studies.

Results

The minimum length of the gall bladder was found to be 5 cm and its maximum length was 10 cm. The mean length was 6.79 ± 1.45 cm. The minimum and maximum breadth of the gall bladder was found to be 2.4 cm and 4.7 cm respectively and the mean breadth was 2.81 ± 0.79 . Pear shaped (Fig. 1) gall bladder was found in 26 (52%) specimens. The other different shapes of the gall bladder observed in the present study and their percentages are summarized in Table 1 and Fig. 2 a, b, c, d. In 49 (98%) specimens, the position of gall bladder was beneath the right lobe of the liver. In 1 (2%) specimen (Fig. 3) the gall bladder was intrahepatic in position. The external variations of the gall bladder observed in 9 (18%) specimens were in the form of folding of the neck, folded fundus (Phrygian cap) and hartmann's pouch. Out of the 9 (18%) specimens, folding of the neck (Fig. 4A) was found in 3(6%), folded fundus (Phrygian cap-Fig. 4B) in 2(4%) and hartmann's pouch (Fig. 5) in 4(8%) specimens.

Table 1: Showing different shapes of gall bladder

Shape	Number	Percentage
Pear shaped	26	52%
Flask shaped	14	28%
Cylindrical	6	12
Irregular	2	4
Hour glass	2	4

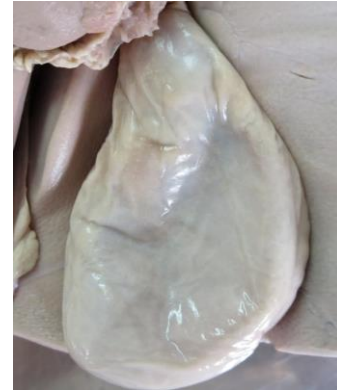

Fig. 1: Pear shaped gall bladder

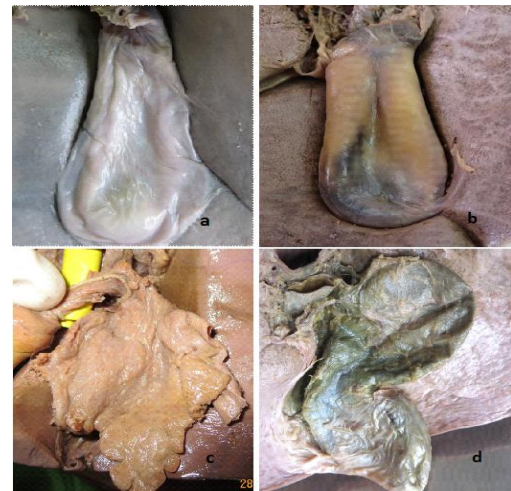

Fig 2: Different shapes of gall bladder: a) Flask shaped b) Cylindrical shaped c) Irregular shaped d) Hour glass shaped

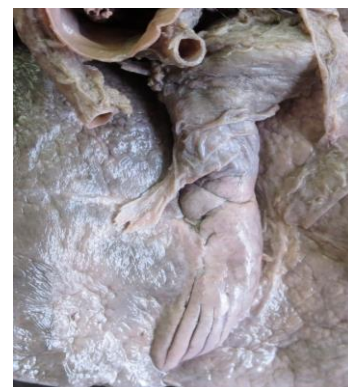

Fig. 3: Intrahepatic gall bladder

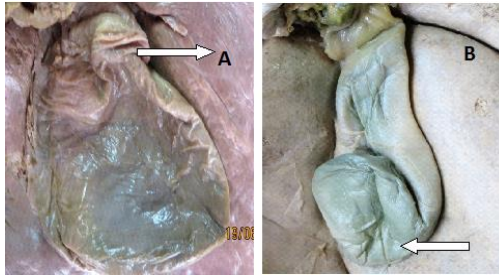


Fig. 4: Gall bladder showing folding of neck (A) and folded fundus (B)

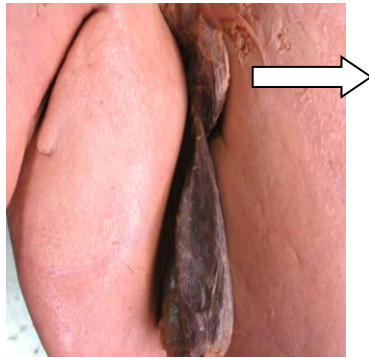


Fig. 5: Gall bladder showing hartmann's pouch

Discussion

The measurements of the gall bladder and its shape reported by different authors are summarized in Table 2. The results of the present study are similar to that of the previous authors.⁵⁻⁹

Cholecystomegaly has been reported in a number of disorders such as diabetes (because of an autonomic neuropathy) and after truncal and selective vagotomy. The gallbladder also becomes larger than normal during pregnancy, in patients with sickle hemoglobinopathy, and in extremely obese people. Micro gall bladder is seen in persons with cystic fibrosis.¹⁰

The hepatic diverticulum which appears first on 18th day projects ventrally & cranially into surrounding mesoderm of septum transversum. Around 23-25th somite stage, the hepatic diverticulum enlarges and gets divided into a large cranial portion pars hepatica & a small caudal portion pars cystica. The pars cystica gives rise to gall bladder & cystic duct.¹¹ Any aberration or arrest during normal embryological development results in variations.

Talpur¹² studied 300 patients in whom laparoscopic cholecystectomy was performed and found variations in the anatomy of extrahepatic biliary system. Variations of the gall bladder were seen in 2% of subjects. The variations seen were in the form of buried gall bladder (1%), floating gall bladder (0.33%) and

Phrygian cap gall bladder (0.33%). Intrahepatic gall bladder was found in 1(2%) of specimens in the present study.

One of the abnormal positions of gall bladder is intrahepatic gallbladder. An intrahepatic gall bladder may present as partial type or complete type. In partial type, a part of the gall bladder may project outside from within the liver, but in complete type, the gall bladder is completely embedded within the parenchyma of the liver. This variant may pose a threat to the surgeons. It is a developmental anomaly and is caused due to congenital arrest in the movement of gall bladder from its intrahepatic position in the 2nd month of gestation to its normal superficial location.

Adults with intrahepatic gall bladder are more prone for cholelithiasis due to incomplete emptying of the gall bladder caused by stasis. This variant can be readily diagnosed by ultrasonography or CT scan.¹³

The diagnosis of cholecystitis in patients with intrahepatic gall bladder is complicated as there are no signs of inflammation of peritoneum due to long distance between the gallbladder and peritoneum. The preferred treatment of choice for cholelithiasis in patients with intrahepatic gall bladder is cholecystostomy rather than cholecystectomy as cholecystectomy is threatening in persons with such anomaly.¹⁴

The external variations of the gall bladder of the present study are compared with that of the previous authors.^{5-7,9,15,16} (Table 3). The variations of the present study in the form of folded neck (6%), folded fundus (Phrygian cap) (4%), hartmann's pouch (8%) closely correlates with that of the previous studies.

Phrygian cap, a triangular deformity of gall bladder fundus in which the fundus is folded on the body resulting in partial separation of the fundus from the body is considered as a normal anatomical variant of gall bladder. It is caused by a localised thickening of the gallbladder wall and is of little significance as the gallbladder function is usually normal.^{2,3}

The incidence of Phrygian cap was reported in 3%-7.5% by Lichtenstein & Nicosia.¹⁷ They also explained that this variant is caused due to differences between the between the gall bladder bed and its size.

This variant is asymptomatic and can be diagnosed on x-ray or ultrasound. This anomaly is of two types. In the retroserosal or concealed type, the peritoneum completely invests the gall bladder, but in serosal or visible type, the peritoneum gets reflected on itself after it follows the bend in the fundus. This variant may sometimes simulate a mass in the liver. It is of

no clinical significance unless mistaken for a layer of stones or hyperplastic cholecystosis.^{10,16}

A diverticulum or a widening seen at the lateral end of the neck of gall bladder is hartmann's pouch. It is of two types namely congenital and acquired type. In congenital type all the three layers of gall bladder wall are present, whereas the acquired variety is a result of any disease process and has little or no smooth muscle in its wall. It may present with an array of clinical signs and symptoms and is often associated with cholelithiasis and carcinoma of the gall bladder.

A large hartmann's pouch may obscure cystic duct & calot's triangle.¹⁸ When the gall

stones get impacted within the hartmann's pouch, bile gets absorbed resulting in the collection of mucous (mucocele) within the pouch. The external compression of the common hepatic duct or common bile duct caused due to gall stones impacted within the hartmann's pouch results in a rare complication known as Mirizzi's syndrome. It is characterised by intermittent or persistent jaundice. The identification of the presence of hartmann's pouch should be done preoperatively before any surgery to prevent intra operative and post operative complications.

Table 2: Showing measurements and shape of gall bladder reported by different authors

Author	Number of specimens	Length	Breadth	Shape
Nadeem	70	4.5-11.6	2.7-5.2	Pear (82.85%), flask (2.86%), Cylindrical (2.86%), irregular (1.43%), Bilobed (1.43%), others (7.14%)
AV Prakash	90	7-10	2-5	Pear (82.22%), others (17.78%)
Rajguru	60	5-12	2.5-5	Pear (85%), flask (5%), cylindrical (3.33%), Irregular (1.67%), hourglass (3.33%), Retort (1.67%)
Rajendra	78	4-11	2.5-5	Pear(53.2%),cylindrical(11.4%), hourglass(6.3%)oval(11.4%)others(16.5%)
Desai	50	4.5-11	2.8-5	Pear(84%),cylindrical(10%),hour-glass(2%), retort(4%)
Present study	50	5-10	2.4-4.7	Pear (52%), flask (28%), cylindrical (12%), Irregular (4%) hourglass (4%)

Table 3: Showing external variations of gall bladder reported by different authors

Author	Folded neck	Folded fundus (phrygian cap)	Hartmann's pouch
Nadeem	-	-	5(7.14%)
Prakash AV	4(4.44%)	5(5.56%)	-
Rajguru	3(5%)	3(5%)	-
Desai	2(4%)	2(4%)	-
Nahar	-	-	4(5.7%)
Dundareddy	-	1(2%)	2(4%)
Present study	3(6%)	2(4%)	4(8%)

Conclusion

The study provides details of the anatomic variations of the gall bladder. Appreciation and awareness of these anomalies is of considerable importance to radiologists to differentiate riedel's lobe of liver with the variations of the gall bladder. Furthermore, knowledge of variant anatomy of gall bladder is of greatest significance to laparoscopic surgeons during cholecystectomy to prevent disastrous

consequences during surgery such as hepatobiliary injuries, haemorrhage and haemobilia. It also reduces morbidity, conversion and re-exploration in such patients.

Acknowledgement

I sincerely thank our principal of MVJ Medical College & Research Hospital, Bangalore, for giving me permission to carry out the research work.

Funding: None

Conflict of interest: None declared

Ethical approval: Not required

References

1. Standring S; Gray's anatomy. The anatomical Basis of clinical Practice, 40th edition, Elsevier Churchill Livingstone, Philadelphia, London 2008, pp 1177-81.
2. Piracci A, Mitrusi A, Totozani D. ultrasound examination of anatomical variations of the gall bladder. Albanian medical journal.2013;1:88-91.
3. Beckingham IJ. The gall bladder and bile ducts. Association of laparoscopic surgeons .1-12.
4. Bergman RA, Afifi AK, Miyauchi R. Illustrated Encyclopedia of Human Anatomic Variation: Opus IV: Organ Systems: Digestive System and Spleen. Gallbladder.
5. Nadeem G. A study of the clinico-anatomical variations in the shape and size of gallbladder J. Morphol. Sci. 2016;33(2):62-7.
6. Prakash AV, Panshewdikar PN, Joshi DS, Anjaankar AP. A cadaveric study involving variations in external morphology of gall bladder. Int J Med Res Health Sci. 2013;2(2):239-42.
7. Rajguru J, Khare S, Jain S, Ghai R, Singla M, Goel P. Variations In The External Morphology of Gall Bladder. J. Anat. Soc. India. 2012;61(1):9-12.
8. Rajendra R, Makandar UK., Tejaswi HL, Patil BG. Morphometric Study of Gall Bladder In South Indian Population(cadaveric study).Indian Journal of Forensic and Community Medicine. 2015;2(1):35-42
9. Desai J , Bhojak N. Study of Variations in External Morphology of Gall Bladder in Cadavers BJKines-NJBAS.2015;7(1):29-33.
10. Gore RM, Fulcher AS, Taylor AJ Ghahremani GG. Textbook of gastrointestinal Radiology in Anomalies and Anatomic Variants of the Gallbladder and Biliary Tract: 2nd ed. B Saunders Co Philadelphia, PA;2000;1305-20.
11. Hamilton, Boyd, Mossman. Human Embryology (Prenatal development of form and function). 1971; 5th edition: Lambridge. W. Heffer & sons limited.
12. Talpur KAH, Laghari AA, Yousfani SA, Malik AM, Memon AI et al. Anatomical variations and congenital anomalies of Extra Hepatic Biliary System encountered during Laparoscopic Cholecystectomy. J Pak Med Assoc. 2010;60(2):89-93.
13. Manjit Singh Khalsa, Hari JP, Dutta A. Cholecystectomy for intrahepatic gall bladder with incidental subhepatic appendix: a challenge for the surgeon. International Journal of Research in Health Sciences. 2017;5(2):16.
14. Hassan A, Zargar SA, Malik A, Shah P. Surgical significance of variations in the anatomy in the biliary region. Int J Res Med Sci. 2013;1(3):183-7.
15. Nahar N, Ara S, Rahman M, Shahriah S, Afroz H et al. Presence of hartmann's pouch in human gall bladder. Bangladesh Journal of Anatomy. 2012;10(2):57-8.
16. Dundareddy R, Sumana R. Comparative study of Human Gall Bladder variations in south Indian population. International journal of scientific research. 2017;6(4): 36-8.
17. Lichtenstein M. & Nicosia, A.J. The clinical significance of accessory hepato-biliary ducts. Annals of Surgery. 1955;141:120-4.
18. Choudhury P. Relevant Biliary Anatomy during cholecystectomy. Journal of evolution of medical & dental sciences. 2014;3(35):9332-42.