

Study of diaphyseal nutrient foramina in human typical lower limb long bones

Prasanna Shravan Gaydhanker^{1,*}, Sanjay Mansingh Rathod²

¹Assistant Professor, ²Professor & HOD, Dept. of Anatomy, Shri Bhausheb Hire Government Medical College, Dhule, Maharashtra, India

***Corresponding Author:**

Email: pras_mbbs@rediffmail.com

Abstract

Higher percentage of the nutrient foramina on femur was double while tibia and fibula showed single nutrient foramina. We studied the number, size, direction and foraminal index of diaphysis nutrient foramina of femur tibiae & fibulae in manner in which other authors studied. For the study, 450 dry bones (150 femora, 150 tibiae and 150 fibulae) of adult subjects of unknown sex & age were used from the Anatomy Museum of Government Medical College Miraj & Other medical colleges in Maharashtra, India. Of the 150 femora, tibiae & fibulae dominant foramina were 120(61.54%), 67(42.14%) & 32(20.38%) respectively and secondary foramina were 75(38.46%), 92(57.86%) & 125(79.62%) respectively. This information will be of great importance to orthopedician surgeons performing surgical procedures of the lower limb fractures.

Aim and Objective: A detailed study was conducted for: Number and size of nutrient foramina in human lower limb typical long bones; Direction of nutrient foramina; Foraminal index.

Keywords: Femur, Fibulae, Foraminal index, Nutrient foramina, Tibiae, Typical lower limb long Bones.

Received: 6th August, 2017

Accepted: 7th November, 2017

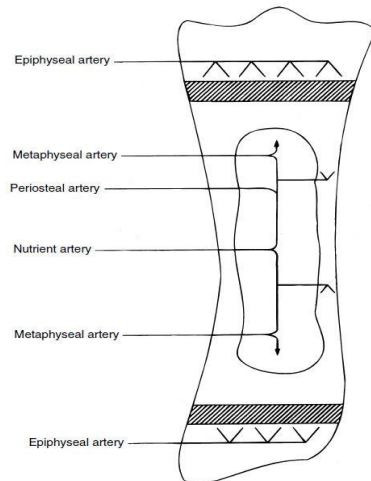
Introduction

Role of nutrient foramina in nutrition and growth of bones is evident from term "Nutrient". During active growth period in embryo, foetus, early ossification phase and in vascular necrosis nutrient artery is very important.¹⁻³ Long bones generally derive their blood supply from diaphysial nutrient arteries and other arteries like periosteal, metaphysial and epiphysial arteries. Nutrient artery enters shaft through nutrient foramen, runs through the cortex and divide into ascending and descending branches in medullary cavity. Each branch further divides into a number of small parallel channels which terminate in adult metaphysis by anastomosing with the periosteal, metaphysial and epiphysial arteries.² Diaphyseal nutrient artery entry diaphysis of the long in oblique way, their point of entry and angulation is relatively constant. As observed diaphyseal nutrient vessels move away from the growing end of the bone. In lower limb growing end of femur is lower end and of tibia is upper end while fibula has lower end as growing end. Blood supply of the long bones is also derived from the periosteal, metaphysial and epiphysial arteries, which are very important forming a series free of intrabone anastomosis.

The nutrient artery of the femur is general derived from the second perforating artery and when two nutrient arteries are present, they tend to detach from the first and third perforating

arteries. According to some fibula may show obliquely downward directed diaphyseal nutrient foramina as its growing end is toward medial malleolus. The study showed detail blood supply pattern of the femur, tibia and fibula bones by identifying number, size direction and foraminal index with respect to the diaphyseal nutrient foramina. Periosteal artery supply outer 1/3rd and nutrient artery supply medullary cavity, inner 2/3rd cortex and metaphysis this blood supply pattern help us to understand success of nailing of long bone fractures. It is an observational type of study as a very important characteristic. Variations have been described in the direction of nutrient foramina only in the lower limb bones.⁸ A considerable interest in studying nutrient foramina resulted not only from morphological, but also from clinical aspects. Nutrient foramina reflect to certain degree the bone vascularization. Some pathological bone conditions such as developmental abnormalities, fracture healing or acute hematogenic osteomyelitis are closely related to the vascular system of the bone.

Nutrient foramen is directed away from growing end of the bone. Their direction are indicated by a jingle, "to the elbow I go, from the knee I flee."²



Material and Methods

Study area and place: A random study was carried out on bones on the bones of Anatomy Dept. at Government Medical College, Miraj and other Anatomy Dept. of Government Medical Colleges.

Sample size: The sample size of present study was 450 bones. These 450 bones were divided into three groups. Each group had 150 bones

Foraminal index formula:

Foraminal index = $\frac{\text{the distance from the proximal end of the bone to the nutrient foramen} \times 100^{4,5}}{\text{Total bone length.}}$

Total length of bone in centimetre was estimated with help osteometric board:

Femur: the distance between the proximal highest point of the head of the femur and the most distal point of the medial condyle.

Tibia: the distance between the proximal margin of the medial condyle and the medial malleolus tip.

Fibula: the distance between the apex of the head of the fibula and the lateral malleolus tip.

Statistical Analysis

Statistical analysis was done by using the Statistical Package of Social Sciences (SPSS) and tables were tabulated by Microsoft office excel 2010 and windows8.0. The range, mean and standard deviation of Foraminal index were calculated.

each that is 150 Femora, 150 Tibiae & 150 Fibulae.

Sample selection criteria: Apparently normal, cleaned and dried human adult Femur, Tibia and Fibula without any gross anatomical deformity were selected for study, with no appearance of gross pathological changes. Age and sex of bones were not tried to determine. Bones of medico - legal cases were excluded from study. Side determination of Femur, Tibia and Fibula was not attempted in present study. Foramina at lower end of bones were ignored.

Photographs: Photographs were taken with the help of sony high definition camera of 16 mega pixels.

Methodology

1. Nutrient foramina number was counted and a detailed study was done for its size and direction.
2. With help of a hand-lens nutrient foramina were Identification as elevated margins and by presence of a distinct groove proximal to them.
3. Only well-defined diaphyseal foramina were accepted.
4. Foraminal index was calculated.

Result

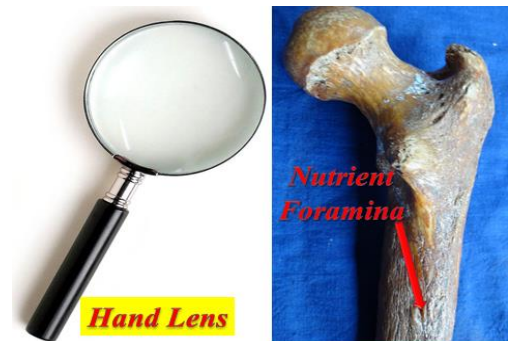

Fig. 1



Fig. 2: To see the size 24 No. hypodermic needle (0.56 mm in diameter) was used

Nutrient foramina smaller than the size of 24 hypodermic needle (0.56 mm in diameter) are secondary nutrient foramina (S.F) while those equal or larger are dominant nutrient foramina (D.F)^{8,12}

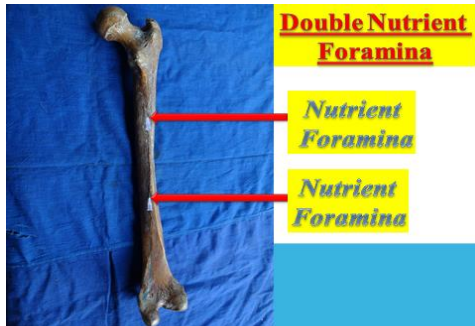


Fig. 3

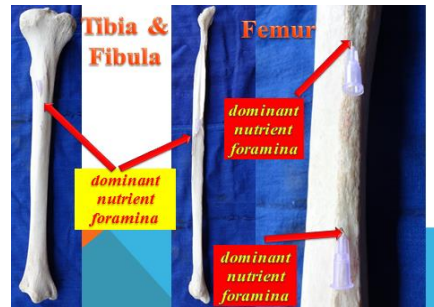


Fig. 4

Nutrient foramina numbers were as follows: After examining each group which had 150 bones each, that is 150 Femora, 150 Tibiae & 150 Fibulae. We saw in case of femur 105 (70%) single nutrient foramina while 45 (30%) double nutrient foramina. Whereas tibia and fibula showed 141 (94%) and 143 (95%) single nutrient foramina respectively while it also reflected 9 (6%) and 7 (5%) double nutrient foramina respectively.

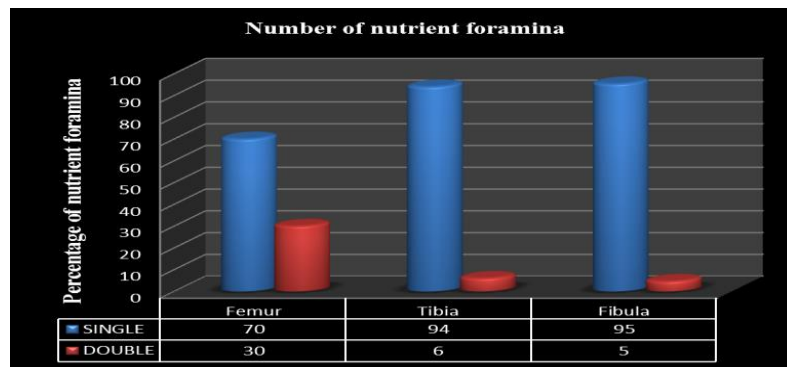


Fig. 5

Of the 150 femora, tibiae & fibulae dominant foramina were 120(61.54%), 67(42.14%) & 32(20.38%) respectively and secondary foramina were 75(38.46%), 92(57.86%) & 125(79.62%) respectively. Which were further tabulated as single dominant nutrient foramina, single secondary nutrient foramina, doublele dominant nutrient foramina and double secondary nutrient foramina. This all result is tabulated as follow:

Table 1: Nutrient foramina size

Bones	Nutrient foramina number	Dominant/ Secondary	Number	%
Femur (n=150)	Single	DF	59	30.26
		SF	46	23.59
	Double	DF	61	31.28
		SF	29	14.87
Tibia (n=150)	Single	DF	60	37.74
		SF	81	50.94
	Double	DF	7	4.4
		SF	11	6.92
Fibula (n=150)	Single	DF	27	17.2
		SF	116	73.89
	Double	DF	5	3.18
		SF	9	5.73

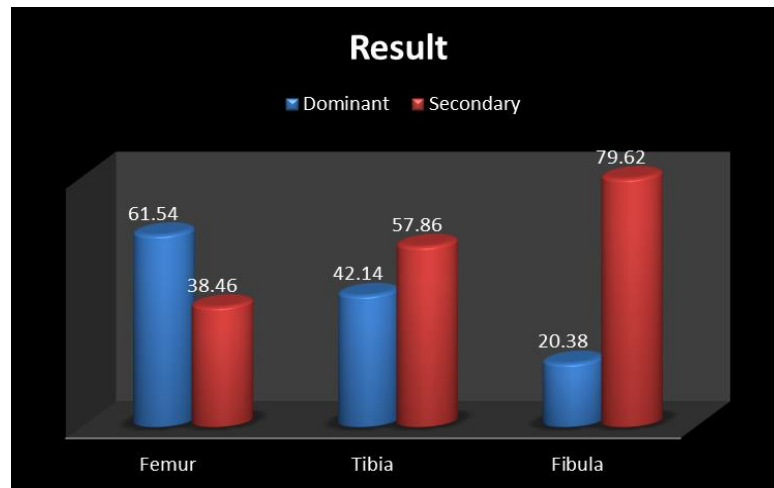


Fig. 6

Foraminal index was as follow: Foraminal index of femur ranges from 30.39 to 65.75 of tibia from 35 to 69.34 and of fibula from 32.18 to 73.24 while mean of femur, tibia and fibula is 43.74, 47.62 and 48.05 respectively.

Table 2

		Femur	Tibia	Fibula
Mean + Standard Deviation Of Foraminal index		43.74 ± 9.88	47.62 ± 8.56	48.05 ± 8.98
Range Of Foraminal index	Lowest	30.39	35	32.18
	Highest	65.75	69.34	73.24

Direction of nutrient foramina: All the studied femora showed the nutrient foramina which were directed proximally, while opposite was seen in case of tibiae the nutrient foramina of all examined tibiae were directed distally. But fibulae showed a different picture of the total 157 nutrient foramina observed in the fibulae 124 (78.98%) was directed distally while the direction of 33 (21.02%) was proximally directed.

Discussion

In this study, 30% of the femora examined possessed double nutrient foramina, and 70% possessed single nutrient foramen. Many authors study showed highest percentage of femora with double nutrient foramina which was not seen in our study results,^{6,7} while others study reported the presence of a single foramen in most of the femora.⁸⁻¹⁰ Few studies also reported three nutrient foramina but to low percentage that is (2.19% - 10.7%).⁷⁻⁹ Few studies were very interesting as their result showed femur with six to nine nutrient foramina on diaphysis.¹⁰ While other confirmed the absence of nutrient foramina in some femora.⁶

Present study showed 94% of the tibiae with double nutrient foramina and 6% tibiae with single nutrient foramen. Past studies result reflected 90% of the tibiae with one nutrient foramen.⁶⁻⁸

95% of Fibulae showed of one nutrient foramen and 5% of the Fibulae with two nutrient foramina. But 80% of Fibulae with one nutrient foramen & 20% of Fibulae with two nutrient foramina were seen in study of many authors,^{6,8,10} which was somewhat close to our results. Few studies showed absence of nutrient foramina on fibulae.^{6,12}

In our study results femora showed exceptional highest percentage of dominant nutrient foramina, while in tibiae, fibulae showed exceptional highest percentage of secondary nutrient foramina. To some extent similar result was observed in other studies of Longia et al. (1980)⁸ whose result showed that about 66.67% of the nutrient foramina were secondary.

The present study indicates that nutrient foramina in the femora, tibiae were directed away from the growing end which was in similar fashion reported by Mysorekar, 1967⁶ in his study.

Conclusion

1. Single & Double dominant type of foramina were almost of equal percentage in femur,
2. Majority of Single foramina present in tibia and fibula were majority of secondary type.
3. Nutrient foramina Direction follow growing end theory.
4. This Study is of great importance to Anatomists during dissection to study normal course of nutrient artery & to Orthopaedic surgeons performing surgeries of the lower limb fractures to avoid bleeding due to accidentally perforating of the nutrient artery during operations.

Acknowledgment

I am very thankful to Dr. N G Herakar sir H.O.D of government medical college Miraj and Dr. Sanjay M Rathod sir H.O.D of government medical college Dhule for their bone library permission and their greatful guidance. And very thankful to my wife Dr. Anuradha. P. Gaydhanker (M.D P.S.M) for calculation & bar graphs.

References

1. Fraizer, Ernest J. The Anatomy of Human Skeleton (1964);4th Edition:p5.
2. Chaurasia's BD. Hand book of General Anatomy 3rd Ed., Page 35-6.
3. Gray's Anatomy (1992);38th Ed:p469.
4. Hughes, H. (1952). The factors determining the direction of the canal for the nutrient artery in the long bones of mammals and birds. Acta anat. 15:261-80.
5. Shulman, S.S. (1959). Observations on the nutrient foramina of the human radius and ulna. Anat. Rec.134:685-97.
6. Mysorekar VR. Diaphysial nutrient foramina in human long bones. J Anat. (1967);101:813-22.
7. Nagel A. The clinical significance of the nutrient artery. Orthop. Rev. (1993);22:557-61.
8. Longia GS, Ajmani ML, Saxena SK, Thomas RJ. Study of diaphyseal nutrient foramina in human long bones. Acta Anat. (Basel) (1980);107:399-406.
9. Lutken P. Investigation into the position of the nutrient foramina and the direction of the vessel canals in the shafts of the humerus and femur in man. Acta anat. (1950);9:57-68.
10. Sendemir E, Cimen A. Nutrient foramina in the shafts of lower limb long bones: situation and number. Surg. Radiol. Anat. (1991);13:105-8.
11. Position of nutrient foramen on the shaft of human long bones, J. Anat. Socy. India;16:54-63.
12. Emine Kizilkanata, Neslihan Boyana, Esin T. Ozsahina, Roger Soamesb, Ozkan Oguza .Location, number and clinical significance of nutrient foramina in human long bones. Ann. Anat. (2007);189:87-95.