

Meckel's Diverticulum: A case report

D. N. Sinha

Formerly Professor & HOD, Govt. Medical College, Haldwani, Uttarakhand

Email: drdnsinha@hotmail.com

Abstract

An embryological & surgical entity of the Meckel's diverticulum has been studied in the incidental finding in a female patient admitted to hospital for the abdominal injury. Histological studies revealed absence of heterotrophic gastric and pancreatic tissue. However, the diverticulum did show thick longitudinal muscle and thinner circular muscle coat as compared to the adjacent normal Ileal tissue. In view of the existing literature, the presence of heterotrophic tissue could be as a result of genetic influence, a hypothesis needs further study.

Keywords: Meckel's diverticulum, Heterotrophic Gastric mucosa, Pancreatic tissue

Received: 7th November, 2016

Accepted: 11th July, 2017

Introduction

Meckel's Diverticulum importance has been further advocated by Aarnio and Salonen⁽¹⁾ that the diverticulum should be searched in a Laparotomy due to acute abdomen. It is also documented that the majority of people afflicted with Meckel's diverticulum are asymptomatic. Cennamo et al⁽²⁾ recommended that the diverticulum should be totally removed even when it is asymptomatic because the problem arising secondary to complications are more severe compared to any discomfort following surgical removal.

Case Report

A female patient aged 35 years was admitted in Dr. Sushila Tiwari Government Hospital, Haldwani with abdominal injury. During emergency exploratory laparotomy, the small bowel injury was repaired and the incidental presence of Meckel's diverticulum along with a part of Ileum was resected out in anticipation that it might not cause abdominal problem in future. The female patient had no earlier symptoms related to the peptic ulcer and associated problem pertaining to the presence of this embryological and surgical entity.

Materials and Method and Observation

On examination, the resected part of Ileum showed the Meckel's diverticulum two feet away from Ileocaecal junction and the length was nearly two centimeter with little finger breadth. It was supplied by Ileal branch of superior Mesenteric artery as usual. The diverticulum did not reveal any evidence in favour of inflammatory disorder. The tissue of diverticulum and adjacent Ileal tissue were subjected for the histological study. (Fig. 1)

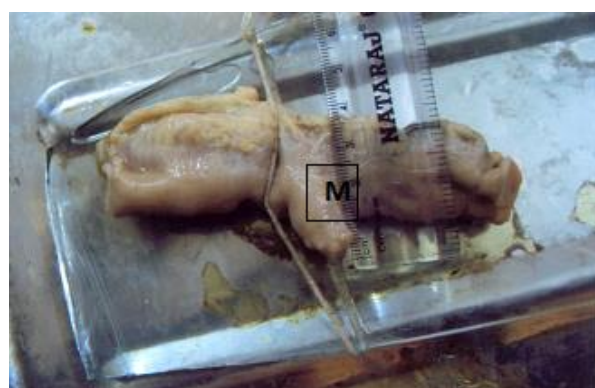

Fig. 1: Photograph showing the Meckel's Diverticulum (M)

Discussions

As usual the surgical description goes long back to the surgical history, where Meckel's diverticulum although originally described by FABRICUS HILDANUS in 1598, is named after JOHANN FRIEDRICH MECKEL, who established its embryonic origin in 1809. Although Meckel's diverticulum is usually of no medical significance, two types of complications can require clinical attention. One involves ectopic mucosal tissue and most often leads to GI bleeding in younger children. In second type the sequele of the diverticulum involves an aberrant intra abdominal tissue. Surgical significance and its importance in surgical practice has been extensively reviewed in existing literature.

From 1 to 4 feet away from the end of Ileum, a diverticula (Meckel's) is seen sometimes, a diverticulum (Meckel's) which presents the remains of vitello intestinal duct. It is expected in 2% subject. This diverticulum exists as a tube of the same structures as of Intestine. However, the length varies. At the apex of the Meckel's diverticulum gastric mucous membrane is some time found.⁽³⁾ The diverticulum is situated at the antimesenteric border of the Ileum. The diverticulum has

been found in 1% to 2.5% of the person who sought for surgical intervention. It may be 2.5 centimeters long. The Ileal diverticula is particularly prone to pathological changes and often it is removed during surgical operation.⁽⁴⁾ Keith, et al.⁽⁵⁾ Reviewed that anomalies occur in 2 to 4% of the people & 3 to 5% more prevalent in male than female. The wall of the diverticulum contains small patches of gastric mucosa & pancreatic tissue. Sadler⁽⁶⁾ described that the Meckel's diverticulum does not usually cause any symptoms However, it contains heterotrophic pancreatic tissue or gastric mucosa, which may cause ulceration, bleeding or even perforation. Miyabara et al⁽⁷⁾ found this diverticulum in 3% of subject and average length was seen. Its mucosa is ileal type but small areas may have a gastric mucosa with oxyntic cells secreting acid. Sometime heterotrophic pancreatic tissue or other tissue occurs in the wall of the Meckels diverticulum. In a study of 1816 late fetal and neonatal cadaver a diverticulum in 61 individual (3 and 4%), gastric mucosa in 11, jejunal mucosa in 2, colonic mucosa in 2 and pancreatic tissue in one were noticed.⁽⁷⁾ Tauro et al⁽⁸⁾ mentioned that this diverticula occurs during 5th to 7th of intrauterine life. Meckel's diverticulum has a blood supply independent of that of contiguous Ileum. The diverticulum is vulnerable to infection and obstruction in the same way as appendix. In 20% of cases the mucosa contains heterotrophic epithelium namely gastric, colonic or sometime pancreatic tissue.⁽⁹⁾ If symptoms do occur they typically appear before the age of two. It is generally not indicated to remove Meckel's diverticulum found incidentally during surgery for other reasons According to the Mayo, Meckel's diverticulum is frequently suspected, often looked for and seldom found. Available literature does not speak authentically about the racial biases, no sex based difference in the incidence of Meckel's diverticulum. However some series of scientific documentation cited that the incidence of Meckel's diverticulum have been found less than half of the children, younger than 2 years. It appears to be more acknowledgeable that Meckel's diverticulum could be more an appreciable incidental finding of embryological entity.

In the present case the finding revealed different histological features of Meckel's diverticulum when compared with histological findings of the normal adjacent Ileal tissue. The mucosa of Meckel's diverticulum did not show much mucosal fold and clubbed shaped villi was shorter in length having less secreting glandular tissue in lamina propria. The muscular zone showed thin circular muscle coat as compared to the outer thick longitudinal muscle.

However, in normal Ileum the circular muscle zone was much more than the longitudinal muscle coat. In contrast the mucosa of normal Ileal tissue revealed larger mucosal fold and villi were leaf like. The mucosa appears to occupy less glandular and lymphoid tissue as compared to the histological structure of Meckel's

diverticulum which did not show any evidence of gastric mucosa, pancreatic and colonic mucosa, as often described in literature associated with diverticulum, (Fig. 2 and Fig. 3)

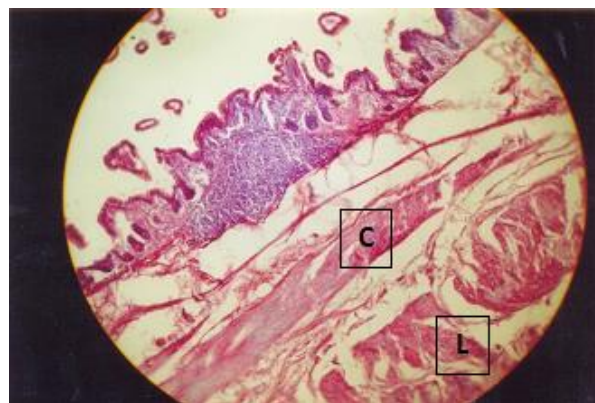


Fig. 2: Photomicrograph of the Meckel's X 400 H&E (C-circular Muscle L-Longitudinal Muscle)

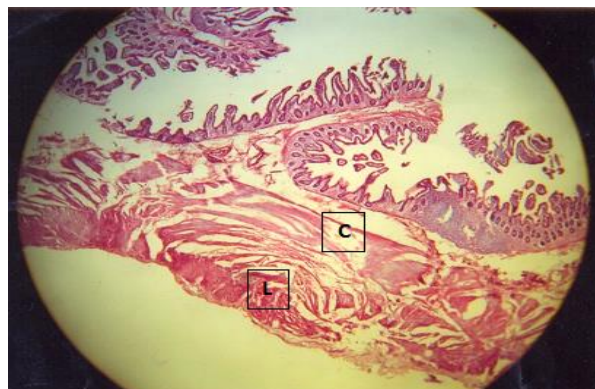


Fig. 3: Photomicrograph of Ileum adjacent to diverticulum X100 H&E (C-circular muscle L-longitudinal muscles)

The presence of gastric mucosa and heterotrophic pancreatic tissue could be a result of epithelial mesenchyme interaction. Gut endoderm and surrounding mesenchyme produce gut derived organ. Molecular biology has opened the doors to new ways for embryological understanding of normal and abnormal development. Gene expression can be regulated at several levels. Accessory pancreatic tissue may be present at anywhere from distal end of oesophagus to the tip of the primary intestinal loop. Most frequently, it lies in the mucosa of the stomach and in Meckel's diverticulum where it may show all the histological characteristic of pancreas itself. There is no description available as to how the epithelium of the diverticula changes into the gastric mucosa or heterotrophic pancreatic tissue, although it is part of the Ileum connected to the yolk sac. The available literature does not substantiate through evidence-based clarification to the specific mechanism of the existence of such glandular structure at the site of Meckel's diverticulum.

In absence of conclusive reference, the hypothesis could be evolved & possibility of further scientific probe could be closely monitored targeting the activity of gene regulation or the showing of certain factors, released from yolk sac or notochord which remain localized to the area concerned and resulted in the formation of gastric mucosa or heterotrophic pancreatic tissue formation. This could be PAX4, PDX gene (Pancreatic and duodenal homeobox). Fibroblast growth factors 2 (FGF2) and activin (a TGF β family members) produced by notochord and endothelium of the dorsal aorta repress SHH expression in gut endoderm destined to form such heterotrophic pancreatic tissue.⁽⁶⁾

However, these heterotrophic structures are not often seen in Meckel's diverticulum except in incidental cases. It appears to be the nature's selective process or nature's experimentation of sporadic differential assortment.

Conclusion

This is the history of diverse embryological and surgical entity of Meckel's diverticulum, where additional glandular and variable mucosal structures frequently suspected, often looked and seldom found.

References

1. Aarnio P, Salonen IS – Abdominal disorders arising from 71 Meckel's diverticulum. *Ann chir Gynaecol* 2000; 89:281-4.
2. Cennamo A, Tolomeo R, Sparavigna L, Izzo A Meckel's diverticulum our experience. *Minerva Chir* 2000; 55; 319-24.
3. Rogers LC "Treves" *Surgical Applied Anatomy* 4th Edn. Cassell & company Limited London 1962, pp 360-361.
4. Hollinshead H W and Rosse C. *The text book of anatomy* 4th Edn. Harper and Row, Philadelphia 1985, p 661.
5. Keith L.M & Persaud TVN *The developing Human clinically oriented embryology*. Saunders Philadelphia, Pennsylvania (2009) p. 275.
6. Sadler T.W *Langman's Medical Embryology* Eleventh edition south Asian edition page 228, Lippincott Williams & Wilkins, New Delhi, Philadelphia, Baltimore, New York, London Buenos Aires, Hong Kong Sydney, Tokyo 2009, p222.
7. Miyabara' S, Okamoto N, Akimoto, N. Satow, Y, Kidaka N Meckel's diverticulum found at autopsy a fetopathological study of sixty one cases. *Hiroshima. J. Med. Sci.* (1974) 23 (2-3), 179-190.
8. Tauro LF, Martis JJS, Shenoy H.D. Double Meckel's Diverticulum *J.I.M.A* 174-175 volume 107, Number 03 2009 pp174-175.
9. Morris PJ, Wood WC, Margolies MN *oxford text book of surgery*. vol. 2, 2nd edn. Oxford, Oxford university press 1998;1375-9.