

## Morphometric study of various foramina in the middle cranial fossa of the human skull

G. Karthikeyan<sup>1</sup>, PK Sankaran<sup>2,\*</sup>, Gunapriya Raghunath<sup>3</sup>, Yuvaraj M<sup>4</sup>, Rohini Arathala<sup>5</sup>

<sup>1</sup>Assistant Professor, <sup>2</sup>Associate Professor, <sup>3</sup>Professor, <sup>4</sup>Tutor, <sup>5</sup>PG Student, Dept. of Anatomy, Saveetha Medical College, Thandalam, Chennai

**\*Corresponding Author:**

Email: drpks@live.com

### Abstract

**Purpose:** To study the morphological details and analyse the morphometry of the various foramina in the dry human skulls of Indian population.

**Materials and Method:** Sixty four dry skulls of unknown sex and of Indian origin were used in this study which was carried out at the Department of Anatomy and forensic medicine. The parameters used were incidence, longitudinal diameter, transverse diameter, distance from midline, distance from petrous apex, and distance between right and left foramen.

**Result:** The mean sizes of the foramen ovale on the right and left sides were 7.45x1.1 mm and 7.61x1.15 mm. We found that completely ossified pterygospinous ligament passed immediately inferior to the foramen ovale and also presence of bony septa within the foramen. The foramen spinosum was present bilaterally in 90% of the skulls. The mean sizes on the right and left sides were 2.54x0.8 mm and 1.97x0.7 mm. Foramen Vesalius is one of the most inconsistent foramina of the skull. In this present study this foramen was present in only 25% of the studied skulls.

**Conclusion:** Results shows comparison of mean and standard deviation of maximum dimensions of the right and left sided foramina of the middle cranial fossa. No statistically significant differences between both sides were observed except the carotid canal. The results of this study can be helpful for anatomists and surgeons who approach the middle cranial fossa for various procedures.

**Keywords:** Foramina-Middle cranial fossa, Foramen rotundum, Foramen ovale, Foramen spinosum, Foramen of Vesalius

**Received:** 16<sup>th</sup> June, 2017

**Accepted:** 15<sup>th</sup> July, 2017

### Introduction

The Interior of skull is divided into three cranial fossae namely anterior, middle and posterior. The part in between lesser wing of sphenoid and petrous part of the temporal bone is known as middle cranial fossa. It is formed by body and greater wing of the sphenoid bone, squamous part of the temporal and part of the parietal bones. Cavernous sinus, hypophysis cerebri, temporal lobes of the cerebrum, middle meningeal artery and trigeminal ganglion is presented in the middle cranial fossa. The greater wing of sphenoid bone presents three consistent foramina namely foramen rotundum, foramen ovale and foramen spinosum. These foramina transmit vital structures in and out of middle cranial fossa. Anterior most part of the middle cranial fossa related to superior orbital fissure which communicates middle cranial fossa with the orbital cavity. Just behind and below to the superior orbital fissure, foramen rotundum (FR) is located. One end of the foramen rotundum opens into the greater wing sphenoid part of the middle cranial fossa and its other end opens into the posterior wall of the pterygopalatine fossa which transmits maxillary division of the trigeminal nerve to the pterygopalatine fossa. Posterolateral to the foramen rotundum, foramen ovale (FO) is located which transmits mandibular division of the trigeminal nerve and lesser petrosal nerve, a branch of the glossopharyngeal nerve, to the

Infratemporal region and accessory meningeal artery into the middle cranial fossa. Posterior to the foramen ovale, foramen spinosum (FS) is located which transmits middle meningeal artery, a branch of the maxillary artery. Apart from above mentioned consistent foramina, the middle cranial fossa of the skull has various foramina like Foramen of Vesalius, Canaliculus innominatus, foramen lacerum, carotid canal, optic canal and two small canaliculi named as mastoid and tympanic canaliculi.<sup>(1)</sup> Variation in the dimension, shape and number of the foramina is clinically important in view of the delicate neurovascular structures that traverse them. The present study focused on morphometric dimensions and morphological variations of various clinically important foramina like foramen ovale, spinosum, rotundum and Vesalius in the middle cranial fossa. Since these foramina act as a gateway for neurovascular structures these variations in dimension may compress them leading to consequences. So, study of base of the skull has an important role in view of its clinical significance.<sup>(2)</sup> Moreover, knowledge of the variations in the foramina would guide clinicians towards a correct interpretation of radiographs and would be of help in surgical approaches in complicated middle cranial fossa region.

**Materials and Method**

In this study, 64 dry adult skulls were used which were obtained from the Anatomy department and Forensic department of Saveetha Medical College, Thandalam, Chennai. All skulls were from native origin and damaged skull was removed from the sample. The diameter of foramen ovale in long axis (length)(antero-posterior axis) and short axis (width)(medio-lateral axis) was measured using vernier caliper on both sides. The maximum diameter of foramen spinosum was measured in medio-lateral axis and the readings are tabulated for right and left side. All readings were measured thrice and then the mean figure was recorded. These foramina were also noted for any morphological variations like shape, septations and partitions. Also the middle cranial fossa was noted for presence of an inconsistent foramen called foramen Vesalius. If present, the diameter of this foramen was measured and its variations were noted. The final result were tabulated and analyzed for mean and standard deviation using SPSS software and compared with right and left side.

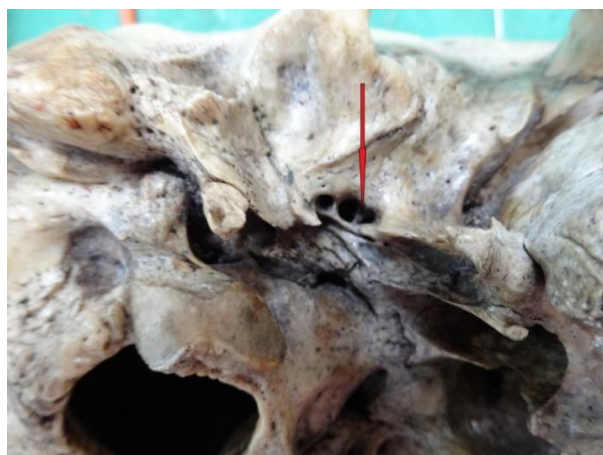
**Results**

**Foramen ovale:** The mean length of foramen ovale on right was 7.45 mm and on left was 7.61mm. The mean width on right was 3.99mm and on left was 4.6mm. The measurement of foramen ovale ranged from 3.54mm to 9.21 mm from medial to lateral and 3.33 mm to 10.12 mm antero-posteriorly (Table 1). In this present study an average distance of foramen to the midline was similar on both sides i.e. 22.02 mm on the right side, 21.88mm on the left side. In this present study foramen ovale were bilaterally present in all specimens. In all specimens the shape was oval except two specimens which were circular. Also in one specimen on right side the ovale was divided by thin bony septation in to two partitions. The septation was perpendicular to long axis and not a part of any ossified ligament (Fig. 1). In another bony skull the foramen was divided into compartment by ossified pterygospinous ligament (Fig. 2). This ligament passed inferior to left foramen ovale dividing into two equal compartments.

**Table 1: Metrical data on the foramina ovale.**

Foramen ovale	Length (mm)		width(mm)		Range (mm)	
	Right	Left	Right	Left	M-L diameter	A-P diameter
Mean diameter	7.45	7.61	3.99	4.6	3.54-9.21	3.33-10.12
Standard deviation	1.1	1.15	1.8	1.4	-	-

M-L=Medio-lateral, A-P=Antero-posterior



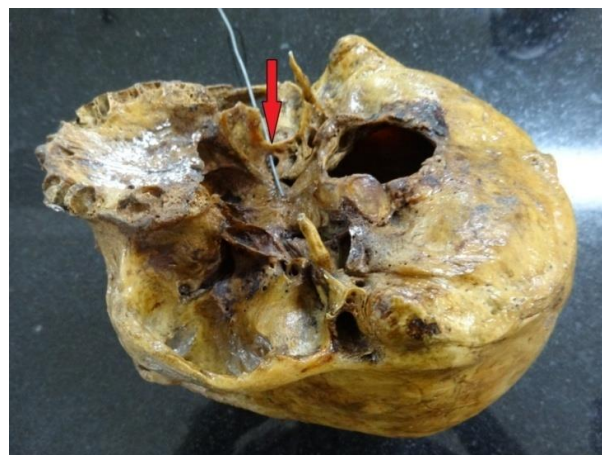**Fig. 1: The below arrow shows bony septa dividing the foramen ovale into two equal part**

**The foramen spinosum:** The mean diameter of foramen spinosum on right was 2.54mm and on left side was 1.97mm (Table 2). The foramen spinosum were present in 63skulls except one skull which showed bilateral absence of this foramen (Fig. 3) and in another skull this foramen was very small like pin head and also duplicated (Fig. 4), so the measurement was not taken in this skull.

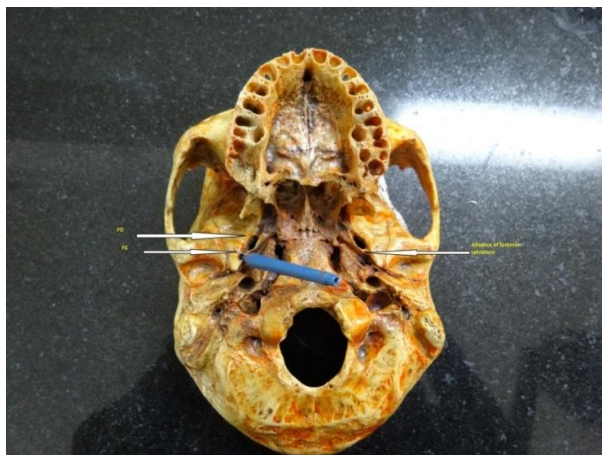
**Table 2: Mean diameter of foramen spinosum on right and left side**

Foramen spinosum	M-L axis(mm)	
	Right	Left
Mean diameter	2.54	1.97
Standard deviation	0.8	0.7

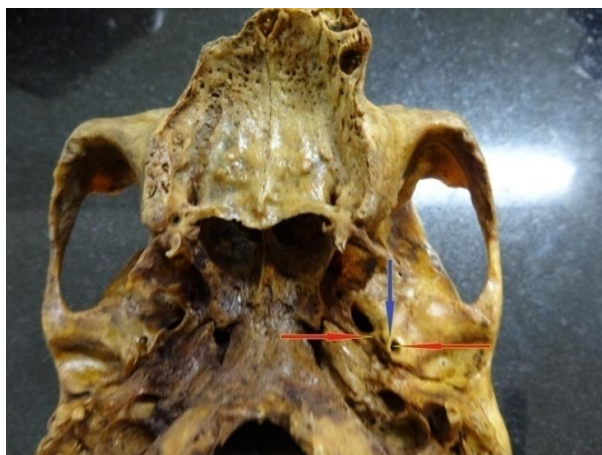M-L=Medio-lateral



**Fig. 2: The arrow points to the ossified pterygospinous ligament**



**Fig. 3:** The below right arrow indicates the absence of foramen spinosum, probe indicates presence of foramen spinosum on the right side. (FS-foramen spinosum, FO- Foramen ovale)



**Fig. 4:** Blue arrow indicates bony septum dividing the foramen spinosum, Red arrow indicates duplication of foramen spinosum

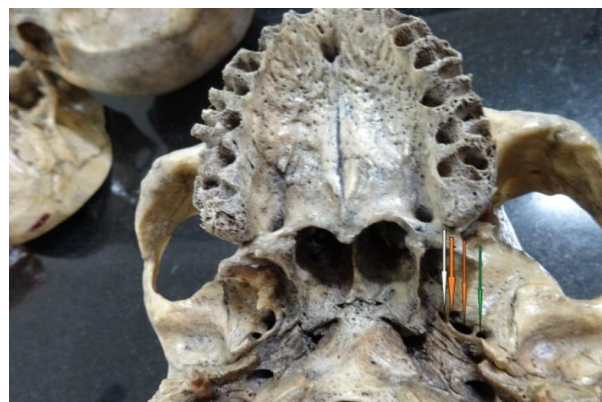**Table 3: Mean diameter and distance from midline and petrous apex to foramen rotundum**

Parameters	Right(mm)	Left(mm)
Longitudinal diameter	4.01	4.56
Transverse diameter	3.74	3.96
Distance from midline	16.67	18.53
Distance from petrous apex	19.01	17.02

M-L=Medio-lateral, A-P=Antero-posterior

**Foramen rotundum:** The mean vertical diameter of foramen rotundum was 4.01 mm and 4.56mm in right and left side respectively. The mean transverse diameter of this foramen is 3.07mm and 3.96mm. The distance of this foramen from midline and petrous apex is not statistically significant on both sides (Table 3).

**Foramen of Vesalius:** Foramen Vesalius is an inconsistent foramen which was present in 10 skulls (Fig. 5) among 64 skulls. Out of 10 skulls 7 skulls showed this foramen bilaterally and unilaterally in 3 skulls. The mean diameter of this foramen on right was 1.34mm and on left side was 1.98mm.



**Fig. 5:** White arrow indicates unilateral presence of left foramen Vesalius located medial to the duplicated foramen ovale orange arrow green arrow indicates foramen spinosum

### Discussion

**Foramen ovale:** This study observed the presence of this foramen bilaterally in all the skulls. The mean length of the foramen on right side was 7.45+1.1(with the range from 3.54-9.21mm) and left side was 7.61+1.15 (with the range from 3.33-10.12mm). Like all earlier studies, this study also showed no statistical significance ( $P>0.05$ ) in measurements on right and left sides.<sup>(3,4)</sup> Also the mean width in present study was 3.99 mm on right side and 4.6mm on left side which was similar to previous studies which showed  $3.21 \pm 0.02$  mm and  $3.29 \pm 0.85$  mm on right side and left sides respectively.<sup>(5)</sup> There are various studies (Table 4) around globe showing length of foramen ovale in different population like 7.48mm in Japanese,<sup>(4)</sup> 7.2mm in German<sup>(6)</sup> and 7.46 mm in Nepal.<sup>(3)</sup>

**Table 4: Foramen Ovale: Comparison of data from the present study with the previous studies**

Authors	Length	Width	Distance from mid sagittal line		Distance from apex of petrous	
			Right	Left	Right	Left
Lindblom1936	7	4	-	-	-	-
Lang (1983)	7.26	3.65	-	-	-	-
Ray et al	7.46	-	-	-	-	--
Landl MK,(2005)	6.6 6.77	-	-	-	-	-
Berge&Bergman (2001)	7.11	3.60	-	-	-	-
Osunwoke E.A et al(2005)	Max-9.5mm Min-5.0mm	Max-5 Min-2	-	-	-	-
Namita A. Sharma1 et al(2011)	7.05	3.99	22.13	21.71	-	-
M.S. Somesh et al(2011)	7.6	5.12	-	--	-	-
unver dogan, n.et al(2014)	Rt-7.18 Lt-7.29	7.29 4.06	22.58	22.15	9.22	9.91
Present study	Rt-7.45 Lt-7.61	3.99 4.6	<b>22.02</b>	<b>21.88</b>	<b>8.21</b>	<b>8.96</b>

There was no literature reporting complete absence of foramen ovale in middle cranial fossa. This study showed one skull on right side having a thin bony septation dividing the foramen into two compartments of approximately equal size. So this thin bony septation could interfere with transcutaneous needle placement and distort anatomic relationships during cranial approaches.<sup>(7)</sup> Another study reported presence of bony spur in this foramen indicating incomplete partitions.<sup>(3)</sup>

The foramen ovale that lays between the extracranial and intracranial junction it could be used in various diagnostic and therapeutic invasive procedures. This foramen can be used for electroencephalographic analysis of seizures during selective amygdalohippocampectomy, microvascular decompression hypercutaneous trigeminal rhizotomy for trigeminal neuralgia and percutaneous biopsy of cavernous sinus tumors.<sup>(8)</sup>

The present study showed completely ossified pterygospinous ligament in the foramen, through compressing mandibular Increase in the width and flattening of the lateral pterygoid plate may leave little space, causing difficulty while performing surgery on the pterygoid region. Anomalies involving the pterygospinous ligament may not only be of academic interest but also be beneficial for maxillofacial and dental surgeons and anesthetists.<sup>(9)</sup>

**The foramen spinosum:** In the present study foramen spinosum was absent in 2% of skull. Various studies had described unilateral absence and its importance like 0.4–1% of cases<sup>(10,11)</sup> few studies had mentioned rarely absence of foramen spinosum on both sides.<sup>(12)</sup> These variations in this foramen is clinically important because middle meningeal artery enters cranial cavity and supply duramater.<sup>(13)</sup> In absence of this foramen the middle meningeal artery may arise from the ophthalmic

artery, lacrimal artery, or from the petrous, cavernous part of the internal carotid artery.<sup>(12,13)</sup> There is more explanation for absence of foramen spinosum if the middle meningeal branch arises from internal carotid artery or from the branch of internal carotid artery.<sup>(14)</sup> We observed duplicated foramen spinosum in 2.5% of cases. Duplication of this foramen can be explained due to early division of the middle meningeal artery into posterior and anterior divisions.<sup>(14,15,16)</sup> The external diameters of Foramen Spinosum varied and did not usually exceed 3 mm, if the diameter exceeds 5 mm the subject should be immediately evaluated for any vascular abnormality.<sup>(3)</sup>

**Foramen rotundum:** Various studies had shown the average diameter of foramen rotundum as 3.11 in cadavers and 3.44 in dried skulls.<sup>(17)</sup> Comparing with this study the diameter was 3.07 mm and 3.96 mm on right and left side which was similar to previous studies and there was no statistical difference in both sides in distance from midline and petrous apex. The most common variation of foramen rotundum is “lateral rotundal canal” which measures an average diameter of about 1 to 3 mm and in the floor. This foramen either opens in to the infratemporal fossa or in to the space between the pterygoid plates.<sup>(18)</sup>

**Foramen of Vesalius:** The foramen of Vesalius or venosum is a small inconsistent foramen in the greater wing of the sphenoid bone antero-medial to foramen ovale with an exclusive feature in the human skull and is not present in any other primate.<sup>(19)</sup> This study found presence of this inconsistent foramen in 10 skulls that transmit emissary vein and a nerve. In the absence of this foramen, the respective emissary vein leaves the skull through the foramen ovale<sup>(20)</sup> and if present it may transmit a small nerve, the nervulus sphenoidalis lateralis through this foramen into the cavernous

sinus.<sup>(6,3)</sup> The external diameter was found to be 1.34 mm on right side and 1.98 mm on left side which was compared and similar with the values recorded in earlier studies.<sup>(6)</sup> If the diameter is less than 0.5 mm it is safe for percutaneous rhizotomy and if the diameter is greater than 0.5 mm it may damage structures on the adjacent foramen ovale.

If this foramen present, percutaneous trigeminal rhizotomy through needle can be done but it has an adverse effect in puncture of cavernous sinus leading to temporal lobe hematoma.<sup>(3)</sup> Therefore, the knowledge about the morphology and incidence of Foramen Vesalius is not only important from the anatomical point of view but is also essential for the operating surgeon.

### Conclusion

This study concludes the morphometrical data of various foramina in the middle cranial fossa and its variations so that it is useful for the operating surgeons in that region. This study concludes the diameters of foramen ovale and spinosum does not show any statistical significant difference in right and left side. Also the inconsistent foramen Vesalius is present in 10 skulls out of 62 skulls indicating its anatomical significance for surgery during rhizotomy.

### References

1. Standring. S. M Gray's Anatomy. 39th ed. New York, Elsevier Churchill Livingstone, 2005,462-6.
2. Sharma. N. Garud, R. S. Morphometric evaluation and a report on the aberrations of the foramina in the intermediate region of the human cranial base: A study of an Indian population. *Eur. J. Anat*,2011,15(3):140-9.
3. Ray, B.; Gupta, N. & Ghose, S. Anatomic variations of foramen ovale. *Kathmandu Univ. Med. J. (KUMJ)*3(1):2005, 64-8.
4. Yanagi. S. Developmental studies on the foramen rotundum, foramen ovale and foramen spinosum of the human sphenoid bone. *The Hokkaido Journal of Medical Science* :1987,62(3): 485-496
5. Berry AC, Berry RJ. Epigenetic variation in human cranium. *J Anat*. 1967,101: 361-379.
6. Lang. J, Maier. R, Schafhauser. O. Postnatal enlargement of the foramina rotundum, ovale, spinosum and their topographical changes. *Anat. Anz*:1984,56(5):351-87.
7. Tubbs, R. Shane M.S. Ossification of ligaments near the foramen ovale: An anatomic study with potential clinical significance regarding transcutaneous approaches to the skull base neurosurgery. 2009,65:60-64.
8. M.S. Somesh, H.B. Sridevi et al A Morphometric Study of Foramen Ovale. *JTN*. DOI: 10.5137/1019-5149.JTN.3927-10.
9. Kavitha Kamath. B, Vasantha K. Anatomical Study of Pterygospinous and Pterygoalar Bar in Human Skulls with their Phylogeny and Clinical Significance. *J Clin Diagn Res*: 2014,8(9):10-13.
10. Greig DM. Congenital anomalies of the foramen spinosum. *Edinb Med J*: 1929,36:363-371.
11. McLennan JE, Rosenbaum AE, Haughton VM. Internal carotid origins of the middle meningeal artery. *Neuroradiology*: 1974,7:265-275.
12. Royle G, Motson R. Anomalous origin of the middle meningeal artery. *J Neurol Neurosurg Psychiatry*:1973;36:874-876
13. Manjunath KY. Anomalous origin of the middle meningeal artery—a review. *J Anat Soc India*: 2001,50:179-183.
14. Lindblom. K. A roentgenographic study of the vascular channels of the skull. *Acta Radiol (Suppl)*: 1936,30.
15. Reymond, J.; Charuta, A. & Wysocki, J. The morphology and morphometry of the foramina of the greater wing of the human sphenoid bone. *Folia Morphol. (Warsz)*: 2005,64(3):188-93.
16. Sondheimer. FK. Basal foramina and canals. In: Newton TH, PottsDG, eds. *Radiology of the skull and brain: the skull*: 1971,1, 287-347.
17. Kwatha. L, Namonta. K, Rungruang. T, Chaisuksunt. V, Apinhasmit. W, Chompoopong. S Anatomic and morphometric consideration for external landmarks of foramen spinosum in thai dry skulls. *Siriraj Med. J*: 2012,64( 1):26-29.
18. Ginsberg LE, Pruett SW, Chen MY, Elster AD (1994) Skull-base foramina of the middle cranial fossa: reassessment of normal variation with high-resolution CT. *Am J Neuroradiol*: 1994, 15:283-2917
19. Wood-Jones F. The non-metrical morphological characters of the skull as criteria for racial diagnosis. Part I. General discussion of the morphological characters employed in racial diagnosis. *J Anat*:65: 179-195.
20. Henderson, W. R. A note on the relationship of the human maxillary nerve to the cavernous sinus and to an emissary sinus passing through the foramen ovale. *J. Anat*:1966, 100:905-8.