

Congenital renal abnormalities in fetuses: a study in a teaching institute

Pabbati Raji Reddy

Associate Professor, RVM Institute of Medical Sciences & Research Center, Telangana, Hyderabad

Email: pabbatirajireddy@gmail.com

Abstract

Introduction: The term renal malformations include a number of development aberrations which include structural and developmental anomalies. Renal agenesis, Renal dysplasia, hypoplasia and polycystic kidney disease are some of the renal anomalies.

Materials and Method: The approximate age, sex and crown rump length were recorded for the 50 fetuses included in the study. The embalmed fetuses were dissected as per protocol and anomalies were recorded. The size, shape and the kidneys, the arrangement of the attached structures such as the hilum, ureter, bladder abdominal aorta and the inferior vena cava were noted and recorded.

Results: out of the 50 fetuses 29 were males and 21 were females. 2 of the fetuses had abnormal kidneys, out of which, one was male with Right Renal agenesis and the other was female with congenital polycystic kidney. The surface of both the kidneys of the male fetus showed cysts which looked like gas bubbles, thereby showing the presence of congenital polycystic kidney. There was agenesis observed in the right kidney and ureter in the female fetus while the left kidney was normal.

Conclusion: Although the renal anomalies are relatively uncommon, it is better for early detection so that corrective measures can be taken either pre or postnatally.

Keywords: Renal abnormality, Renal agenesis, Congenital polycystic renal disease, Fetus

Received: 31st October, 2016

Accepted: 25th July, 2017

Introduction

Congenital abnormalities of the urinary tract are most commonly identified sonographically. Their incidence is said to occur in every 1-4 pregnancies,⁽¹⁾ with a representation of 15-20% of all prenatally diagnosed congenital anomalies. Obstructive uropathy accounts for majority of the cases.⁽²⁾ With the advent of ultra sound, these anomalies are being detected very early in life and many of the new born are being treated within the first five years of life, although, there are quite a few fatalities in utero also.⁽³⁾

The urinary tract development take place in the third week of intrauterine life form the intermediate mesoderm and form the urogenital sinus (bladder and the urethra), while the intermediate mesoderm form the kidneys and the ureters. During this development, the renal system pass through the pro and mesonephros and the metanephros stage before forming the definitive kidney.⁽⁴⁾ From about 9-12 weeks of pregnancy, the fetal kidneys and adrenal glands are well developed to be visualized on either sides of the lumbar spine.

The term renal malformations include a number of development aberrations which include structural and developmental anomalies. Renal agenesis is one such example where the kidney is totally absent.^(5,6) Renal dysplasia occurs when there are undifferentiated and metaplastic cells within the organs. These many be tiny as in the case of renal aplasia or can distend the abdomen as in multicystic dysplastic kidney. A hypoplastic kidney is small with very few nephrons than normal, which may be greatly enlarged in oligomeganephronia.⁽⁷⁾

Some other type of anomalies is the polycystic kidney disease, which include autosomal recessive polycystic kidneys and the disorder resulting from genetic mutations.⁽⁸⁻¹¹⁾

In an analysis by the Northern Congenital Abnormality Survey (NorCAS), 19.6% of the pregnancies, in which a congenital anomaly was identified failed to produce a living child. Therefore, this study was conducted to identify the renal anomalies present in the fetuses which do not produce a living child.

Materials and Method

This study was conducted by the Department of Anatomy at Mediciti institute of medical sciences during the period of two years. A total of 50 dead new born were dissected and thoroughly verified. The information was collected from the autopsies conducted by the Forensic department of our hospital.

The still born were brought from the maternity hospitals after the proper paperwork, and were kept in 10% formalin solution. The approximate age, sex and crown rump length were recorded for each foetus. All the foetues were properly numbered and were injecting with preservative liquids by body injectors and storing in the tank solution. They were dissected after 3 or 4 days and if no anomaly was found, they were discarded.

The dissection was performed with a midline incision from supra-sternal notch to symphysis pubis and two transverse incision form the umbilicus laterally as far as possible to expose the abdominal and the thoracic cavities completely. The position of the

suprarenal gland and the upper poles of the kidneys were noted and recorded. The size, shape and the kidneys were also recorded. The arrangement of the attached structures such as the hilum, ureter, bladder abdominal aorta and the inferior vena cava were noted and recorded.

Results

Out of the 50 fetuses 29 were males and 21 were females. 2 of the fetuses had abnormal kidneys, out of which, one was male with Right Renal agenesis and the other was female with congenital polycystic kidney. The male was of 28 gestation weeks with a crown rump length of 27cms and head circumference of 15 cms. All the external features were normal. Internally, the gastrointestinal area i.e. the stomach to the sigmoid colon was found to be normal and removed. The right and left kidneys were slightly larger than a normal sized kidney of the same gestational age and measured 6.5 x 3 x 1cm. The surface of both the kidneys showed cysts which looked like gas bubbles, thereby showing the presence of congenital polycystic kidney (Fig. 1).

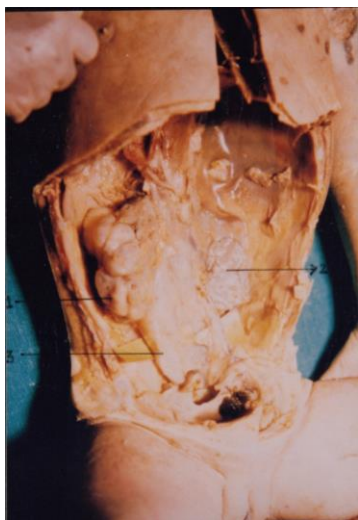


Fig. 1: Congenital polycystic kidney

The rest of the features such as position of the supra renals, structures at hilum, renal vein, renal artery, and the ureter were normal. The right ureter was dilated but normal in size. There was no stenosis, no tortuosity and the renal pelvis was uniformly dilated. Similar was the case with the left ureter.

In the second fetus which was a female, the gestational age was 26 weeks with the crown rump being 25 cms. The rest of the external features were normal.

There was agenesis observed in the right kidney and ureter. The right supra renal gland was very small in size, though the left kidney, ureter and the supra renal gland were normal (Fig. 2).

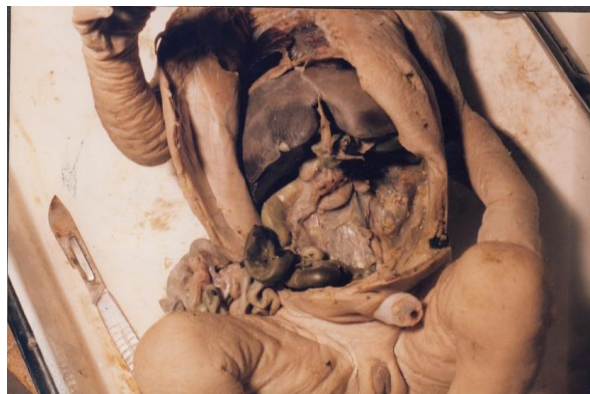

Fig. 2: Right Renal agenesis in male fetus

Discussion

Though very few studies have been conducted on the survey of congenital malformations in the nonliving fetuses, there are a few in the living fetuses. We have attempted to compare the cases from both live and non-living fetus studies.

In the present study, congenital anomalies of the kidneys was found in 4% of the fetuses. An abnormality in the development of kidney and ureter was found in 9.6% by Dees et al. An incidence of renal abnormalities was found in 1 in 27 individuals (3.7%) by Smith et al while Culp et al found in 3.1% of the cases. In a more recent study by Scott, 57.7% of the deaths of the fetuses was solely due to renal anomalies.

With more recent studies it was unable to compare due to procedural reasons. For instance, some studies do not register cases delivered before 20 weeks of gestation and include only renal agenesis and cystic diseases for urinary tract anomalies.⁽¹⁶⁾ In another instance, 45% of the pregnancies were terminated but few major anomalies went undetected.⁽¹⁷⁾

Of all the anomalies, unilateral agenesis occurs more commonly, though bilateral agenesis has a profound effect on the patient. Very few cases have been cited for bilateral agenesis with most of them being cited by Potter in 1965.

We have not come across a bilateral agenesis but did come across a unilateral agenesis in one female fetus. In a study by Davidson et al, a 0.28% incidence was observed of bilateral anomaly with a significantly higher rate in males rather than females.

Renal agenesis is said to occur when there is an absence of the metanephrogenic blastema, or absence of the ureteric bud. This disorder may also be associated with genital tract abnormality, skeletal abnormality, anorectal malformation and cryptorchidism¹⁸. There was no adrenal gland in the agenesis patient in our study. It is estimated that in 8-17% of the cases, there will be no adrenal gland for such cases.⁽¹⁹⁾

We had encountered a case of congenital polycystic kidney in one male fetus. In a study by Scott, 78 out of 323 patients with renal anomaly had polycystic renal disease.⁽¹⁵⁾ Autosomal recessive

polycystic kidney disease has a spectrum of severity, with most of the severe forms appearing earliest in life and being bilateral. Usually those diagnosed early in life are usually recessive type.⁽²⁰⁾

It is estimated that the incidence of autosomal recessive polycystic kidney disease is 1 in 20,000 live births.⁽²¹⁾ It is more frequently said to occur due a mutation in the PKHD-1 gene, but additional genes are also known to play a role. A heterozygous carrier state is reported in 1 in 70.⁽²²⁾ It is characterized by the dilatation of tubules especially in the medulla, with the outer cortex being spared.⁽⁴⁾ Severely affected fetuses if born are born with oligohydramnios, Potter's face. Many of them will develop respiratory insufficiently. In survivors, approximately 40% have severe hepatic and renal disease.⁽⁴⁾

This disease basically results in bilateral symmetric microcystic disease occurring in the distal convoluted tubules and collecting ducts,⁽¹⁸⁾ maybe associated with Caroli's disease⁽²³⁾ or congenital hepatic fibrosis.^(24,25) Secondary to the liver fibrosis, they may develop portal hypertension, esophageal varices, hemorrhoids, upper gastrointestinal bleeding, splenomegaly and hypersplenism.

The limitation in this study was the less number of specimens for study.

Conclusion

The number of dead fetuses due to renal anomalies have not improved in the past few years probably due to early detection and medical termination of pregnancy rather than post natal deaths. Many of these anomalies are hereditary and due to the advances in prenatal diagnosis, advent of fetal surgeries and kidney transplants, there has been an improvement in the prognosis although still the numbers are not statistically significant. Proper diagnosis of the genetic abnormalities are possible in today field of medicine which can improve and prevent further fetal anomalies.

References

- Grandjean H, Larroque D, Levi S. The performance of routine ultrasonographic screening of pregnancies in the Eurofetus Study. *Am J Obstet Gynecol.* 1999;181:446-454.
- Elder JS. Antenatal hydronephrosis. Fetal and neonatal management. *Pediatr Clin North Am.* 1997;44 n.
- Bhide A, Sairam S, Farrugia MK, et al. The sensitivity of antenatal ultrasound for predicting renal tract surgery in early childhood. *Ultrasound Obstet Gynecol.* 2005;25:489-492.
- A. Hindryckx, L. De Catte. Prenatal diagnosis of congenital renal and urinary tract malformations. *Facts Views Vis Obgyn.* 2011; 3(3): 165-174.
- Potter EL. *Normal and abnormal development of the kidney.* 1972 Year Book Medical Publishers, Chicago).
- Bernstein J, Risdon RA, Gilbert-Barness E Renal system. In *Potter's pathology of the fetus and infant.* ed Gilbert-Barness E 1996 (Mosby, St Louis), pp 863-922.
- Woolf AS. Multiple causes of human kidney malformations. *Arch Dis Child* 1997;77:471-474.
- Zerres K, Mucher G, Bachner L, et al. Mapping of the gene for autosomal recessive polycystic kidney disease (ARPKD) to chromosome 6p21-cen. 1994 *Nature Genet* 7:429-432.
- Brook-Carter PT, Peral B, et al. Deletion of the TSC2 and PKD1 genes associated with severe infantile polycystic kidney disease—a contiguous gene syndrome. 1994. *Nature Genet* 8:328-332.
- Feather S, Woolf AS, Malcolm S, Donnai D, Winter R. The oral-facial-digital syndrome type 1 (OFD1), a cause of polycystic kidney disease and associated malformations, maps to Xp22.2-22.3. 1997. *Hum Molec Genet* 7:1163-1167.
- Woolf AS. The biology of kidney malformations. In *Embryos, genes and birth defects.* ed Thorogood P (Wiley, Chichester), 1997. pp 303-327.
- Dees JE. Importance of diagnosing congenital anomalies in the upper urinary tract. 1941. *J Urol*;41:659.
- Smith EC, Orkin LA. A clinical and statistical study of the kidney and ureter. 1945. *J Urol*;53:11.
- Culp OS, Hiebert PE. Clinical significance of congenital anomalies of kidney and ureter. 1944; *J Urol*; 52:397.
- Scott JES. Fetal, perinatal, and infant death with congenital renal anomaly. *Arch Dis Child* 2002;87:114-117.
- EUROCAT. Report 7. Brussels: Scientific Institute of Public Health, 1997.
- Isaksen CV, Eik-Nes SH, Blaas HG, et al. Fetuses and infants with congenital urinary system anomalies: correlation between prenatal ultrasound and postmortem findings. *Ultrasound Obstet Gynecol* 2000;3:177-85.
- Patel NA, Suthar PP. Ultrasound appearance of congenital renal disease: Pictorial review. *Egypt J Radiol Nucl Med.* 2014;45(4):1255-1264.
- Singh I, Pal GP. Human embryology 8th ed. In: Chapter 16 – Urogenital system, 2007:237-67.
- Cole BR, Conley SB, Stapleton FB. Polycystic kidney disease in the first year of life. 1987., *J Paed*;111:693-699.
- Wilson PD. Polycystic kidney disease. *N Eng J Med.* 2004;350:151-164.
- Sweeney WE, Avner ED. Pathophysiology of childhood polycystic kidney diseases: new insights into disease-specific therapy. *Pediatr Res* 2014;75:148-157.
- V.T. Ninan, M.R. Nampoory, K.V. Johny, et al. Caroli's disease of the liver in a renal transplant recipient. *Nephrol Dial Transpl*, 17 (6) (2002), pp. 1113-1115.
- W.H. Mcalister, M.J. Siegel. Pediatric radiology case of the day. Congenital hepatic fibrosis with saccular dilatation of the intrahepatic bile ducts and infantile polycystic kidneys. *AJR Am J Roentgenol*, 152 (6) (1989), pp. 1329-1330.
- G. Brancatelli, M.P. Federle, V. Vilgrain, et al. Fibropolycystic liver disease: CT and MR imaging findings. *Radiographics*, 25 (3) (2005), pp. 659-670.