

Evaluation of proximal femoral morphometry in plain CT Scans in South-Indian Population

Ganesh T. Waghmode^{1,*}, Uma T. Waghmode², Pavan B. Shinde³

¹Associate Professor, Dept. of Anatomy, Navodaya Medical College, Raichur, ²Medical Officer, Rural Hospital, Mohol, ³Medical Officer, Primary Health Centre, Sangeli

***Corresponding Author:**

Email: gw1726@gmail.com

Abstract

Introduction: Morphological parameters of proximal femur are required in orthopaedic management of disorders of hip joint, to radiologists in diagnosis of disorder of hip joint and during production of implants. Implants are required for total hip replacement need appropriate implant size to avoid complications.

Context and purpose of study: Morphological variations are present due to genetics, lifestyle & physique. Western hip implants do not match with Indian hip joints. Present study will help in preparing hip implants for south Indian population. CT scans of hip joints of 32 male and 28 female between age group 60 to 70 years were studied in period of six months. Diameter of head of femur, length of neck of femur, width of neck of femur and neck shaft angle of femur were found out from 120 hip joint CT scan images from 32 males and 28 females between age groups 60 years to 70 years. Mean, range, standard deviation calculated. The probability value was determined by chi-Square test.

Result: Mean femoral head diameter in male was 41.2 +/- 4.8 mm and in female it was 35.7 +/- 3.5mm.

Mean femoral neck length in male was 89.3 +/- 4.3 mm and in female it was 78.7 +/- 3.5mm.

Mean femoral neck width in male was 27.8 +/- 4.6 mm and in female it was 24.0 +/- 3.7mm.

Mean femoral neck shaft angle in male was 130.5 +/- 4.5 mm and in female it was 127.4 +/- 3.8 mm.

Conclusion: Morphometric difference is seen in present study and previous studies due to different lifestyle and physique. present study will be useful for radiologists in diagnosing disorders of hip joint, for orthopaedic surgeons in management of disorders of hip joint and in designing implants of hip joint for south Indian populations.

Keywords: Hip joint, Implants, Proximal femur

Received: 28th May, 2017

Accepted: 4th July, 2017

Introduction

Morphometric study of proximal femur is important for radiologists, orthopaedic surgeons, implant designers, anatomists and anthropologists.

Variation is present in race, climate, and geographical areas. Indian dimensions of proximal are lesser than western standards.⁽¹⁾

There is strong correlation between the occurrence of thigh pain and inadequate fit and fixation of the implant.⁽²⁾

Mismatch due to large size of implant causes aseptic loosening, anterior thigh pain, operative complications and shorter life span of implants.⁽³⁾

Present study was done on CT scan images of hip joint of south Indian population. Present study will help radiologists, orthopaedic surgeons, implant designers, anatomists and anthropologists.

Materials and Method

CT scan images of hip joints of 32 normal males and 28 normal females between age groups 60 years to 70 years were obtained from department of radiology Navodaya hospital Raichur in period of six months. Diameter of head of femur, length of neck of femur, width of neck of femur and neck shaft angle of femur were found out from 120 hip joint CT scan images from 32 males and 28 females between age groups 60 years to 70 years. All parameters were statistically analyzed. Student's test was used to obtain probability value and to find out statistical significance.

Result

Values of mean, range, standard deviation of CT scan images of hip joints of diameter of head of femur (DHF), length of neck of femur (LNF), width of neck of femur (WNF) and neck shaft angle of femur (NSA) are shown in Table.

Table 1: Showing parameters of CT scan images of proximal femur

Sex		Male				Female			
Parameters		NSA	DHF	LNF	WNF	NSA	DHF	LNF	WNF
Mean	Rt	130.3+/- 4.5	41.1 +/- 4.6	89.3+/- 4.1	27.6+/- 4.5	127.4+/- 3.2	35.7 +/- 3.5	78.6+/- 3.2	24.1+/- 3.6
	Lt	130.2+/- 4.3	41.0 +/- 4.5	89.2+/- 4.2	27.4+/- 4.3	127.3+/- 3.6	35.6 +/- 3.4	78.5+/- 3.3	24.0+/- 3.5
Range	Rt	125.8 to 134.8	36.5 to 45.7	85.2 to 93.4	23.1 to 32.1	123.6 to 131.20	32.3 to 39.2	75.4 to 81.8	20.5 to 27.7
	Lt	125.9 to 134.5	36.5 to 45.5	85.0 to 93.4	23.1 to 31.7	123.7 to 130.9	32.2 to 39	75.2 to 81.8	20.5 to 27.5
Standard deviation	Rt	+/- 4.5	+/-4.6	+/-4.1	+/-4.5	+/- 3.2	+/-3.4	+/-3.2	+/-3.6
	Lt	+/- 4.3	+/-4.5	+/-4.2	+/-4.3	+/- 3.6	+/-3.4	+/-3.3	+/-3.5
P Value for femoral sides		<0.4345 STN	<0.6923 STN	<0.9321 STN	<0.9013 STN	<0.4521 STN	<0.7012 STN	<0.9076 STN	<0.8934 STN
P value between sexes		<0.0001 STS	<0.0001 STS	<0.0001 STS	<0.0001 STS				

(NSA) neck shaft angle in degrees, (DHF) diameter of head of femur in millimeter, (LNF) Length of neck of femur in millimeter, (WNF) width of neck of femur in millimeter (STN) statistically not significant and (STS) statistically significant.

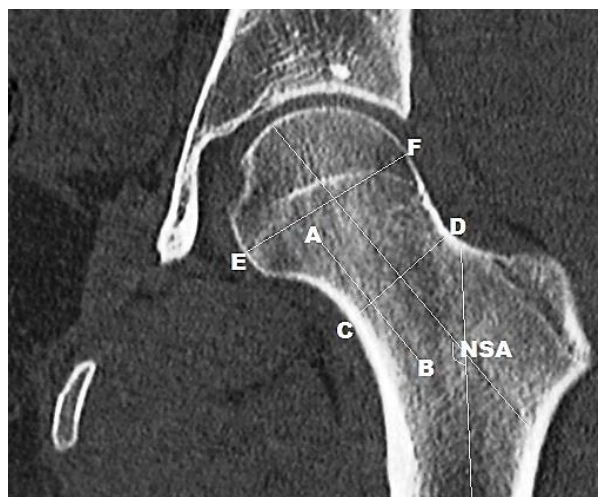


Fig. 1: (NSA) neck shaft angle, Diameter of head of femur (EF), Length of neck of femur (AB) and Width of neck of femur (CD)

Discussion

Morphometric study of proximal is most important as data of proximal femur is required to orthopaedic surgeon, radiologists and for preparation of implants. There are racial, regional and age variations in the stature of human beings so implant should be designed according to specific population. The age group studied in our study was 60 years to 70 years in this age group disorder of hip joint like osteoarthritis, fracture and dislocation is not uncommon, while managing these disorders there is need of morphometric data of proximal femur.

Study by Moore et al was based on Manual Morphometry according to their study range of neck

shaft angle of femur was 115° to 140° they have not mentioned about diameter of head of femur, length of neck of femur and width of neck of femur.⁽⁴⁾

Gujar et al mentioned only mean neck shaft angle of femur on right side was 136.6° and on left side was 136°, their study was based on manual methods and they have not mentioned about diameter of head of femur, length of neck of femur width neck of femur.⁽⁵⁾

Study by Tamires M M et al based on digital morphometry according to their study diameter of head of femur was 3.09 +/- 0.41 cm, length of neck of femur was 1.42 +/- 0.33 cm and width of neck of femur was 2.26 +/- 0.23 cm.⁽⁶⁾ They have not mentioned regarding values of parameters of proximal femur in male and female and of right side and left side of femur but in present study we have mentioned variations in proximal femur of male and female as well as variation of proximal femur of right side and left side.

Present study and study by Baharuddin M Y et al⁷ based on digital morphometry of CT scan images of proximal femur of male and female. They have compared CT scan images of proximal femur of Malaya male & female at the Age group of 25+/5.18 years. In present study age group studied was 60 to 70 years which was most important as disorders of hip joint are very less at age 25+/5.18 years but in old age at 60 to 70 years disorders of hip joint are more.

In study by Baharuddin M Y et al mean neck shaft angle of femur in male was 132.33° +/- 3.44° and mean neck shaft angle of femur in female was 129.87° +/- 3.95°. In present study mean neck shaft angle of femur in male was 130.5° +/- 4.5° and mean neck shaft angle of femur in female was 127.4° +/- 3.8°.

In present study mean diameter of head of femur in male was 41.2 +/- 4.8mm and mean diameter of head of femur in female was 35.7 +/- 3.5mm. In study by Baharuddin M Y et al mean diameter of head of femur in male was 43.62 +/-3.03mm and mean diameter of head of femur in female was 38.85 +/- 2.17 mm.

In study by Baharuddin M Y et al mean length of neck of femur in male was 91.08 +/- 5.65 mm and mean length of neck of femur in female was 81.78 +/- 4.33 mm. In present study mean length of neck of femur in male was 89.3 +/- 4.3 mm and mean length of neck of femur in female was 78.7 +/- 3.5 mm.

In present study mean of width of neck of femur in male was 27.8 +/- 4.6 mm and mean width of neck of femur in female was 24.0 +/- 3.7mm. In study by Baharuddin M Y et al mean width of neck of femur in male was 28.88 +/- 3.38 mm and mean width of neck of femur in female was 25.95 +/- 4.31mm.

Conclusion

Hip joint implants are required most commonly in old age as fracture neck of femur is common in old age, non-union of fracture also common in old age. Total hip joint replacement with implant is required in osteoarthritis which is most common in old age. Western hip joint implants does not match with Indian hip joint morphometry. A mismatched implant leads to unavoidable complications. Our study will provide morphometric data of proximal femur of male and female of south India for production of hip joint implants for south Indian population. Present study will help to south Indian orthopaedic surgeons

References

1. D. Ravichandran, N. Muthukumaravel, R. Jaikumar, Hirak Das, Melani Rajendran, Proximal femoral geometry in Indians and its clinical applications J. Anat. Soc. India 60(1) 6-12 (2011).
2. Reddy VS, Moorthy GV, Reddy SG. Do we need a special design of femoral component of total hip prosthesis in our patients? Indian J Orthop 1999;33:282-4.
3. Mishra AK, Chalise P, Singh RP, Shah RK. The proximal femur a second look at rational of implant design. Nepal Med Coll J 2009;11:278-80.
4. Moore KL, Dalley AF, Agur AMR Clinically Oriented Anatomy. USA Lippincott Williams & Wilkins; 2013.
5. Gujar S, Vikani S, Parmar J, Bondre KV. A correlation between femoral neck shaft angle to femoral neck length. Int J Biomed & Adv Res 2013; 4(5): 295-298.
6. Tamires M M, Taciano D S R, Belisa Duarte R O, Yuri M L A, Vitor C. Proximal Femoral epiphysis: Manual morphometry versus digital morphometry. International journal of morphometry 2015; Vol 33(3):1114-1119.
7. Baharuddin MY, Kadir MRA, Zulkifly AH, Saat A, Aziz AA, Lee MM. Morphology study of the proximal femur in Malay population. International Journal of Morphology 2011. 29(4):1321-1325.