

## Atherosclerosis: Its affinity for different coronary arteries and their sites

Abdur Rafe Abdul Waheed<sup>1,\*</sup>, SB Sukre<sup>2</sup>

<sup>1</sup>Assistant Professor, <sup>2</sup>Professor & HOD, Dept. of Anatomy, Govt. Medical College, Aurangabad, Maharashtra

**\*Corresponding Author:**

Email: abdurrafe@ymail.com

### Abstract

Atherosclerosis of coronary arteries is a common phenomenon seen to be prevalent worldwide. The advent of coronary arteriography has made it possible, in vivo, to indicate the localization, extent and severity of disease. The left anterior descending artery (LAD) is said to be the most commonly involved vessel in coronary atherosclerosis. In the present study, angiographic evaluation of the coronary arteries was done to find out the artery most commonly involved in atherosclerosis and also the most common site of the artery showing occlusion. Out of 350 cases studied, 213 showed occlusion. LAD was the most commonly involved artery to show occlusion [162 cases, 76%] followed by right coronary artery (RCA) [92 cases, 43%]. Irrespective of the vessels involved, the proximal segment of the arteries was the site where disease tend to cluster.

**Keywords:** Atherosclerosis, Coronary, Arteriography, LAD, RCA.

**Received:** 4<sup>th</sup> August, 2017

**Accepted:** 10<sup>th</sup> October, 2017

### Introduction

Blood supply of heart is through the right and left coronary arteries arising from the ascending aorta in its anterior and left posterior sinuses. The two arteries, as indicated by their name, form an oblique inverted crown, in which an anastomotic circle in the atrioventricular groove is connected by marginal and interventricular (descending) loops intersecting at the cardiac apex.<sup>(1)</sup> Atherosclerosis is a common phenomenon, which is seen with various prevalences in different races. According to its definition, it is a disease of elastic vessels (aorta, carotid, iliac, coronary, etc.). Atherosclerosis of coronary arteries and myocardial infarction are the most common fatal cardiac diseases found in autopsies.<sup>(2)</sup> More than 90% of patients with IHD have atherosclerosis of one or more of the coronary arteries. Clinically significant stenosing plaques may be located anywhere within the different coronary vessels but tend to predominate within the first several centimeters of the left anterior descending (LAD) and left circumflex (LCX) arteries, and along the entire length of the right coronary artery (RCA).<sup>(3)</sup> A stenotic lesion located at a more proximal level of the coronary arterial system reduces blood flow in a larger area of myocardium, resulting in a more pronounced ischemic response to exercise than a similar lesion located more distally.<sup>(4)</sup> Careful, important, and informing studies on the anatomy of coronary arteries in both normal and pathologic human hearts have been pursued for many years. Modern myocardial revascularization procedures require complete diagnosis which should indicate the localization, extent and severity of the disease, the presence and significance of the collateral circulation and the status of the left ventricular myocardium. Coronary arteriography in conjunction with hemodynamic and contrast studies of the left ventricle

fulfill these requirements and can guide us to the appropriate selection of patients for coronary surgery.<sup>(5)</sup>

The present study was undertaken to know angiographically the predilection of atherosclerosis for different coronary vessels and also the sites within these vessels most frequently involved by in disease process.

### Materials and Method

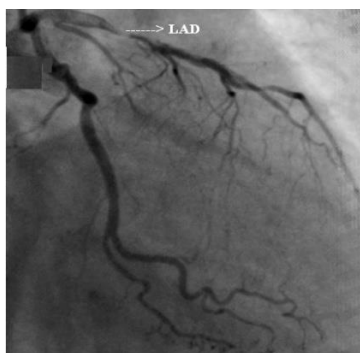
The study was carried out in the Department of Anatomy, Government Medical College, Aurangabad. A consecutive series of 350 adult patients having mean age range between 40-60 years referred to the Cardiovascular and Thoracic Surgery Centre, Aurangabad for coronary angiography was included. Patients with diagnosed anomalous coronary arteries were excluded from the study. Approval from the ethical committee of Government Medical College and Hospital, Aurangabad, was obtained. The parameter under consideration was,

**Vessel showing the occlusive lesion and its site.** The data obtained from the angiographic procedure of the patients was analysed for the above parameter, charted, compared and contrasted with that given in literature and other studies.

**Study Design:** Observational type of analytical study.

**Vessel Showing the Occlusive Lesion and its Site:** The appearance of the site of occlusive lesion depends on the severity of the lesion. It can range from luminal irregularity or nipping of the vessel to complete obstruction thereby preventing the passage of the dye distal to the obstruction. The left anterior oblique (LAO) projection is the best for better visualization of the right coronary artery and its branches, the left main, distal LAD and the proximal left circumflex (LCX). For the proximal LAD and its septal branches and the mid portion of the LCX, the right anterior oblique (RAO)

projection is the best. Hence, LAO view for the RCA and RAO view for the LAD were analysed.



RAO view showing stenosis in the proximal LAD

**Observations and Results**

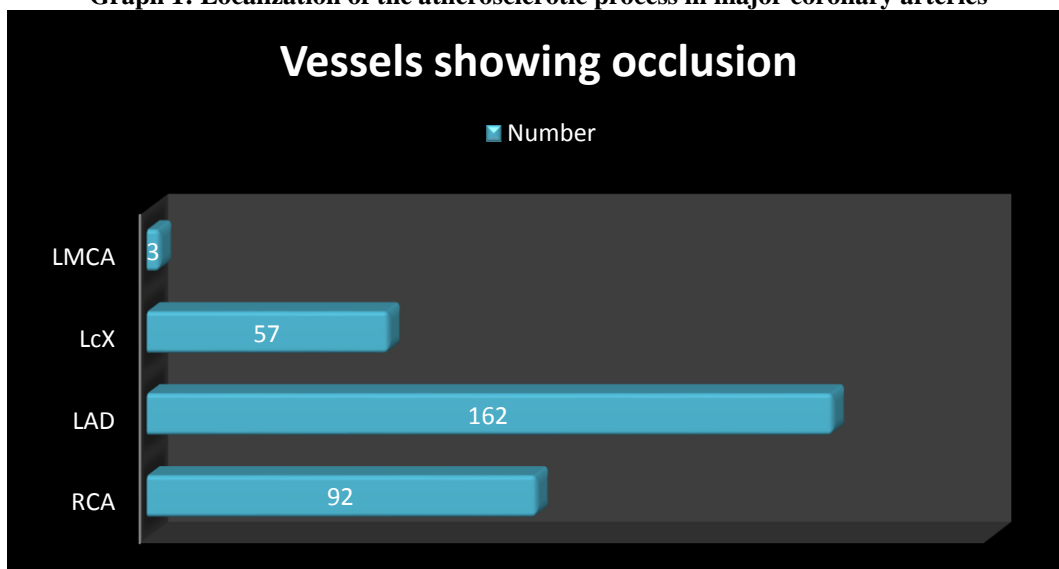
**Coronary arteries showing occlusive lesion:**

Observations on the localization of occlusive lesion in coronary arteries revealed that out of 213 cases showing the occlusion, the most common artery to show a block was LAD 162 (76%), followed by RCA 92 (43%). The least common vessel to show an occlusive lesion was left main coronary artery (LMCA).

**Table 1: Localization of the atherosclerotic process in major coronary arteries**

Vessel	Number
RCA	92
LAD	162
LcX	57
LMCA	3

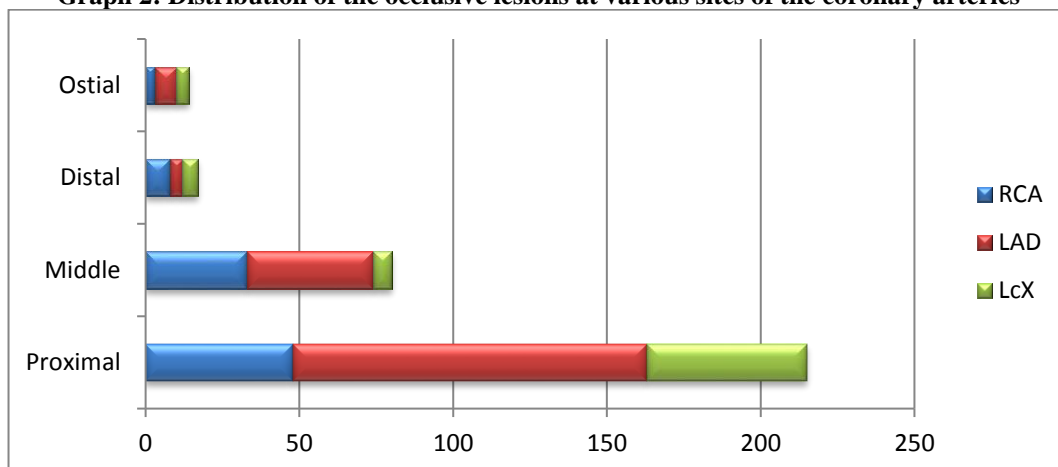
**Graph 1: Localization of the atherosclerotic process in major coronary arteries**



**Distribution of lesion at various sites within the coronary arteries:** A look at the under given Table 2 shows that for all the major coronary arteries, it was the proximal segment of the artery which showed the presence of occlusive lesion most commonly. The middle segment of the arteries was the second most common site where the lesions tend to cluster. The ostia of the coronary arteries were the least common site to show the lesion.

**Table 2: Distribution of the occlusive lesions at various sites of the coronary arteries**

	Proximal	Middle	Distal	Ostial
RCA	48	33	8	3
LAD	115	41	4	7
LcX	52	6	5	4

**Graph 2: Distribution of the occlusive lesions at various sites of the coronary arteries**

### Discussion

In the present study, LAD was the most common artery to show the occlusive lesion 162 (76%) followed by the RCA 92 (43%). This was in accordance with the study done by Chen Shao Liang<sup>(6)</sup> which also showed the LAD to be the most commonly involved vessel in occlusive lesion 54(40.9%) followed by RCA 51(38.6%). A similar view was shared by J Golshahi,<sup>(2)</sup> who found most lesions to be located in LAD (19.6%) followed by the RCA (13.7%). The anterior descending artery has been considered as the artery most frequently and severely affected by the atherosclerotic process. However the study done by G G Gensini<sup>(5)</sup> showed the RCA to be most commonly involved vessel by the occlusive lesion 91(91%) followed by LAD 83(83%).

**Table 3: Comparison of the Vessels showing occlusion**

Vessels showing occlusion	Chen Shao Liang		G G Gensini		Present study	
	No	%	No	%	No	%
RCA	51	38.6	91	91	92	43.19
LAD	54	40.9	83	83	162	76.05
LcX	27	20.5	72	72	57	26.76
LMCA	0	0	17	17	3	14.08

As far as the preferred sites for occlusive lesions within the individual branches is concerned, it was the proximal segment of the artery where the disease most commonly was found to cluster. Similar finding of preference of the proximal segment of coronary arteries to the occlusive lesion was reported by G G Gensini,<sup>(5)</sup> Hitoshi Nakagawa,<sup>(7)</sup> Kim Seong Hwan<sup>(8)</sup> and Abel E. Moreyra.<sup>(9)</sup>

### Summary and Conclusion

The LAD was the artery found most commonly to be involved in the occlusive lesion (76%), followed by the RCA (43%). Similarly, irrespective of the vessel, it was the proximal segment of the arteries found to be most commonly involved in the occlusive process. These findings were similar to that reported by various authors in their studies. Thus the preoperative information about the coronary artery anatomy and the coronary artery disease may be helpful in planning the use of coronary perfusion and other myocardial preservation techniques during coronary interventional procedures to reduce the incidence of fatal myocardial infarction.

We thus conclude that, selective coronary arteriography afford an accurate survey of the in vivo anatomy as well as of the presence, localization and extent of the obstructive lesion within them and that coronary atherosclerosis is a disease process with a tendency to involve coronary arteries in a diffuse manner.

### References

1. Standring S. The anatomical basis of clinical practice 40<sup>th</sup> Edition, Philadelphia: Elsevier Churchill Livingstone, 2008:978-980.
2. J Golshahi. Frequency of atherosclerotic lesions in coronary arteries of autopsy specimens in Isfahan forensic medical center. Journal of Research in Medical Sciences 2005;1:16-19.
3. Robbins & Cotran. Pathologic basis of disease 7<sup>th</sup> Edition: Elsevier Publication, 2004:572.
4. Ka - Hei Leong, and Robert H. Jones: Influence of the location of left anterior descending coronary artery stenosis on left ventricular function during exercise. Circulation.1982;65:109-114.
5. G G Gensini. Coronary Arteriography: A Study of 100 cases with angiographically proved coronary artery disease. Chest 1968;54:90-99.

6. Chen-Shao Liang. Clinical outcomes of percutaneous coronary intervention for chronic total occlusive lesions in remote hospitals without one site surgical support. *Chinese Medical Journal*.2009;122(19):2278-2285.
7. Hitoshi Nakagawa. Coronary spasm preferentially occurs at branch points. An angiographic comparison with atherosclerotic plaque. *Circulation: Cardiovascular Interventions*.2009;2:97-104.
8. Kim, Seong. The influence of coronary dominance on coronary atherosclerosis and distribution of coronary artery disease in Korea. *The Korean Circulation Journal*. 2006;36(1):46-52.
9. Abel E. Moreyra, Craig Sclar, John J Burns and John B. Kostis. Prevalence of Angiographically Recognizable Atherosclerosis in Non- Dominant Right Coronary Arteries. *Angiology J* 1984 Dec;35(12):760-66.