

## Anomalous origin of Musculocutaneous nerve(MCN) along with an additional nerve supply to biceps brachii & brachialis from median nerve(MN): A case report

Binita Chaudhary<sup>1,\*</sup>, Manisha Gaikwad<sup>2</sup>

<sup>1</sup>Assistant Professor, <sup>2</sup>Additional Professor, Dept. of Anatomy, AIIMS, Bhubaneswar, Odisha

**\*Corresponding Author:**

Email: binitachaudhary18@gmail.com

### Abstract

Musculocutaneous nerve is the nerve of anterior compartment of the arm & it supplies the muscles of front of the arm and skin on the lateral aspect of forearm. It is the terminal branch of lateral cord of brachial plexus. Variations of musculocutaneous nerve have been reported by previous authors. Here we present a case of unilateral anomalous origin of musculocutaneous nerve along with an additional nerve supply to biceps brachii and brachialis during routine undergraduate dissection in the left arm of 55 years old male cadaver. These variations should be searched during surgical reduction of fractures by orthopaedicians and should not be overlooked by surgeons during nerve repair to prevent damage to the additional branch which supplies muscles of anterior compartment of arm.

**Keywords:** Brachial Plexus, Lateral cord, Median nerve, Musculocutaneous nerve, Muscles of anterior compartment of arm.

**Received:** 23<sup>rd</sup> March, 2017      **Accepted:** 26<sup>th</sup> September, 2017

### Introduction

Musculocutaneous nerve normally arises as a continuation of lateral cord of brachial plexus & it supplies the muscles of the arm which acts as a flexor of forearm at the elbow joint (brachialis).<sup>(1)</sup> It also supplies the muscle which is responsible for all screwing movements (biceps brachii). Short head of biceps brachii & coracobrachialis which flexes the arm also receives supply from this same nerve. Variations in the nerves of upper limb have been reported in the literature.<sup>(2,3)</sup> Absence of MCN was found by Prasad Rao.<sup>(4)</sup> Sometimes MCN may not even pierce the coracobrachialis.<sup>(5)</sup> Complete absence of MCN and innervation of anterior compartment of arm by median nerve are uncommon as reported by Ihunwo AO et al.<sup>(6)</sup> Jamuna M & Amudha G reported absence of MCN in 6% of limbs, the nerve passed without piercing the coracobrachialis in 6% of limbs and in 2% of limbs the nerve joined the median nerve after piercing the coracobrachialis.<sup>(7)</sup>

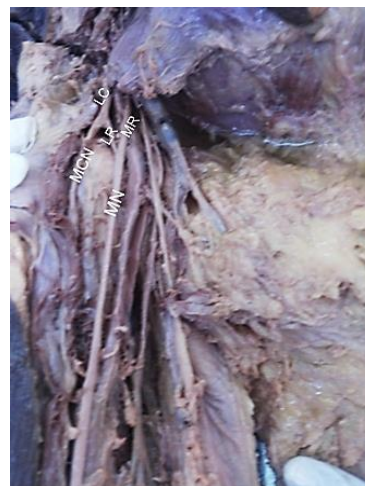### Materials and Method

During routine undergraduate dissection class, pectoral region, axilla and front of the arm of both side were dissected in a 55 years old male cadaver. Cords and branches of brachial plexus were identified. The specimen was cleaned with water and photographs were taken.

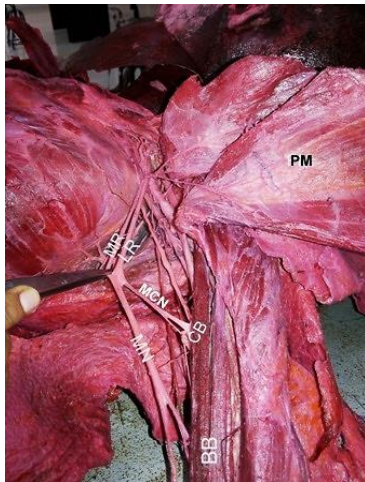
### Observation

In this case, on the left arm we found that the lateral cord is continuing as lateral root of median which after joining the median root of median forms the median nerve. It is the median nerve that is giving off musculocutaneous nerve that is going to supply the

flexors of arm (i.e. coracobrachialis & short head of biceps brachii), flexor of the forearm (i.e. brachialis) & supinator of forearm (biceps brachii). In addition to this median nerve is also giving one extra branch to biceps brachii & brachialis.



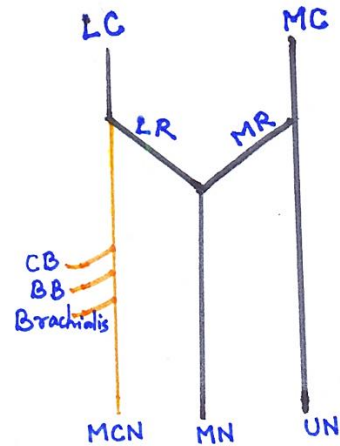
**Image (a): Normal formation of Brachial Plexus.**  
**LC- Lateral Cord,**  
**LR- Lateral Root, MR- Medial Root, MCN- Musculocutaneous Nerve, MN- Median Nerve. Here MCN is arising from the Lateral Cord. Lateral root of median joins the medial root of median to form MN which is not giving any branch to the muscles of the arm**



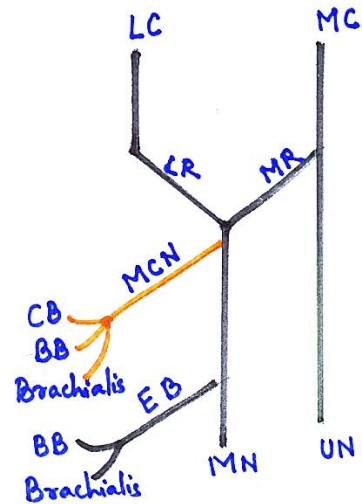
**Image (b):** MR- medial root of Median, LR- Lateral root of Median, MN- Median nerve, MCN- Musculocutaneous nerve, CB- Coracobrachialis, PM- pectoralis Major.  
In our case MR is joining LR to form MN & MCN is arising from the median nerve



**Image (c):** MCN-Musculocutaneous Nerve, CB-coracobrachialis, BB-Biceps brachii, EB-Extra branch.  
Here MCN is arising from MN & it is supplying CB, BB & Brachialis. An extra branch (EB) is arising from the MN which is also supplying BB & brachialis. Thus in our case Biceps brachii & brachialis muscle is innervated by 2 nerves



**Image (d):** LC- Lateral cord, MC-medial cord, LR- Lateral root of median, MR- Median root of median, MCN- musculocutaneous nerve, MN- Median nerve, CB-Coracobrachialis, BB-Biceps brachii.  
In normal case LC continues as MCN after giving LR



**Image (e):** EB- Extra branch.  
In our case report, LC is continuing as LR which is joining the MR to form MN & it is the MN that is giving off MCN which is supplying CB, BB, Brachialis. In addition to this MN is also giving an extra branch that is also supplying BB & brachialis

**Discussion**

Median nerve normally supplies the muscles of the forearm. In the present case muscles of anterior compartment of the arm (biceps brachii & brachialis) is having dual nerve supply. It is advantageous to the patient because the muscles function won't be hampered if the musculocutaneous nerve is accidentally cut/ damaged during surgical procedures. There will be no paralysis of biceps brachii and brachialis as it is also supplied by one extra branch. Vice versa if the extra

branch is damaged in fracture of humerus, flexion of elbow will not be hampered as it is receiving supply from musculocutaneous nerve. Variation in the origin and communication of MCN and MN have been reported. Absence of MCN along with accessory head of Biceps brachii was reported by UW Mane et al.<sup>(8)</sup> Absence of MCN with variation in the course & distribution of MN was reported by Parchand MP et al.<sup>(9)</sup> According to Le Minor, these variations are of five types.

Present finding coincides with Le Minor Type IV variant to some extent in which MCN remains absent and entire fibres of MCN passes through lateral root of MN and fibres to the muscles of anterior compartment supplied by Musculocutaneous nerve branch out directly from Median nerve, but it differs in that it is also giving an additional branch to the muscles of flexor compartment of the arm.

### Conclusion

This type of variation in musculocutaneous nerve is rare. Such variation should be searched during surgeries in axilla for lymphadenectomy, nerve repair of brachial plexus, for open reduction & internal fixation of fractures in upper arm and in anesthetic block. Surgeons may injure the branch of median nerve (MN) in the arm as normally the median nerve doesn't give any branch in the arm. Isolated lesion of MCN is rare, but occurs in injury to the upper arm & shoulder e.g. Fracture of humerus and in patients with neuralgic amyotrophy. There is marked weakness of elbow flexion because Biceps brachii & much of the brachialis is paralysed.

### Reference

1. Standring S, Borley NR, Collins P, Crossman AR, Gatzoulis MA, Healy JC, Johnson D, Mahadevan V, Newell RLM, Wingley CB. Gray's Anatomy. 40th Ed. London. Churchill Livingstone. 2008;780-81,821.
2. Kerr AT. The brachial plexus of nerves in the upper limb with reference to their variations in the formation and branches. *AMJ Anat*, 1918;23:285-395.
3. Linell EA. The distribution of nerves in the upper limb, with reference to their variabilities and their clinical significance. *J Anat*. 1921 Jan;55:79-112(S).
4. Prasad Rao PW, Chaudhary SC. Absence of the musculocutaneous nerve: two case reports. *ClinAnat*2001;14:31-5.
5. Nakatani T, Mizukami S, Tanaka S. Three cases of the musculocutaneous nerve not perforating the coracobrachialis muscle. *Kaibogaku Zasshi*. 1997 Jun;72(3):191-4.
6. Ihunwo AO, Osinde SP, Mukhtar AU. Distribution of median nerve to the anterior compartment of the arm. *Cent Afr J Med*. 1997 Dec;43(12):359-60.
7. Jamuna M, Amudha G. A cadaveric study on anatomic variations of the musculocutaneous nerve in the infraclavicular part of Brachial Plexus. *J Clin Diagn Res*. 2011;5:1144-47.
8. Mane UW, Pandhare SR. Absence of musculocutaneous nerve along with accessory head of biceps brachii. *Int J Recent Trends Sci Technol*. 2011;1:45-8.
9. Parchand MP, Patil ST. Absence of musculocutaneous nerve with variations in course and distribution of the median nerve. *Anat Sen Int*, 2013;88:58-60.
10. Le Minor JM. A rare variation of the median and musculocutaneous nerve in man. *Archives Anatomy Histology embryology*, 1990;73:33-42.