

## A cadaveric study of Gastrocnemius muscle from point of view of entrapment syndromes

Shinde Amol Ashok<sup>1</sup>, Dinesh K. Patel<sup>2\*</sup>, Varshaly K. Bharambe<sup>3</sup>

<sup>1,2</sup>Assistant Professor, <sup>3</sup>Professor, Dept. of Anatomy, Dr. DY Patil Medical College, Pune, Maharashtra

**\*Corresponding Author:**

Email: amol9267@gmail.com

### Abstract

**Introduction:** Gastrocnemius has a medial and lateral belly. It joins with soleus to get inserted as the Achilles tendon. Accessory heads of gastrocnemius can give rise to popliteal artery entrapment syndromes.

**Materials and Method:** 60 formalin embalmed lower limbs were meticulously dissected to see for any variation in number of heads and nerve supply of Gastrocnemius.

**Observations:** 15% limbs showed accessory heads of gastrocnemius. 8.34% showed 4 heads and 6.66% showed 3 heads. Length of Achilles tendon in limbs with variation ranged from 6.1 cm to 12.8 cm.

**Conclusion:** Knowledge of accessory heads of gastrocnemius will help the radiologist during imaging studies in cases of popliteal entrapment syndromes and neurovascular compression.

**Keywords:** Gastrocnemius tertius, Accessory head of gastrocnemius, Popliteal artery entrapment syndrome, Calf injury, Additional heads of gastrocnemius.

**Received:** 10<sup>th</sup> August, 2017

**Accepted:** 10<sup>th</sup> October, 2017

### Introduction

The calf is made of bipennate muscle gastrocnemius and multipennate muscle soleus. Gastrocnemius has a medial head known as capite mediale and a lateral head known as capite laterale.<sup>(1)</sup> Medial head takes origin from posterior surface of femur above medial condyle and lateral head arises above the lateral condyle. Both heads of gastrocnemius fuse to form a single belly which together with soleus forms the Achilles tendon. The Achilles tendon gets inserted on the dorsal surface of calcaneum.

The word gastrocnemius is derived from Greek words gastro and kneme meaning stomach and leg respectively. The bulging of the calf mimics the bulging of stomach, so it is also called 'stomach of leg'.<sup>(2)</sup>

The tibial nerve supplies the gastrocnemius muscle. It is strong plantar flexor of foot. Soleus acts to initiate walking while gastrocnemius is muscle used in running.

Heads of gastrocnemius form the inferolateral and inferomedial boundaries of popliteal fossa.

Close proximity to Tibial nerve and popliteal vessels in popliteal fossa makes any variant anatomy of gastrocnemius as a differential diagnosis in neurovascular compressions and entrapment syndromes.<sup>(3)</sup>

### Materials and Method

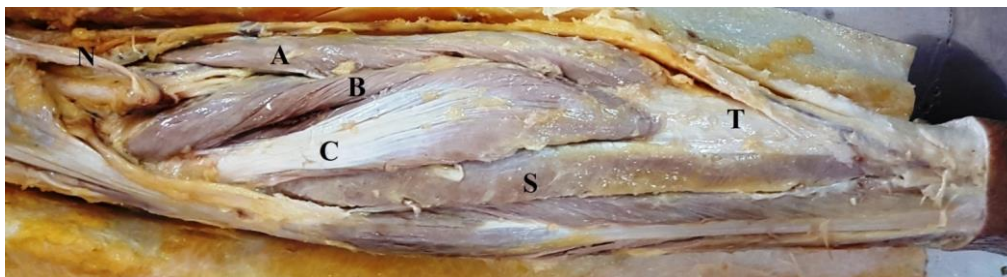Meticulous dissection of 60 formalin embalmed lower limbs was done. Any variation in number of heads, origin, insertion and nerve supply of gastrocnemius muscle is noted. Length of the heads of gastrocnemius and Achilles tendon are measured with

vernier caliper and measuring tape as applicable. Relation of the popliteal artery to the additional heads of gastrocnemius was noted.

### Result

Additional head of gastrocnemius was seen in 9 (15%) lower limbs. 3 cadavers showed bilateral variation (10%). 2 right sided and one left sided lower limb showed unilateral variation. 4 heads of gastrocnemius (Fig. 3) were seen in 5 (8.34%) limbs. 2 cadavers showed 4 heads bilaterally. One right limb demonstrated 4 headed gastrocnemius. 3 heads of gastrocnemius (Fig. 1 and 2) were seen in 4 (6.66%) limbs. One cadaver showed bilateral 3 heads of gastrocnemius. One right and one left side limb showed 3 heads of gastrocnemius. All the heads of gastrocnemius were supplied by tibial nerve. No variation in course of sural nerve was noted. The popliteal artery was seen passing between the accessory medial head and normal medial head of gastrocnemius in 2 cadavers (Fig. 3).

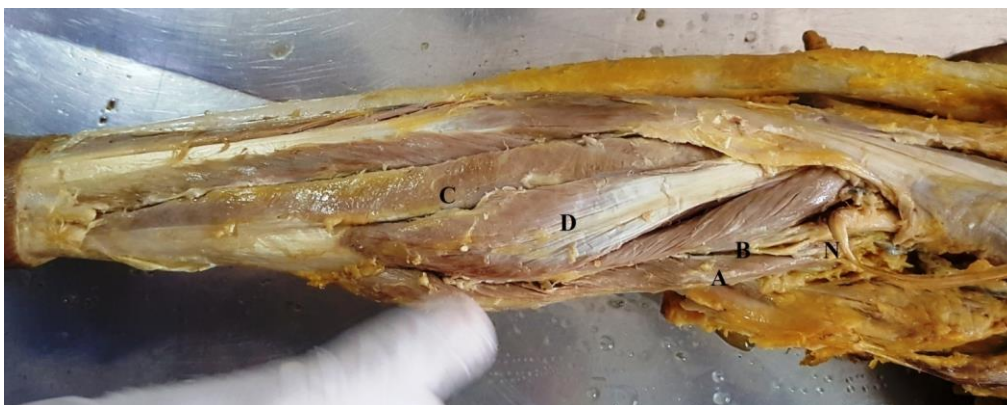
A single belly was formed by joining of all heads of gastrocnemius. This muscle belly joined with belly of soleus to form the Achilles tendon, which inserted on posterior surface of calcaneum. Length of the heads of gastrocnemius before forming common tendon and length of Achilles tendon is tabulated in Table 1. Maximum length seen for medial and lateral bellies are 7.5 cm and 9 cm respectively. Length of Achilles tendon of limbs with additional heads of gastrocnemius ranged from 6.1 cm to 12.8 cm.



**Fig. 1:** Showing three headed gastrocnemius: A – Medial head of gastrocnemius, B – Additional medial head of gastrocnemius, C – Lateral head of gastrocnemius, D – Additional lateral head of gastrocnemius, T – Achilles tendon, S – Soleus and N – Tibial nerve



**Fig. 2:** Showing three headed gastrocnemius: A – Medial head of gastrocnemius, B – Additional medial head of gastrocnemius, C – Lateral head of gastrocnemius, D – Additional lateral head of gastrocnemius and T – Achilles tendon



**Fig. 3:** Four headed gastrocnemius: A – Medial head of gastrocnemius, B – Additional medial head of gastrocnemius, C – Lateral head of gastrocnemius, D – Additional lateral head of gastrocnemius and N – Tibial nerve

**Table 1:** Showing lengths of bellies of gastrocnemius and Achilles tendon in limbs with accessory bellies of gastrocnemius

S. N.	Side	Number of bellies of Gastrocnemius	Muscle length (cm) medial to lateral	Tendon length (cm)
1	Right	4	5.2	6.1
			5.9	
			7.4	
			8.6	
2	Left	4	5.6	6.5
			5.4	
			6.9	
			7.1	
3	Right	4	7.5	12.6

			7.1	
			8.3	
			9.0	
4	Left	4	6.8	12.8
			7.1	
			9.2	
			9.4	
5	Right	4	6.7	12.5
			6.9	
			8.8	
			9.3	
6	Right	4	5.9	11.9
			6.2	
			8.4	
7	Right	3	5.6	7.2
			6.1	
			7.5	
8	Right	3	7.1	12.5
			7.2	
			7.9	
9	Left	3	7.3	12.8
			7.7	
			8.3	

## Discussion

**Embryological reasoning:** Gastrocnemius muscle embryologically originates from the calcaneum blastomere and then it migrates upwards by ascending towards the inferior epiphysis of femur. Before termination on femur it splits into medial and lateral bellies. Any variant mode of embryological migration and termination may result as variation in number of bellies and attachments.<sup>(3)</sup>

Gastrocnemius is the superficial calf muscle. It originates as medial and lateral heads. The medial head is more commonly injured. Medial head of gastrocnemius sprain is also called 'Tennis leg' as it is frequently seen in tennis players. Risk of strain of gastrocnemius is more as it crosses two joints (knee and ankle) and has type two fast acting muscle fibers. Strain of gastrocnemius is called 'coup de fouet' or snap of a whip.<sup>(4)</sup>

Sookur et al<sup>(5)</sup> in a study of variations of muscles of lower limb state that variations of medial and lateral heads of gastrocnemius are due to anomalous origins and accessory slips. Medial and lateral heads of gastrocnemius take origin from posterior surface of femur, above the condyles and from the capsule of the knee joint. Additional medial head may arise from intercondylar notch instead of medial condyle. Additional slips may arise from intercondylar notch and pass between popliteal artery and vein to get inserted into medial head. Lateral head may have a more medial origin on posterior surface of femur, but lateral to popliteal artery. Additional slips may pass anterolateral to popliteal vessels and insert in the lateral head.

In a study of gastrocnemius in Nigerian population, Ashaolu et al<sup>(3)</sup> give a 51.7% incidence of four headed gastrocnemius and 13.3% incidence for 3 headed gastrocnemius. These figures are more than our study where we got incidence of four-headed gastrocnemius as 8.33% and three headed gastrocnemius as 6.66%. Knowledge of such variations will help during popliteal nerve blocks and autografting of gastrocnemius muscle.

Shinde et al<sup>(6)</sup> in a study of soleus muscle report 8% cases of accessory head of soleus. One limb showed three-heads of gastrocnemius with an accessory head of soleus. This condition is known as gastrocnemius tertius. Coexistence of gastrocnemius tertius and accessory soleus is considered a rare variation.

Yildirim et al<sup>(7)</sup> report a case of bilateral gastrocnemius tertius with unilateral accessory head of soleus. Accessory head of gastrocnemius can lead to entrapment syndromes in popliteal fossa. Decrease in pulse of distal arteries on passive dorsiflexion suggests popliteal artery entrapment, while pain and tenderness in popliteal fossa points towards nerve compression in the popliteal fossa.

Calf injuries are one of the most common muscle injuries of leg. Gastrocnemius acts to flex the leg at knee joint and plantar flex the foot at ankle joint. Gastrocnemius injury is considered high risk because it crosses two main joints, the knee and ankle. Calf injuries occur with strenuous exercise and also on innocuous movements in middle aged people with sedentary lifestyle. Differential diagnosis for calf injury are gastrocnemius tear, thrombophlebitis, soleus tear, Achilles tendon rupture, and posterior compartment syndrome. Pain in the medial head of gastrocnemius

just above the musculotendinous junction with palpable tenderness are clinical signs to diagnose gastrocnemius tear.<sup>(8)</sup>

A case report of four headed gastrocnemius was given by Rodrigues et al.<sup>(9)</sup> They describe the medial head of gastrocnemius splitting into three heads. The multiple heads join with the lateral head to form the Achilles tendon. The sural nerve was seen entrapped between the multiple heads of gastrocnemius. Sural nerve is primarily a sensory nerve but they state that considering some communication with tibial nerve in leg, motor loss is also reported along with sensory loss in case of entrapment. No variation in course of sural nerve was seen in our study.

Popliteal entrapment syndrome was first reported by Anderson Stuart. Unilateral calf pain in a athletic young patient is a symptom seen in popliteal artery entrapment syndrome. Accessory medial head of gastrocnemius compressing the artery in popliteal fossa is the most common cause. Stenosis of the artery and early atherosclerotic changes may be seen in chronic cases. Surgical intervention to relieve the compression is considered. The popliteal artery is surgically decompressed with myotomy. This is followed by embolectomy and prophylactic fasciotomies.<sup>(10)</sup>

In a study of patients with entrapment syndromes, Rosset E et al<sup>(11)</sup> found the popliteal artery was susceptible for compression in cases of accessory heads of gastrocnemius. CT and MRI were used to define the muscular origin of popliteal compression. Higher insertion of gastrocnemius, presence of a fibrous band linking the medial and lateral head of gastrocnemius and muscular hypertrophy were causes for arterial compression.

Popliteal artery entrapment syndrome has been reported due to aberrant course of popliteal artery or accessory heads of gastrocnemius or plantaris muscle compressing a normal popliteal artery. The range of prevalence of popliteal artery entrapment syndromes is 0.16 to 3.5%. The syndrome is classified as type I in case of an aberrant course of popliteal artery, type II in case of an accessory medial head of gastrocnemius compressing the popliteal artery with a normal course. Type III anomaly has an accessory slip from the medial head of gastrocnemius, forming a sling around the popliteal artery and in Type IV a popliteal artery with normal course gets compressed by passing deep to the popliteus muscle. Any of type I to IV anomaly with popliteal vein involvement is called type V. Type VI is popliteal artery compression due to a hypertrophied gastrocnemius muscle.<sup>(12)</sup> Our study shows the popliteal artery passing between the accessory and normal medial heads of gastrocnemius in two cadavers (Fig. 1). This condition is seen in type II popliteal artery entrapment syndrome.

Radonic et al<sup>(13)</sup> describe three cases of popliteal artery entrapment syndrome. Accessory head of gastrocnemius compressing the popliteal artery was

reported. Intermittent claudication on physical activity is seen in young adults. Soldiers and athletes are more likely to succumb to popliteal artery entrapment syndromes as their muscles are well toned and enlarged. Any accessory muscle forming the boundary of popliteal fossa may lead to compression of the artery.

## Conclusion

Gastrocnemius injuries have been one of the leading causes of calf injuries. Medial head of gastrocnemius is more commonly involved. Accessory heads of gastrocnemius have given rise to entrapment syndromes in the popliteal fossa. Our study gives a 15% incidence of accessory heads of gastrocnemius. Bilateral variation is seen in 10% cadavers. Three (6.66%) and four (8.33%) headed gastrocnemius muscles are reported. Knowledge of additional heads of gastrocnemius is important while autografting and using imaging techniques for entrapment syndromes.

## References

1. Upasna, Amandeep Singh Nar, Ashwani Kumar, Atul Mishra, Ashvind Bawa. Morphological analysis of proximal gastrocnemius muscle – a study in thirty adult human cadavers. International journal of anatomy, radiology and surgery, 2016 Apr, Vol 5(2) 41-43.
2. [https://en.wikipedia.org/wiki/Gastrocnemius\\_muscle](https://en.wikipedia.org/wiki/Gastrocnemius_muscle).
3. Ashaolu J, Oni-Orisan, Ukwenya V, Alamu, Adeyemi D. Variability of the morphology of gastrocnemius muscle in an African Population. Anatomy Journal of Africa 2014, 3 (3): 400---404.
4. J. Bryan Dixon. Gastrocnemius Vs. Soleus Strain: How to differentiate and deal with calf muscle injuries. Curr Rev Musculoskelet Med. 2009 Jun;2(2):74–77.
5. Paul A. Sookur, Mrcp, Ali M. Naraghi, Frcr, Robert R. Bleakney, Frcpc, Rosy Jalan, Frcr, Otto Chan, Frcr, And Lawrence M. White. Accessory Muscles: Anatomy, Symptoms, and Radiologic Evaluation. Radiographics, March-April 2008 Volume 28, Issue 2 Pp:481–499.
6. Shinde Amol A, Patel Dinesh K and Bharambe Vaishaly K. A study of soleus muscle – clinical and embryological consideration. International Journal Of Biomedical And Advance Research 2016;7(12):608-611.
7. Fatos Belgin Yildirim, Levent Sarikcioglu and Koh Nakajima. The co-existence of the gastrocnemius tertius and accessory soleus muscles. J Korean Med Sci. Oct 2011; 26(10): 1378–1381.
8. Virginia Nsitem. Diagnosis and rehabilitation of gastrocnemius muscle tear: A Case Report. J Can Chiropr Assoc. 2013 Dec; 57(4):327–33.
9. Vincent Rodrigues, Mohandas KG Rao, and Shivananda Nayak. Multiple Heads of Gastrocnemius with Bipennate Fiber Arrangement- A Clinically Significant Variation. J Clin Diagn Res. 2016 Aug; 10(8):AD01–AD02.
10. Kemal Gokkus, Ergin Sagtas, Tamer Bakalim, Ertugrul Taskaya and Ahmet Turan Aydin. Popliteal entrapment syndrome. A systematic review of the literature and case presentation. Muscles Ligaments Tendons J. 2014 Apr-Jun;4(2):141–148.
11. Rosset E, Hartung O, Brunet C, Roche PH, Magnan PE, Mathieu JP, Branchereau A, Fariasse J. Popliteal artery entrapment syndrome. Anatomic and embryologic bases, diagnostic and therapeutic considerations following a

- series of 15 cases with a review of the literature. *Surg Radiol Anat.* 1995;17:161–169. 23–27.
12. Srinivasa Rao S, Bhagath Kumar P, Satheesha Nayak B, Kumar MR Bhat (2013) Popliteal Vessels Entrapment by a Variant Accessory Belly of Medial Head of Gastrocnemius. *Anatom Physiol* 3: 116. doi:10.4172/2161-0940.1000116.
  13. Vedran Radonić, Stevan Koplić, Lovel Giunio, Ivo Božić, Josip Mašković, and Ante Buća. Popliteal Artery Entrapment Syndrome: Diagnosis and Management, with Report of Three Cases. *Tex Heart Inst J.* 2000;27(1):3–13.