

## A study on the occurrence of human femoral third trochanter

Rajad R<sup>1</sup>, Rani Raphael M<sup>2\*</sup>, Romi S<sup>3</sup>

<sup>1,2</sup>Assistant Professor, <sup>3</sup>Professor, Dept. of Anatomy, Govt. TD Medical College, Alappuzha

\*Corresponding Author:

Email: raniraphael1975@gmail.com

### Abstract

**Introduction:** The human femoral third trochanter is described as a projection from the proximal aspect in the upper part of gluteal tuberosity. This projection could be in the form of an oblong, rounded or conical shape. This projection is called third trochanter with reference to the greater trochanter and lesser trochanter. Studies on the third trochanter are comparatively less in number.

**Materials and Method:** 100 human femora of unknown sexes from the Department of Anatomy, Government T.D Medical College, Alappuzha, Kerala, were inspected to estimate the occurrence of third trochanter.

**Result:** The third trochanter was present in 13 bones (13%). The frequency of occurrence was 13.46% in left and 12.5% in right. The mean vertical length was 15.81 mm and the mean breadth was 8.48 mm.

**Conclusion:** The third trochanter of femur with an incidence of 13% in the present study might potentially influence the fracture line in pertrochanteric fracture. Its presence should be taken into consideration while modeling the pre contoured femoral plates.

**Keywords:** Gluteal tuberosity, Pertrochanteric fracture, Proximal femur, Third trochanter.

Received: 3<sup>rd</sup> April, 2017

Accepted: 29<sup>th</sup> April, 2017

### Introduction

The proximal parts of the femur normally consist of the head, neck, greater trochanter and lesser trochanter. The gluteal tuberosity is described as an elongated depression or a ridge to which the gluteus maximus muscle is attached. Its upper part may be prominent enough to be called a third trochanter.<sup>(1)</sup> When present it may be oblong, oval or conical in shape and mostly present lateral to a line connecting the tip of greater trochanter to the superior bifurcation of line a aspera.<sup>(2)</sup> Finnegan, Michael and Faust states that the difference between the third trochanter and the gluteal ridge is based on kind and not degree of development.<sup>(3)</sup>

Its function as described in many studies is to provide an additional area of attachment to the ascending tendon of gluteus maximus.<sup>(4)</sup> So it should be present in individuals with greater strength of the muscle. Another role of the third trochanter described is to alternate the direction of the insertion of tendon of the gluteus maximus muscle. In this scenario the third trochanter would serve as a trochlea to alternate the direction of the tendon before it inserts to the rest of gluteal tuberosity.<sup>(2)</sup>

The clinical significance of the study lies in the mechanism and management of pertrochanteric fractures. There is correlation between the muscle insertions and the topography of break lines in pertrochanteric fractures of the proximal femur.<sup>(5)</sup> An awareness and knowledge of the anatomy of third trochanter is of use in managing fractures in this region.

The objective of the present study was to determine the occurrence of third trochanter in femur. This study is justified by the comparatively lesser number of

existing studies on the same and the need to compile data which could be of clinical use in proximal femoral procedures with the technical advances aiding it. The study can also be used to evaluate micro-evolutionary trends.<sup>(6)</sup>

### Materials and Method

The study was conducted in 100 human dried adult femora of unknown sexes from the Department of Anatomy, Government T.D Medical College, Alappuzha, Kerala. Only those femora with undamaged region of third trochanter were included in the study. There were 52 left femora and 48 rights. They were inspected for the presence of third trochanter. When present the length and breadth of the third trochanter was measured with a digital vernier caliper.

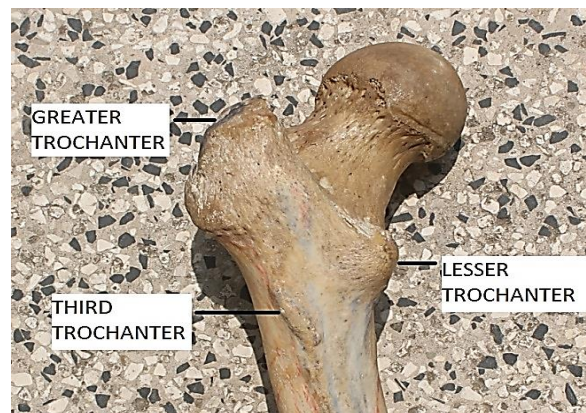


Fig. A: Showing a left femur with third trochanter

## Results

Of the 100 femora studied the third trochanter was present in 13 bones (13%). 7 were in left and 6 in right. So the frequency of occurrence was 7 out of 52 in left and 6 out of 48 in right (13.46% and 12.5% respectively). The mean vertical length was 15.81 mm (15.61 mm in left and 16.04 mm in right). The mean breadth was 8.48 mm (8.27 mm in left and 8.74 mm in right).

**Table 1: Measurements of the third trochanter (in mm)**

Side	Length	Width
Right	16.04±5.72	8.74±2.78
Left	15.61±3.28	8.27±2.41
Total	15.80±4.37	8.48±2.48

## Discussion

The third trochanter is of great significance in anthropometry and is extensively studied in prehistoric skeleton from excavation sites as an infracranial nonmetric trait for quantitative studies of population affinities.<sup>(4)</sup> The phenotypic development and expression of such discontinuous skeletal traits like the third trochanter are largely controlled by genetic factors.<sup>(7)</sup> But it is also partially dependent on generalised or local size variation.<sup>(8)</sup> Studies have also shown that various biological and environmental factors such as age, sex, nutritional status or side dependence are also responsible for the manifestation of such nonmetric traits.<sup>(9)</sup> Local mechanical factors also influence this.<sup>(10,11)</sup> A study on excavated human femora showed it is present more in females but it was considered to be related to the hard living conditions rather than heredity.<sup>(12)</sup>

It is present in various species of mammals but there is still no definite conclusions about its evolutionary significance that whether it is a progressive or regressive feature. This is because it is present in rats, rabbits, whales<sup>(2)</sup> and extremely well developed in horses and rhinoceros but not so in many primates including apes.<sup>(13)</sup> It is frequently present and well developed in Neanderthals but not in many other anthropoid species.<sup>(2)</sup>

The occurrence of third trochanter is 13% in the present study. This is consistent with the findings in other studies in Northern Tamilnadu(13.72%)<sup>(14)</sup> and Pakistani population(13.9%);<sup>(15)</sup> but higher than the studies in general Indian population by Ghosh et al (6.6%),<sup>(16)</sup> in excavated Polish femora by Bolanowsky (6.1%) and in Northern Karnataka (4.43%).<sup>(17)</sup> A definite population group could not be drawn for the study because a major portion of the bones were purchased from outside for study purposes.

As described in literature the third trochanter was found to be of two varieties – a flattened rough rectangular elevation or as an oval prominence. The

mean vertical length was found to be 15.81 mm and mean breadth 8.49 mm. This is in discordance with the study by N Muthukumaravel and K.Y. Manjunath,<sup>(14)</sup> where mean vertical length was 19.81±5.22 mm and mean breadth 7.63±1.75 mm. Ajita et al reports a case of third trochanter from Manipur, India which measured 18 mm in length.<sup>(18)</sup> Literature describing the dimensions of third trochanter is scarce. The maximum length encountered in the study was in a right femur (25.5 mm) and the maximum breadth was 12.81 mm in the same femur.

Previous studies show that the presence of third trochanter is more in right side.<sup>(3)</sup> But in the present study there is no such significant variation. This may be because of another limitation of the present study that right and left femora are not from the same skeleton. It is not possible to verify whether the left femora with third trochanter had one in their right counterpart and not suitable for right left comparison.

Clinical relevance of this study is in fracture treatment. The findings can be useful in intramedullary reaming and nailing of proximal femur.<sup>(19)</sup> Attachments of muscles and ligaments act as reinforcing elements to the bone. When there are no such attachments and the bone is covered with periosteum only it offers little resistance for onset of fractures.<sup>(20)</sup> In an animal model study using Armadillo femur when coronal plane forces were applied it was found that the muscles attaching to the third trochanter can counter the bending strains in the loaded femur.<sup>(21)</sup> So theoretically there is a possibility that the femora with third trochanters are more resistant to fractures. With the advent of proximal femoral-locking compression plate (PF-LCP), which is a precontoured fixation device which can improve osteosynthesis of fractures of the trochanteric region of femur, any anthropometric data of the same can be used for the anatomical shape design of these femoral plates.<sup>(22)</sup>

## Conclusion

In the present study which was conducted in 100 femora to document the presence of third trochanter and find its incidence, the incidence was found to be 13%. Its mean length was found to be 15.80±4.37 mm and breadth 8.48±2.48 mm. The study could not find any significant right or left predominance of third trochanter. This data can be used in the analysis and management of pertrochanteric fractures in individuals with third trochanter. If sufficient samples are available we recommend researchers to undertake a study with right and left femora from same skeleton and common population group. It is also recommended that a further study can be done in loaded human femoral models with third trochanter to determine whether its presence influences fracture lines.

## References

1. A Williams and R Newell. Pelvic girdle, gluteal region and hip joint in Gray's Anatomy, Churchill Livingstone Elsevier 39th Edition 2005;1433.
2. Bolanowski W, Smiszkievicz- Skwarska A, Polguj M, Jedrzejewski K S. The occurrence of the third trochanter and its correlation to certain anthropometric parameters of the human femur. *Folia Morphol.* 2005;64(3):168-75.
3. Finnegan M. Non-metric variation of the infracranial skeleton. *J Anat.* 1978 Jan; 125(Pt 1):23-37.
4. Lozanoff S, Sciulli PW, Schneider KN: Third trochanter incidence and metric trait covariation in the human femur. Third trochanter incidence and metric trait covariation in the human femur. *J Anat.* 1985 Dec;143:149-59.
5. Bartoska R, Baca V, Kachlik D, Marvan J, Dzupa V. The correlation between muscles insertions and topography of break lines in pertrochanteric fractures: a comprehensive anatomical approach of complex proximal femur injuries. *Surg Radiol Anat.* 2013 Apr 30.
6. Rajkumari Ajita, Aribam Jaishree, G. Tempy Sangma, Purnabati S. The Third Trochanter in Human Femur: A Case Report. *Journal of Evolution of Medical and Dental Sciences* 2015; Vol. 4, Issue 41, May 21; Page: 7224-7228, DOI: 10.14260/jemds/2015/1047.
7. Carolineberry A, Berry RJ. Epigenetic variation in the human cranium. *J Anat.* 1967 Apr; 101 (Pt 2): 361-79.
8. Howe, w. & parsons, p. (1967). Genotype and environment in the determination of minor skeletal variants and body weight in mice. *Journal of Embryology and Experimental Morphology* 17, 283-292.
9. Dahinten SL, Pucciarelli HM. Effect of age, sex and nutrition on discontinuous traits of rat skull. *Acta Anat (Basel).* 1981;110(2):159-63.
10. Moss ML. Genetics, epigenetics and causation. *Am J Orthod.* 1981 Oct;80(4):366-75.
11. Moss ML, Moss-Salentijn L. The muscle bone interface: An analysis of a morphological boundary. Monograph 8, Ann Arbor, Centre for Human Growth and Development, University of Michigan. 1978; p39-71.
12. Zehra Akgün, İhsaniye Çoşkun. Upper Part Variations in Byzantine Femurs, *Uludag University Medical Faculty Magazine.* 35(3):127-130, 2009.
13. C. Owen Lovejoy et al. The Pelvis and Femur of *Ardipithecus ramidus*: The Emergence of Upright Walking. *Science.* 2009 Oct. VOL 326 2 p71(e1-e5).
14. Muthukumaravel.N, Manjunath K.Y. A study on occurrence of third trochanter in the femora in Northern Tamil Nadu region. *National journal of clinical Anatomy* 2015;vol-4(4)pg.186-189.
15. N Aziz, T Nadeem, A A Mubarik. A Study of Third Trochanter in Femora of Pakistani Population. *Ann King Edward Med Uni Apr - Jun 1996*;2(1-2):8-11.
16. Ghosh S, Sethi M, Vasudeva N. Incidence of third trochanter and hypotrochanteric fossa in human femora in Indian population. *OA Case Reports* 2014 Feb 25;3(2):14.
17. Sarita Sylvia, Md.Khaleel Ahmed, Priyanka Jainapur. Third trochanter of human femora in North Karnataka region. *Int J Anat Res* 2015;3(2):1011-1014.
18. Rajkumari Ajita, Aribam Jaishree, G. Tempy Sangma, Purnabati S. The Third Trochanter in Human Femur: A Case Report. *Journal of Evolution of Medical and Dental Sciences* 2015; Vol. 4, Issue 41, May 21; Page: 7224-7228.
19. P Bokariya et al. Anthropometric Study of Femur in Central Indian Population. *J MGIMS, September 2009, Vol 14, No (ii), 47 – 49.*
20. Bartoska R, Baca V, Kachlik D, Marvan J, Dzupa V. The correlation between muscles insertions and topography of break lines in pertrochanteric fractures: a comprehensive anatomical approach of complex proximal femur injuries. *Surg Radiol Anat.* 2013 Apr 30.
21. Paul O'Higgins and Nicholas Milne. Applying geometric morphometrics to compare changes in size and shape arising from finite elements analyses. *Hystrix, It. J. Mamm.* (2013) 24(1):126–132.
22. Kun-Jhih Lin, Hung-Wen Wei: Proximal Femoral Morphology and the Relevance to Design of Anatomically Precontoured Plates: A Study of the Chinese Population, *Scientific World Journal, Vol. 2014.*