

Pre-ureteral and Pre Common Iliac Arterial (Rt) Vena Cava – A case report

Suba Ananthi K^{1,*}, Sandosh S², Aruna S³

¹Associate Professor, ²Tutor, ³Professor & HOD, Dept. of Anatomy, Indira Gandhi Medical College & Research Institute, Kadirkanan, Puducherry

***Corresponding Author:**

Email: subasara@yahoo.com

Abstract

Pre-ureteral vena cava is a rare congenital anomaly that results from altered vascular development. During routine dissection of the abdominal cavity of a 62year old male cadaver in the department of Anatomy, a congenital anomaly of right preureteric vena cava was observed. The right ureter coursed behind inferior vena cava but anterior to right psoas major muscle and then emerged between the inferior vena cava and abdominal aorta. Inferior vena cava was formed anterior to the common iliac arteries which is very rare. The left ureter crossed in front of inferior venacava and then right common iliac artery and entered pelvis. Pelvic part of ureter was normal. The course of left ureter was normal. There was no obvious dilatation of renal pelvis. Imaging studies such as helical CT scan and magnetic resonance imaging (MRI) can clearly demonstrate the entire course of ureter.

Keywords: Kidney, Ureter, Inferior vena cava, Psoas major, Abdominal Aorta, Common iliac artery.

Introduction

Pre-ureteral vena cava is a rare congenital anomaly with ureter coursed to retrocaval area. Pre-ureteral vena cava is also referred as circumcaval ureter or retrocaval ureter. Pre-ureteral vena cava results from altered vascular rather than ureteral development which was the earlier view. Hence pre-ureteral vena cava is the more accurate term rather than Imaging studies such as helical CT scan and magnetic resonance imaging (MRI) can clearly demonstrate the entire course of ureter the retrocaval ureter.⁽¹⁾ The incidence of pre-ureteral vena cava in autopsy is 1 in 1500. It is more common in males than in females with a ratio of 3:1.⁽²⁾ Though it is a congenital anomaly, most of the patients do not present until the third or fourth decade of life.⁽³⁾ Pre-ureteral vena cava was first reported in human by Hochstetter in 1893.⁽⁴⁾

Case Report

During routine dissection of the abdominal cavity of a 62year old male cadaver in the department of Anatomy, a congenital anomaly of right preureteric vena cava was observed. The right ureter passing out of hilum, coursed medially downwards for about 2cm with 45 degree angulation. The next 5cm of right ureter was oblique downwards and passed posterior to Inferior vena cava but anterior to the right psoas major muscle. Then it emerged between the abdominal aorta and inferior vena cava (Fig. 1). With a concavity towards the right, it coursed in front of inferior vena cava, anterior to right common iliac vein and artery it entered the pelvis to open into the urinary bladder. Left ureter was normal. Inferior vena cava was formed anterior to the right common iliac artery which is very rare.

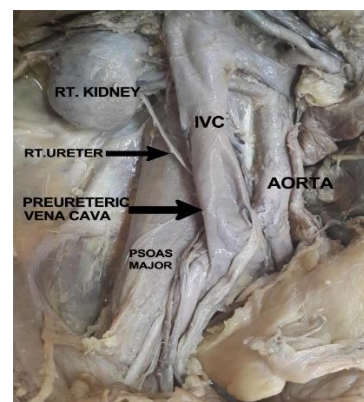


Fig. 1: Arrow shows the right preureteric vena cava and ureter emerging between inferior vena cava and aorta. Inferior vena cava is formed anterior to the right common iliac artery

Discussion

Inferior vena cava develops on right side from a plexus of fetal veins. Among the three parallel channels, the posterior cardinal vein and supracardinal vein lie dorsally whereas the subcardinal vein lies ventrally. These channels with their anastomosis form a collar on each side through which the ascending kidney pass. Normally the infrarenal portion of the inferior vena cava is formed largely by the right supracardinal vein. When the lumbar portion of the subcardinal vein fails to atrophy and becomes the primary right sided vein, right ureter is trapped dorsal to it.⁽⁵⁾ In our case, in addition to preureteric vena cava, inferior vena cava was formed anterior to the right common iliac artery which is a rare anomaly. This is again due to the persistence of right subcardinal vein. Usually, vena cava is formed behind common iliac arteries.

Pre-ureteral vena cava is mostly observed in the right side. In complete or partial situs in versus or

duplication of Inferior vena cava, pre-ureteral vena cava can be observed on the left side.⁽⁶⁾ Bateson and Atkinson in 1969, classified pre-ureteral vena cava into two types according to the radiological appearance and the site of ureteral narrowing. Type 1 is the commonest and upper ureter and renal pelvis typically elongated and dilated in a fishhook shape before passing behind IVC at the level of third lumbar vertebra. Type 1 mostly present with hydronephrosis and obstruction occurs at the edge of the iliopsoas muscle, at which point the ureter deviates cephalad before passing behind vena cava. In type 2, upper ureter is not kinked and passes behind IVC at a higher level, with renal pelvis and upper ureter lying almost horizontal before encircling IVC in a smooth curve. There is lesser degree or no hydronephrosis. If obstruction is present, then it appears to be at the lateral wall of IVC as the ureter is pressed against perivertebral tissues. Type 2 is present in 10% of all cases.^(3,7) The pre-ureteral vena cava which we observed belongs to Type I with no hydronephrosis.

Patients can present with right flank pain, urinary tract infections, hematuria or can be asymptomatic. Since there is gradual development of hydronephrosis, patients become symptomatic in their third or fourth decades. Main causes of hydronephrosis are lumen stenosis, torsion and adhesion of the retrocaval segment.⁽³⁾ The retrocaval segment can be compressed by the vena cava, psoas muscle or spinal column that leads to inflammation and fibrosis. In our case, inferior vena cava was lying anterior to right common iliac artery, which can lead to compression. Ultrasonogram of abdomen is a non-invasive method to demonstrate hydronephrosis. Imaging studies such as helical CT scan and magnetic resonance imaging (MRI) can clearly demonstrate the entire course of ureter.⁽⁸⁾ Nuclear renal furosemide scanning can categorize the anomaly as obstructed or non-obstructed.⁽⁹⁾

Treatment varies according to their presentations, severity of hydronephrosis and impairment of renal function. Surgical correction involves ureteral division with relocation and ureteroureteral or ureteropelvic reanastomosis with resection of retrocaval segment. Ureteral blood supply must be preserved during the ureteral dissection. Nowadays laparoscopic or retroperitoneoscopic ureterolysis and reconstruction of retrocaval ureter is popular with more minimal pain and more success rate.^(10,11,12) In a unilateral functional kidney surgical division of the anomalous venacava and its reposition behind the ureter can be done without disturbing the ureter. With advancement in imaging studies and surgical techniques, the diagnosis and treatment of pre-ureteric vena cava has become easy.

Reference

1. Walsh PC, Campbell's Urology. Vol IV, 9th ed. Philadelphia: W.B Saunders Elsevier (2007), 3418-20.
2. Heslin JE, Mamonas C. "Retrocaval ureter: Report of 4 cases and review of literature". Journal of Urology (1951) 65, 212-222.

3. Kenawi MM, Williams DI. "circumcaval ureter: a report of 4 cases in children with a review of the literature and a new classification". British Journal of Urology (1976) 48,183-192.
4. Ouyang CC, Cheuh SC, Hsu TC, Chen J, Tsai TC, Chiu TY. "Retrocaval ureter- three case reports and review of the literature" Journal of Urology (1994) 5, 49-53.
5. Hollinshead WH, Anatomy for surgeons, vol 2, 2nd edition, London Harper & Row Publishers (1971)587-589.
6. Watanabe M, Kawamura S, Nakada T. "Left pre-ureteral vena cava associated with partial situs inversus" Journal of Urology (1991) 145, 1047-1048.
7. Bateson EM, Atkinson D. "Circumcaval ureter: a new classification". Clin Radiol (1969) 20, 173-177.
8. Uthappa MC, Anthony D, Allen C. "Case report: Retrocaval ureter: MR appearances". British Journal of Radiology (2002) 75, 177-179.
9. Pienkny AJ, Herts B, Streem SB. "Contemporary diagnosis of retrocaval ureter". Journal of Endourology (1999) 13(10), 721-722.
10. Matsuda T, Yasumoto R, Tsujino T. "Laparoscopic treatment of a retrocaval ureter". European Urology (1996) 29, 115-118.
11. Ramalingam M, Selvarajan K. "Laparoscopic transperitoneal repair of retrocaval ureter: report of two cases". Journal of Endourology (2003) 17, 85-87.
12. Gupta NP, Hemal AK, Singh I, Khaitan A. "Retroperitoneoscopic ureterolysis and reconstruction of retrocaval ureter". Journal of Endourology (2001) 15, 191-193.