

The study of Osteomeatal complex and its anatomical variations in Government Medical College and superfacility Hospital of Azamgarh

Manisha Upadhyay^{1,*}, M.K. Gupta², Ganesh Kumar³, Anand Bihari⁴

¹Associate Professor Dept. of Anatomy, ²Associate Professor Dept. of ENT, ³Professor Dept. of Radiology, ⁴Statistician cum Lecturer SPM & SFH Dept., GMC Azamgarh

*Corresponding Author:

Email: manishaup73@gmail.com

Abstract

The present study was a hospital based study carried out in 50 patients in department of anatomy, otolaryngology and radiology of the government medical college and superfacility hospital Azamgarh U.P. The aim of this study to study the role of anatomical variations of osteomeatal complex in rhinosinusitis. Lateral nasal wall of each nasal cavity provides the final common pathway of drainage of mucociliary clearance of frontal, maxillary and anterior ethmoid air cells. Anatomical variants like concha bullosa, haller cells, aggenasi cells, enlarged bulla ethmoidalis may obstruct the drainage pathway and cause rhinosinusitis. In our study computed tomography(CT) was done for assessment of paranasal sinuses, nasal fossae and their anatomical variants. Computed tomography offer detailed study of anatomical variation and it is invaluable tool for managing clinical decision and planning surgical strategies. It has become imperative for radiologist and clinicians to improve understanding of osteomeatal complex.

Keywords: Osteomeatal complex, Paranasal sinuses, Sinusitis, Anatomical variation, Medial body line, Computed tomography (CT).

Introduction

Throughout the history of medicine numerous attempts have been made to illuminate and examine the inside of various hollow cavities located within the body. The introduction of the endoscope as a tool to help sinus surgery along with philosophy of aerating and restoring mucociliary clearance has simulated interest in both anatomy and pathophysiology of paranasal sinuses(Jones 2002).⁽¹⁾ In the present study osteomeatal complex defined as a functional unit of anterior ethmoidal complex representing the final common pathway for drainage and ventilalation of frontal, maxillary and anterior ethmoidal sinuses(Freitas & Boasquevisque 2008).⁽²⁾ The blockade in the osteomeatal complex (OMC) leads to impaired drainage of maxillary, frontal and anterior ethmoid sinuses thus causing rhinosinusitis. Dua et al.(2005)⁽³⁾ reported that removal of disease in osteomeatal complex region is the basic principle of functional endoscopic sinus surgery(FESS), which is best appreciated on CT scan. The health and normal function of nose and paranasal sinuses and their lining mucus membrane depend primarily on two important features: Ventilation and drainage. Normal ventilation of paranasal sinuses requires both a patent ostium and a patent pathway (prechamber) connecting the ostium to nasal cavity (Tonai & Baba 1996).⁽⁴⁾ Different type of anatomical variants of osteomeatal complex present distinct relation with either clinical or tomographical sinus disease. Main anatomical variants are middle concha bullosa, haller and aggenasi cells, nasal septum deviation and enlarged ethmoidal bulla. Description of various anatomical variants of osteomeatal complex is main aim of our study. Stammberger and

Hawke(1993)⁽⁵⁾ have shown that CT examination of paranasal sinuses will provide an anatomic road map of paranasal sinuses to identify the significant anatomic abnormalities. Liu et al⁽⁶⁾ have demonstrate the greater the size of anatomical variants the higher the frequency of association with paranasal sinus mucosal alteration at CT.

Development and Anatomy of Paranasal sinus at CT: The development of paranasal sinuses starts early in the fetal period as nasal cavity invaginations. Only the maxillary and ethmoidal sinuses present at birth. The frontal and sphenoidal sinuses develop from first year of life (Dutra & Marchiori 2002)⁽⁷⁾ and attained maturity upto the age of 12-14 years (Kronemer & Mcalister 1997),⁽⁸⁾ (Scuderi et al 1993).⁽⁹⁾ The ethmoidal cells pneumatization process may originate some variant cells like aggenasi, concha bullosa and haller's (kronemer & Mcalister 1997, Scuderi et al 1993).^(8,9) By the 63rd -70th day prenatal development six major furrows develop in the lateral nasal wall along with their corresponding folds called the ethmoturbinals. Stammberger 1991⁽¹⁰⁾ divides these folds into two anatomical components, an anterior-ascending portion and posteorinferior- descending portion. The ascending portion remain as the aggenasi and descending portion of the first ethmoturbinale remain as uncinat process. Therefore on the embryological basis uncinat process is the basal lamella of first ethmoturbinale, ethmoid bulla evolve from second basal lamella and middle turbinate from third basal lamella. The nasal cavity is divided into right and left sides by osseocartilagenous nasal septum. The lateral nasal wall consist of superior, middle and inferior turbinates. The middle meatus is most

important with an opening –semilunar hiatus- which receives main drainage pathways from the paranasal sinuses the drainage to this fissure is done by the frontal sinus, through the frontal recesses, and the maxillary sinus, through the infundibula, middle and anterior ethmoidal cells. The semilunar hiatus and surrounding structures together compose the osteomeatal complex (Laine & Smoker)⁽¹¹⁾ and obstruction of this narrow region is a key factor in the development of chronic sinusitis (Tonai & Baba,⁽⁴⁾ Isaacson,⁽¹²⁾ Zinreich⁽¹³⁾). Hence presence of anatomical variations around osteomeatal complex may adversely affect the drainage and ventilation of frontal, maxillary and anterior ethmoidal air cells causing rhinosinusitis, is the focus of present study.

Materials and Method

The present study has been done in department of anatomy, otolaryngology, and radiology of the Government Medical College and Superfacility hospital, Azamgarh, UP. This study was conducted from November 2013 to October 2015. This study was done on the coronal CT scan of the paranasal sinuses of the 50 patients suffering from rhinosinusitis. Informed consent was obtained from the patients. Following CT scan, data was collected and analysed using software for radiological measurements. CT scan was done with single slice spiral computed tomographic scanner with the slice thickness 2-5 mm. Table increment 3-4 mm in each step and gantry angulation perpendicular to orbitomeatal base line, kv peak 120 mA/s 150-200. The data was collected in pretested semi-structured questionnaire using software for radiological measurements.

Operational definitions: Reference line in this study was the medial body line (MBL) extending from lower extent of crista galli to the base of nasal septum. Variations like concha bullosa, agger-nassicells and haller cells were measured from this reference line.

Results and Observations

Table 1

Dimension	Right bulla ethmoidalis		Left bulla ethmoidalis	
	Mean	SD	Mean	SD
Distance From MBL (mm)	5.42	0.03	5.43	0.04
Length (mm)	6.9	0.22	7.02	0.3
Breath (mm)	6.31	0.3	6.32	0.26
Height (mm)	6.34	0.22	6.35	0.17
Volume (mm ³)	148.01	10.18	149.66	7.67

Table 2

Dimension	Right agger-nasi cell		Left agger-nasi cell	
	Mean	SD	Mean	SD
Distance From MBL (mm)	4.78	0.55	4.70	0.56
Length (mm)	5.06	0.42	4.84	0.25
Breath (mm)	5.23	0.12	4.91	0.46
Height (mm)	6.91	0.22	6.31	0.25
Volume (mm ³)	85.12	2.97	69.47	1.11

Table 3

Dimension	Right concha bullosa		Left concha bullosa	
	Mean	SD	Mean	SD
Distance From MBL (mm)	1.33	0.19	2.31	0.17
Length (mm)	8.44	0.02	9.25	0.15
Breath (mm)	8.31	0.08	9.38	0.28
Height (mm)	10.40	0.28	10.32	0.18
Volume (mm ³)	384.53	3.13	365.10	2.99

Table 4

Dimension	Right Haller cell		Left Haller cell	
	Mean	SD	Mean	SD
Distance From MBL (mm)	10.38	0.09	10.31	0.30
Length (mm)	6.32	0.27	6.20	0.21
Breath (mm)	4.23	0.09	4.15	0.17
Height (mm)	4.54	0.31	4.24	0.17
Volume (mm ³)	66.33	0.19	66.22	0.20

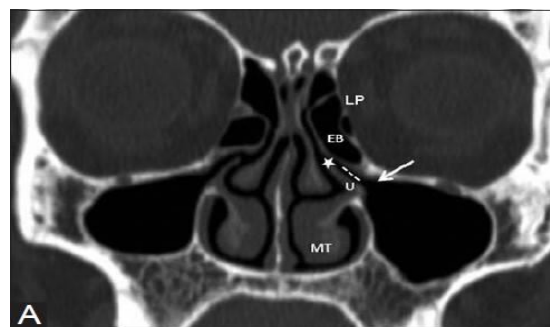


Fig. 1: Coronal CT slice at the level of osteomeatal complex showed bulla ethmoidalis (arrow)

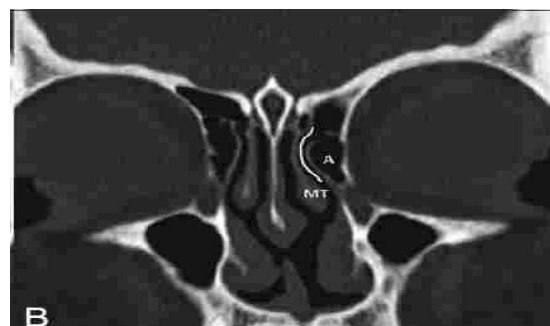


Fig. 2: Coronal CT slice at osteomeatal complex level showed agger-nasicells(A)

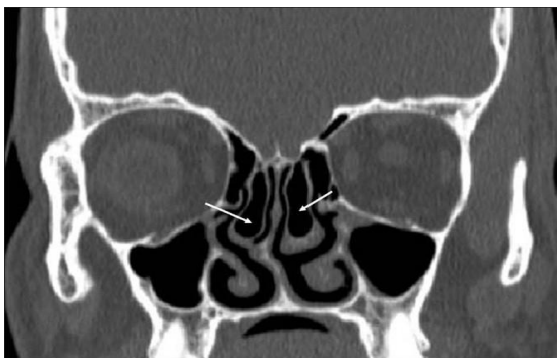


Fig. 3a: Coronal CT slice showed concha bullosa(arrow)

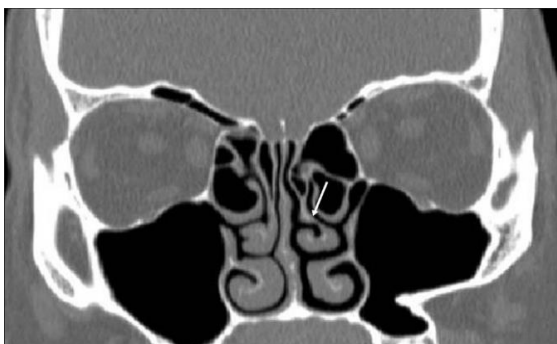


Fig. 3b: Showed paradoxical concha(arrow)

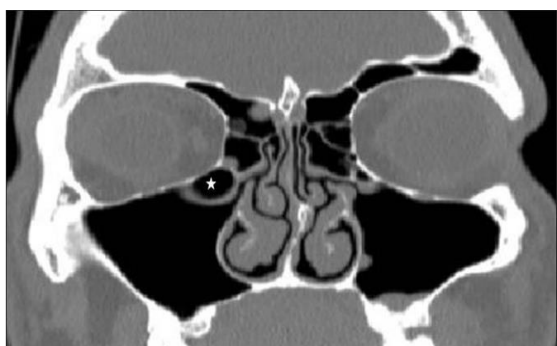


Fig. 4: Coronal CT slice at osteomeatal complex level showed Haller cells(*)

Clinically 77% of study population had presenting symptoms of sneezing 58% and 37% had presenting the symptom of rhinorrhea and headache respectively.

Among 50 studied patients, 14% have concha bullosa, 12% have paradoxical middle choncha, 20% have haller cells, 16% have aggernasi cells.

In this study population, bulla ethmoidalis, which is formed by pneumatisation of bulla lamella, or second ethmoid basal lamella and is like a bleb on lamina Stammberger et al1995⁽¹⁴⁾ and it is described in Table 1. The mean distance of right bulla ethmoidalis from MBL is 5.42 mm with standard deviation of 0.03. The mean distance of left bulla ethmoidalis from MBL is 5.43 mm with Standard deviation of 0.04. Mean length, breath, height and volume of right bulla is 6.9mm, 6.31mm, 6.34mm and 148.01mm³ respectively. Mean length,

breath, height and volume of left bulla is 7.02 mm, 6.32 mm, 6.35mm and 149.66mm³. In the Fig. 1 coronal CT slice at the level of osteomeatal complex showed bulla ethmoidalis (arrow).

Aggernasi cell, which is the most anterior ethmoidal cell, represents the pneumatisation of lacrimal bone due to ethmoidal extension. Table 2 shows dimensions of aggernasicell. It shows mean length, breath, height and volume of right aggernasi cell to be 5.06mm, 5.23mm, 6.91mm and 85.12 mm³ respectively. The distance from MBL is 4.78mm. In Fig. 2 coronal CT slice at osteomeatal complex level showed aggernassi cells(A). The mean length, breath, height and volume of left aggernassi cell is 4.84mm, 4.91mm, 6.31mm and 69.47 mm³ respectively. Mean distance from MBL is 4.7 mm.

The concha bullosa is the pneumatized middle turbinate. Its dimensions are noted in Table 3. It shows length, breath, height and volume of right concha bullosa to be 8.44m, 8.31mm, 10.40mm and 384.53 mm³ respectively. Its distance from MBL is 1.33 mm. The length, breath, height and volume of left concha bullosa is 9.25mm, 9.38mm, 10.32mm and 265.10 mm³. Its distance from MBL is 2.31 mm. In Fig. 3a coronal CT slice showed concha bullosa (arrow) and Fig. 3b showed paradoxical concha(arrow).

Haller cells are the cells which grow in bony orbital floor constitute the roof of maxillary sinus. Zinreich et al⁽¹⁵⁾ and Kennedy et al⁽¹⁶⁾ described haller cells as ethmoid air cells inferior to ethmoid bulla adhering to roof of maxillary sinus in continuity with the proximal infundibulum. They are considered aethmoid cells that grow into floor of orbit and may narrow the ostium of the maxillary sinus especially if they become infected (Llyod et al).⁽¹⁷⁾ Table 4 shows dimensions of haller cells. It shows length, breath, height and volume of right haller cell to be 6.32 mm, 4.23mm, 4.54mm and 66.33 mm³ respectively. Distance from MBL is 10.38 mm. The length, breath, height and volume of left haller cell is 6.20mm, 4.15mm, 4.24mm and 66.22 mm³ respectively. Distance from MBL is 10.31 mm. In Fig. 4 coronal CT slice at osteomeatal complex level showed hallercells(*)

Discussion

The role of anatomical variants in the rhino sinusitis pathogenesis can be evaluated by comparison between prevalence in populations with sinusopathy and prevalence in population free from sinusal problems.

Osteomeatal complex is the final common pathway for the drainage and ventilation of frontal, maxillary and anterior ethmoidal cells. Various anatomical variants like enlarged bulla, aggernassi cells, concha bullosa and haller cells compromise this pathway leading to pathogenesis of rhinosinusitis.

In the present study, 77% patients presented with the symptom of sneezing, 58% with rhinorrhea and 37% with headache. Tonai and Baba⁽⁴⁾ showed that 76% of the study population in their study was symptomatic (having chronic sinusitis), but Bolger et al⁽¹⁸⁾ stated that 82% of study subjects were symptomatic, 18% were asymptomatic or those who were non sinus symptoms.

Concha bullosa (pneumatized middle turbinate) causes negative influence on paranasal sinus ventilation and mucociliary clearance in middle meatus region, result in development of recurrent chronic sinusitis. In our present study, conchabullosa has been found in right side in 10% study population and on left side in 6% population. In 6% cases, it was found on both sides. Total number of concha bullosa in this study was 14%, which was similar to the findings of Mamatha et al,⁽¹⁹⁾ and Lloyd⁽²⁰⁾ who found 15 and 14% of their study population having concha bullosa.

Presence of aggernasicells may obstructs the drainage pathway of frontal sinuses. In this study, we found 16% of the study population showing aggernassi cells, which is similar to the study by Riello and Boasquevisque⁽²¹⁾ and Wani et al⁽²²⁾ who findings were 13.5% and 9.33% cases.

The prevalence of haller's cells in our study was found to be 18% of study population. Similar findings were observed by Mamatha et al⁽¹⁹⁾ documented 17.5% cases in their study population.

Summary and Conclusion

According to Nassar et al⁽²³⁾ many factor are responsible for genesis of rhinosinusitis and the physiological factor (mucociliary clearance disorder) is as important as mechanical obstruction factor. Different variants of osteomeatal complex compromise the pathways of mucociliary clearance. Assessment of anatomical variants in coronal CT scan of paranasal sinus is of utmost important in surgical treatment of rhinosinusitis.

Recommendations

Study of CT scan of Paranasal sinus in coronal and axial section is very much informative for the surgical as well as medical intervention in treatment of rhinosinusitis. It further helps otolaryngologists in performing functional endoscopic sinus surgery.

References

1. Jones NS(2002) CT of the paranasal sinuses: a review of the correlation with clinical, surgical and histopathological findings. *Clin Otol.* 27(1),11-17.
2. Freitas AP and Boasquevisque EM (2008) Anatomical variants of the osteomeatal complex: tomographic findings in 200 patients. *Radiol. Bras. J.* 41(3).
3. Dua K, Chopra H, Khurana AS and Munaj M(2005) CT scan variations in chronic sinusitis. *Ind. j. Radiol. Imag.* 15(3):315-320.

4. Tonai A, Baba S. Anatomic variations of the bone in sinonasal CT. *Acta Otolaryngol Suppl* 1996;525:9-13.
5. Stammberger H and Hawke M(1993) *Essentials of endoscopic sinus surgery* 1sted. St. Louis: Mosby. pp:43.
6. Liu X, Han D, Zhou B (1998) Relationship between anatomic variants of nasal sinus and chronic sinusitis. *Zhonghua Er Bi Yan HouKeZaZhi* 33:149-152.
7. Dutra LD, Marchiori E. Tomografia computadorizada helicoidal dos seios paranasais na criança: avaliação das sinusopatias inflamatórias. *Radiol Bras* 2002;35:161-169.
8. Kronemer KA, McAlister WH. Sinusitis and its imaging in the pediatric population. *Pediatr Radiol* 1997;27:837-846.
9. Scuderi AJ, Harnsberger HR, Boyer RS. Pneumatization of paranasal sinuses: normal features of importance to the accurate interpretation of CT scans and MRI images. *AJR Am J Roentgenol* 1993; 160:1101-1104.
10. Stammberger H (1991) Functional Endoscopic sinus surgery: the Messerklinger technique. BC Decker, Philadelphia pp 10-11.
11. Laine FJ, Smoker WR (1992) The Osteomeatal unit and endoscopic surgery; anatomy, variations and imaging findings in inflammatory disease. *AJR Am J Roentgenol* 159: 849-857.
12. Issacson G (1996) Sinusitis in Childhood. *Clin North Am* 43: 1297-1318.
13. Zinreich J Imaging of inflammatory sign disease. *Otolaryngol Clin Nort Am* 1993;26:535-54.
14. Stammberger H, Kennedy DW. Bolger W (1995) Paranasal sinuses: anatomic terminology and nomenclature. *Ann Otol Rhinol Laryngol* 104: 7-16.
15. Zinreich SJ, Kennedy DW, Rosenbaum AE, Gaylor BW, Kumar AJ Stammberger H, Paranasal sinuses: CT imaging requirement for endoscopic surgery. *Radiology* 1987;163:769-75.
16. Zienrich SJ, Kennedy DW, Gayler BW. Computed tomography of nasal cavity and paranasal sinuses. An evaluation of anatomy for endoscopic sinus surgery. *Clear images.* 1988;1:2-10.
17. Llyod GA, Lund VJ Scadding GK. CT of Paranasal sinuses and functional endoscopic surgery; a critical analysis of 100 symptomatic patients. *Laryngol Otol.* 1991;105:181-185.
18. Bolger WE, Butzin CA, Parsons DS (1991) Paranasal sinus bony anatomic variations and mucosal abnormalities: CT analysis for endoscopic sinus surgery. *Laryngoscope* 101:56-64.
19. Mamatha H, Shamasundar NM, Bharathi MB, Prasanna LC (2010) Variations of Osteomeatal complex and its applied anatomy: a CT scan study. *Indian J Sci Technol* 3:904-907.
20. Llyod GA.(1990) CT of the paranasal sinuses: study of a control series in relation to endoscopic sinus surgery. *J Laryngol Otol* 104: 477-481.
21. Reillo A, Boasquevisque E. (2008) Anatomical variants of the Osteomeatal complex: tomographic findings in 200 patients. *Radiol Bras* 41(3):149-154.
22. Wani AA, Kanotra S, Lateef M, Ahmad R, Qaji SM, Ahmad S.(2009). CT scan evaluation of the anatomical variations of the osteomeatal complex. *Indian J Otolaryngol Head Neck Surg* 61:163-168.
23. Nassar FJ Anselmo-Lima WT, Santos AC. Participação das variações anatômicas do complexo ostiomeatal na gênese da rinossinusite crônica. Análises de tomografia computadorizada. *Rev Bras Otorrinolaringol* 2001;67:489-495.