

Incidence of womarian bones along lambdoid suture in Western Uttar Pradesh dried skulls

Vinay Kumar^{1,*}, Manisha Gupta²

¹Associate Professor, Dept. of Anatomy, ²Professor, Dept. of Physiology, SIMS, Hapur, Uttar Pradesh

***Corresponding Author:**

Email: drsinghal2009@rediffmail.com

Abstract

Womarian bones are small irregular bones present along the sutures of skull associated with various metabolic diseases like Rickets and are the markers for various diseases like osteogenesis imperfecta. The study was done in department of anatomy in the various medical colleges situated in north India over a period of 6 years total 217 well preserved dry human skull of unknown sex without any gross pathology or abnormality were selected for this study. Womarian bones are mostly seen along the lambdoid suture in 115 (52.99%) skull either one or two in number. Multiple Womarian bones were seen only in 2 skulls. The awareness of these bones are essential for orthopedician, radiologist, anatomists, neurosurgeon, morphologist and anthropologist as these may be mistaken for fractures of skull.

Introduction

- Sutures – Immovable joints that join skull bones together, Form boundaries between skull bones
There are four sutures in human skull:
- Coronal suture– between parietal and frontal
- Sagittal suture– between parietal bones
- Lambdoid suture – between the parietal and occipital
- Squamous suture – between the parietal and temporal
- Fontanelles – unossified areas found in the vault of neonatal skull, present at 4 angle of parietal bone. These are unpaired anterior and posterior fontanelles and paired mastoid and sphenoid fontanelles, usually ossify by 2 years of age. The Womarian bones are islands of small bones found at the sutures of the skull.⁽¹⁾ They are unnamed bones because they vary from person to person in number and shape.⁽²⁾ These bones may be defined as those accidental bones found in the skull having no regular relation to their normal ossification these are frequently occur in man.^(3,4)

Significance of Womarian Bones: Womarian bones are the associated with various metabolic diseases like Rickets, Kinky Hair Menkes Syndrome, Clidocranial Dysostosis, Hypothyroidism, Otopalatodigital Syndrome, Downs Syndrome.⁽⁵⁾ Womarian bones are the markers for various diseases and are important in the primary diagnosis of brittle bone disorder and osteogenesis imperfect.⁽⁶⁾ Pryles CV and Khan AJ reported that there is a strong the association between the prevalence of central nervous system disorder with presence of Womarian bones. He had found the occurrence of CNS disorder abnormalities with Womarian bones varies from 93%-100%.⁽⁷⁾

Factors Responsible for the Formation of Womarian bones are following

1. **Skull development and enlargement:** Jeanty and Silva SR described the number of wormian bones

increases with the capacity of the skull,⁽⁸⁾ Barberini F et al⁽⁹⁾ observed that the development of Womarian bones may reflect different stress acting on the cranial vault during late prenatal and early postnatal periods of bone development.

2. **Artificial cranial deformation:** The occurrence of Womarian bones are more in number in deformed skull and frequency increased with artificial deformed skull.⁽¹⁰⁾
3. **Genetic factors:** El-Najjar M et al also described the genetic role for the presence of Womarian bones.⁽¹¹⁾ Barberini, described. Womarian bones formation might be under the control of a number of genes and their phenotypic expression is conditioned by developmental threshold.⁽⁹⁾
4. **Metabolic disorders:** Hess⁽¹²⁾ suggested the development of Womarian bones
May result from metabolic mesodermal disorder.

Material and Method

The study was conducted in the department of anatomy in the various medical colleges situated in north India over a period of 6 years during the routine demonstration of bones. Total 217 well preserved dry human skull of unknown sex without any gross pathology or abnormality were taken for this study from the following medical colleges—

- Muzaffarnagar Medical College and Hospital, Muzaffarnagar 97
- Ramamedical College and Hospital Research Center, Kanpur 45
- Saraswathi Institute of Medical Sciences, Hapur 75

The findings were documented. The photographs of Womarian bones along lambdoid suture were taken using a camera.

Observation and Results

Two hundred and seventeen dry adult human crania with no craniofacial deformities selected for

study. All crania were studied in Frankfurt horizontal plane which was accepted as an international standard at an anthropological congress in Frankfurt. Wormian bones are mostly seen along the lambdoid suture in 115 (52.99%) skull and multiple Wormian bones along the lambdoid suture were seen only in 2 skulls (Fig. 1).

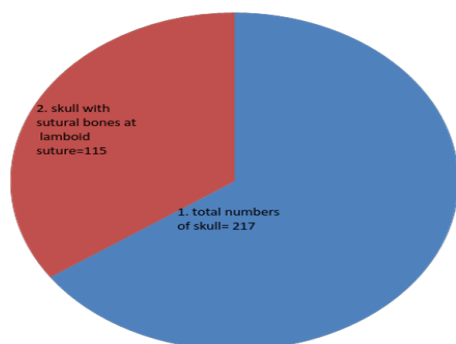
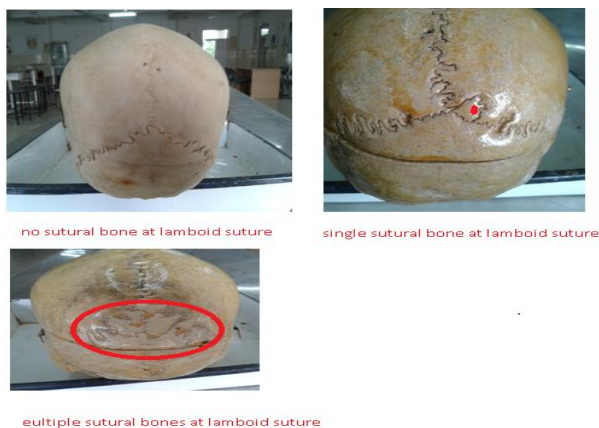

Fig. 1: Presence of Wormian bone in Lambdoid suture



Discussion

According to Bergman, Afifi and Miyauchi et al. (1988), were reported the occurrence of Wormian bones about 40% along the lambdoid suture.⁽¹³⁾ Shivaleela et al noted that 36 skull (33.33) had Wormian bones at lambdoid suture.⁽¹⁴⁾ Brasilli P et al reported an incidence of 50.55%⁽¹⁵⁾ Muralimanju et al observed the presence of Wormian bones along the lambdoid about 56.4%.⁽¹⁶⁾ In the present study, the lambdoid suture showed incidence of the Wormian bones is 52.99%. This is more than the descriptions of Bergman, Afifi and Miyauchi et al. (1988), Shivaleela et al, and Brasilli P et al and very close with the observation by Brasilli P et al but less the finding of the Muralimanju et al. Seems P V et al also reported multiple Wormian bones at the lambdoid suture in 1 skull.^(17,18) Similarly in our study we observed multiple Wormian bones at lambdoid suture only in two skulls.

Conclusion

The above study indicate the presence of Wormian bones along the lambdoid suture. The

awareness of these bones are essential as these may be mistaken for fractures of skull. The knowledge of Wormian bones at lambdoid suture is enlightening for the neuroanatomists, neurosurgeons, orthopedicians, radiologists, anthropologists and morphologists.

References

1. Standring S, Borley NR, Collins P, Crossman AR, Gatzoulis MA, Healy JC et al editors. Head and neck- External skulls. Gray's anatomy. The anatomical basis of clinical practice. 40th ed. Edinburgh: Elsevier Churchill-Livingstone; 2008. p. 409-415.
2. Nayak SB. Multiple Wormian bones at the lambdoid suture in an Indian skull. Neuroanatomy 2008;7:52-53.
3. Fabrizio B, Emiliano B, Robert C, Gianfranco F et al. Surg Radio Anat 2008;30:683-687.
4. Srivastava H C. J Anat 1992;180:219-224.
5. Wormian bones. Differential diagnosis. #6, The Radiology blog, Published April 27;2012.
6. Glorieux FH, Osteogenesis Imperfecta, Best Practice & Research Clinical Rheumatology. 22:1, pp.85-100. 2008.
7. Pryles CV, Khan AJ. Wormian bones. A marker of CNS abnormality? Am J Dis Child 1979;133:380-382.
8. Jeanty P, Silva SR, Turner C. Prenatal diagnosis of wormian bones. J Ultrasound Med 2000;19:863-869.
9. Barberini F, Bruner E, Cartolari R, Franchitto G Heyn R, Ricci F, Manzi G. An unusually-wide human bregmatic Wormian bone: anatomy, tomographic description, and possible significance. Surg Radiol Anat 2008;30:683-687.
10. Wilczak CA, Ousley SD. Test of the relationship between sutural ossicles and cultural cranial deformation: Results from Hawikuh, New Mexico. Am J Phys Anthropol 2009;139(4):483-493.
11. El-Najjar M, Dawson GL. Am J Phys Anthropol 1977;46:155-160.
12. Hess L. Ossicula wormiana. Hum. Biol 1946;18:61-80.
13. Bergman RA, Afifi AK, Miyauchi R. Urban and Schwarzenberg, Baltimore, 1988:197-205.
14. Shivaleela C, Kumar G V, Malipatil Sb and Sandhya K, 2013:584-588.
15. Brasili P, Zaccagni L, Gualdi-Russo E. Scoring of nonmetric cranial traits: a population study. J Anat 1999;195:551-562.
16. Murlimanju BV, Prabhu LV., Ashraf CM., Kumar C Rai R. and Maheshwari C. Morphological and topographical study of Wormian bones in cadaver dry skulls. J. Morpho. Sci. 2011, Vol 28, No3, p. 176-179.
17. Seema PV, Mahajan A. Human skull with complete metopic suture and multiple sutural bones at lambdoid suture - a case report. International Journal of Anatomical Variations. 2014;7: 7-9.
18. Chambellan, V. Etude anatomique et anthropologique sur les os wormiens. Paris: Inaugural Thèse, 1883. p. 66.
19. Pal GP, Tamankar BP, Routal RV and Bhagwat SS. The ossification of the membranous part of the squamous occipital bone in man. J Anat 1984;138:259-266.