

A study of Anatomical variations in the Dry Adult Human mandible

Kasat PA^{1,*}, Shyamkishore K², Bhuiyan PS³, Bhosale YJ⁴

¹Assistant Professor, Dr D. Y Patil Medical College, Nerul, Navi Mumbai, ^{2,4}Professor, ³Professor & HOD, Dept. of Anatomy, Seth G.S.M.C. and K.E.M. Hospital, Parel, Mumbai

***Corresponding Author:**

Email: payalk554@yahoo.com

Abstract

Introduction: The clinicians need to be aware of various anatomical features in the mandible to avoid confusion in the variants of anatomical features with pathology. This would also help the clinicians to avoid difficulties and complications during their surgical work.

Method: Hundred dry adult human mandibles were examined for the number of retromolar foramina and fossae, condylar defects, accessory mandibular foramen, deep mylohyoid grooves, torus mandibularis, wide and shallow mandibular notch and additional sockets for teeth.

Results: Retromolar foramen was found in 12 right sides and 7 left sides. Retromolar fossae were found bilaterally in 5 mandibles. Condylar defects were observed in three mandibles. Accessory mandibular foramen was found in three right and two left sides. Deep mylohyoid groove was observed in three mandibles. Torus mandibularis was observed in one of them. The curved length of the mandibular notch ranged from 30–54mm with a mean of 39.0±4.57mm on the right side and on the left side ranged from 31–56mm with a mean of 39.6±4.12mm. The anteroposterior length of the mandibular ramus ranged from 25–50mm with a mean of 37.8±3.83mm on the right side and on the left side ranged from 28–48mm with a mean of 38.4±3.84mm. The mandibular notch was found to be wide and shallow in four mandibles. An additional socket of teeth was noted unilaterally in two mandibles.

Conclusions: The morphologic variations of the dry adult mandible are clinically important for dental surgeons, head & neck oncosurgeons and anesthetists.

Keywords: Retromolar foramina, Condylar defects, Accessory mandibular foramen, Torus mandibularis, Additional incisor teeth

Introduction

The facial appearance is the result of the size and position of its various bones and the investing soft tissue. The mandible plays a special role in this appearance. The mandible is the largest, lowest and strongest bone of the face.⁽¹⁾ This is the only bone in the skull that is capable of separate movement with the exception of tympanic ossicles. It is of special importance not only for chewing and speech but also in the aesthetic appreciation of the face and its expressiveness.

There are many anatomical features in the mandible which the clinicians should be aware of, in order to avoid confusion of anatomical variants with pathology. This knowledge of unprecedented variations of normal anatomy may also help the clinicians to avoid difficulties and complications during the surgical work.⁽²⁾

The retromolar foramen is an inconstant foramen. It is situated in the central portion of retromolar fossa. This fossa is bounded by the temporal crest and the anterior border of ramus of the mandible. When present it conveys nerve fibers, arterioles and venules through a retromolar canal from the mandibular canal. The neurovascular bundle supplies temporalis, buccinator and the soft tissues of the retromolar region. Some branches supply the distal root of the third molar tooth.⁽³⁾ These are given off within the body of the mandible. During the extraction of the lower wisdom tooth, the dentists need to be aware of a relatively high occurrence of retromolar foramina. This would avoid complications.

Hence, our findings, in the Indian population, on the occurrence of retromolar foramen have been reported.

Mandibular condyle considerably varies both in size and shape. The condyle is roughly ovoid in outline when viewed from above. It is 15 to 20mm transversely and 8 to 10mm anteroposteriorly. The normal condylar head has a convex configuration throughout. Also, symmetry should exist in the same individual between contralateral sides. The condyles are covered by a smooth continuous layer of fibrocartilage. There are both systemic and local conditions which are known to produce defects in this layer. These lesions can be identified in skeletal material.⁽²⁾

The conventional inferior alveolar nerve block is used to achieve local anesthesia for mandibular restorative and surgical procedures such as the sagittal split ramus osteotomy, inverted L osteotomy, vertical ramus osteotomy, mandibular trauma management, orthognathic surgery, eradication of benign and malignant lesions and preprosthetic surgery. It depends on the accurate placement of local anesthetic fluid in the pterygomandibular space. Its success depends on placing the needle tip in close proximity to the mandibular foramen. However, failure rates of 10–39% have been reported. Anatomical variability could be one cause of local anesthetic failure. This may include bone and nerve variations. Hence, identification of accessory mandibular foramen and accurate anatomical location of mandibular foramen is essential.⁽⁴⁾

The teeth that are present in addition to the normal series of teeth, in both the deciduous and permanent dentition, are called supernumerary teeth. They may appear as a single tooth or multiple teeth on one side of the arch or bilaterally. It can be completely erupted or impacted in the maxilla or mandible or in both the jaws. They develop as an offshoot of the third tooth bud arising from the dental lamina or from splitting of the bud. They can be present in any region in the oral cavity. Clinicians should be aware of the various types of additional teeth (supernumery) and make a treatment plan after thorough clinical and radiographic examination. ⁽⁵⁾

So, this study was undertaken to provide information on variations in mandibles. Its results will no doubt furnish a reference for dentists in clinical practices and for surgeons.

Aim

To study the variations in the dry adult human mandibles

Objectives

The objectives of the study were:

1. To observe the number of retromolar foramina and note the presence of retromolar fossae
2. To observe incidence of condylar defects
3. To note for the occurrence of accessory mandibular foramen
4. To observe for the presence of mylohyoid groove
5. To measure the length of curvature of the mandibular notch
6. To measure the width of the ramus of mandible
7. To note for additional sockets of teeth

Materials and Methods

The study included 100 dry human mandibles of undetermined age and gender (as they were not recorded at the time of acquisition) procured from the Department of Anatomy, of a teaching medical institution from Western India. They were kept free from any dust, moth or insect. Each mandible was assigned a serial number. The study was approved by the Institutional Ethics Committee. The results obtained were recorded and tabulated. The different parameters recorded were:

1. The number of retromolar foramina and presence of retromolar fossae (Fig. 1)
2. Condylar defects (Fig. 2)
3. Accessory mandibular foramen (Fig. 3a)
4. Mylohyoid groove (Fig. 3b and 4a)
5. Length of curvature of mandibular notch was measured using thread and scale.
6. Width of the mandibular ramus was measured along line the AB which passes through most superior part of lingula and perpendicular to the posterior ascending mandibular rim. Variations in its width were noted as depicted in Fig. 4b and 4c.
7. Additional sockets of teeth (Fig.5)

The length of curvature of mandibular notch and the width of the mandibular ramus was measured to the nearest of 0.5 mm with a scale. The data was statistically analyzed for the purpose of comparison and correlation by calculating the mean, range and standard deviation.

Mean (A) was calculated by the following formula –

$$\bar{x} = \frac{1}{n} \cdot \sum_{i=1}^n x_i$$

where,

\bar{x} = mean

n = number of mandibles

x_i = each value in data

Standard Deviation was calculated by the following formula –

$$SD = \sqrt{\frac{1}{n} \cdot \sum_{i=1}^n (x_i - \bar{x})^2}$$

where,

SD = standard deviation

n = number of mandibles in the set

x_i = each value in data

\bar{x} = mean of all values in data

Student's paired t-test with two-tailed distribution was applied for comparison of right and left values of different parameters. p-value < 0.05 was considered as statistically significant. Spreadsheets were used to tabulate values.

Inclusion Criteria: All the mandibles available during the study period

Exclusion Criteria: Damaged bones, bones of paediatric age group and bones affected by pathology

Results

1. **Retromolar foramen and fossa (Fig. 1 and Fig. 6):** Retromolar foramen was found in 12 right sides and 7 left sides. They were bilaterally present in 7 mandibles (3.5%) and unilateral in 5 mandibles (2.5%).

Retromolar fossae were found bilaterally in 5 mandibles. Of these, in 3 mandibles retromolar foramen were also present bilaterally. Retromolar fossae were found unilaterally in 2 mandibles, both on the right sides.

2. **Condylar defects (Fig. 2):** Condylar defects were observed in three mandibles.

In one of them, there were grooves present posterolaterally, just inferior to the condyles of both sides. It was observed that the mandibular condylar articular surface dipped down sideward along the anterior aspect on the left side. The everted angle of mandible was seen bilaterally (**Fig. 2a**).

In another mandible, the long axis of the condyle on the right side was directed transversely and the left condyle showed convex posterior enlargement (**Fig. 2b**).

3. **Accessory mandibular foramen (Fig. 3a):** Accessory mandibular foramen was found in three right sides and two left sides. They were bilaterally present in one mandible which also had presence of bilateral retromolar foramen. All accessory mandibular foramina were located above the mandibular foramina, on the medial aspect of the mandibular ramus.
4. **Mylohyoid groove (Fig. 3b and 4a):** Deep mylohyoid groove was observed in three mandibles (Fig. 3b). Bony projection over the left mylohyoid groove (torus mandibularis) was observed in one of these mandibles (Fig. 4a). This mandible also had deepened submandibular fossae bilaterally.
5. **Length of curvature of mandibular notch (Table 1):** The length of the curvature of the mandibular notch on the right side ranged from 30–54mm with a mean of 39.0 ± 4.57 mm and on the left side ranged from 31–56mm with a mean of 39.6 ± 4.12 mm. There was statistically significant difference between right and left values of length of curvature of mandibular notch. p-value was 0.042 (p-value < 0.05).
6. **Width of ramus of mandible (Table 2):** The distance along the line AB from anterior border of ramus to posterior border of ramus on the right side ranged from 25–50mm with a mean of 37.8 ± 3.83 mm and on the left side ranged from 28–48mm with a mean of 38.4 ± 3.84 mm. There was

statistically significant difference between right and left values of AB. p-value was 0.014 (p-value < 0.05).

The mandibular notch was found to be wide and shallow in four mandibles (Fig. 4b and 4c). The mandibular notch on right side of one of these mandibles was angulated. The angulation was 45° (Fig. 4c). The typical curvature of mandibular notch was absent. This mandible also showed bilaterally square shaped ramus.

7. **Additional sockets of teeth (Fig. 5):** Additional incisor socket was noted unilaterally in two mandibles.

Table 1: Length of the curvature of the mandibular notch

Side	Number	Mean (in mm)	Standard Deviation	Range (in mm)
Right	100	39.0	4.57	30–54
Left	100	39.6	4.12	31–56

Table 2: Width of the ramus of mandible

Side	Number	Mean (in mm)	Standard Deviation	Range (in mm)
Right	100	37.8	3.83	25–50
Left	100	38.4	3.84	28–48

Table 3: Comparison of number of retromolar foramen

Study	Year	Country	Sample size	Retromolar foramen
Schejtman et al. ⁽⁶⁾	1967	Italy	86	7 (8.1%)
		Argentina	18	13 (72%)
Azaz & Lustmann ⁽³⁾	1973	Israel	125	21 (16.8%)
Ossenberg ⁽⁶⁾	1987	Japan	94	3 (3.2%)
Sawyer & Kiely ⁽¹⁸⁾	1991	US	234	18 (7.7%)
Kodera & Hashimoto ⁽⁶⁾	1995	Japan	41	8 (20%)
Pyle et al. ⁽⁶⁾	1999	(Caucasian) (Afro -American)	475	37 (7.8%)
Narayana ⁽⁶⁾	2002	India	242	53 (21.9%)
Priya & Manjunath ⁽⁶⁾	2005	India	157	20 (12.7%)
Lagrana et al. ⁽⁶⁾	2006	Argentina	50	9 (18%)
Bilecenoglu & Tuncer ⁽⁶⁾	2006	Turkey	40	10 (25%)
Suazo et al. ⁽⁶⁾	2008	Brazil	294	38 (12.9%)
von Arx et al. ⁽⁶⁾	2011	Switzerland	121	31 (25.6%)
Kawai et al. ⁽⁶⁾	2012	Japan	46	24 (52%)
Rossi et al. ⁽⁶⁾	2012	Brazil	222	59 (26.6%)
Lizio et al. ⁽⁶⁾	2013	Italy	233 (hemi mandibles)	34 (14.6%)
Athavale et al. ⁽⁶⁾	2013	India	71	10 (14.1%)
Orhan et al. ⁽⁶⁾	2013	Turkey	126	14 (11.1%)
Potu et al. ⁽⁶⁾	2014	India	94	11 (11.7%)
Present Study		India	100	19 (9.5%)

Table 4: Occurrences of torus mandibularis

Sample	Males (%)	Females (%)
Poundbury ⁽¹⁹⁾	16.3	10.9
Cannington ⁽²⁰⁾	11.0	15.0
Ukranian ⁽¹³⁾	0.0	1.5
Lapps ⁽²¹⁾	26.8	38.8
North American Whites ⁽²²⁾	6.5	8.1
Eskimo ⁽¹³⁾	58.1	35.2
Canadian Eskimo ⁽¹³⁾	85.3	80.0
Aleuts ⁽¹³⁾	71.7	75.9
Brazilian Indians ⁽²³⁾	0.5	0.5
Blacks ⁽²²⁾	6.1	6.2
Japanese ⁽¹³⁾	26.7	33.3
Ainu ⁽¹³⁾	44.3	21.1
Igloolik Eskimo ⁽¹²⁾	38.7	40.8
Hall Beach Eskimo ⁽¹²⁾	41.5	32.1
Norwegian ⁽¹¹⁾	6.36	8.53
Present Study (Indian)	1.0 (gender not considered)	

Table 5: Comparison of width of ramus of mandible

Study	Year	Country	Sample size	Width of ramus of mandible (in mm)	
				R	L
Oguz & Bozkir ⁽¹⁴⁾	2002	Turkey	34	30.99	31.15
Aksu et al. ⁽¹⁵⁾	2007	Turkey	102	27.23	27.36
Kositbowornchai et al. ⁽¹⁶⁾	2007	Thailand	72	36.10 a*	41.07 b**
Present Study		India	100	37.83	38.46

where,

a* Dry bones, b** Panoramic radiographs, R-Right, L-Left

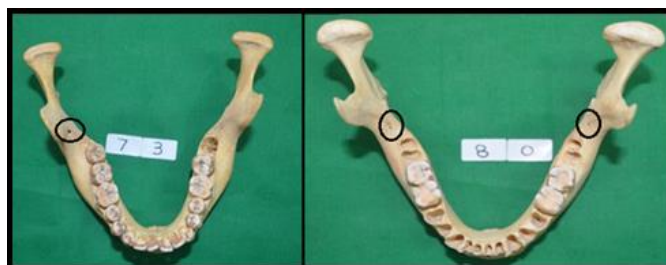

Fig. 1: Illustration showing unilateral (right side) and bilateral retromolar foramina (encircled)

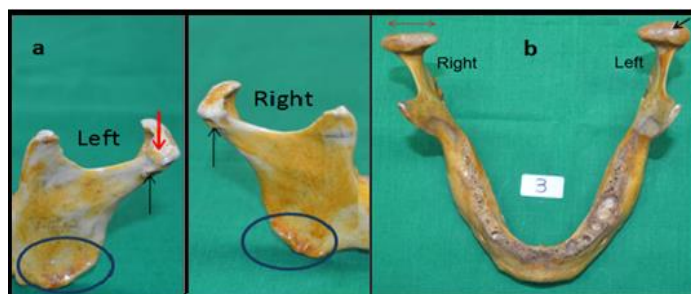


Fig. 2: Illustration showing condylar defects (a) Bilaterally there are grooves present posterolaterally, just inferior to the condyles (black arrow). The articular surface of the condyle dips down along the anterolateral aspect on the left side (red thick arrow). The everted mandibular angle, present bilaterally, is also seen (encircled). (b) The long axis of the condyle on the right side is directed transversely (two headed red arrow) and the left condyle shows convex posterior enlargement (black arrow)

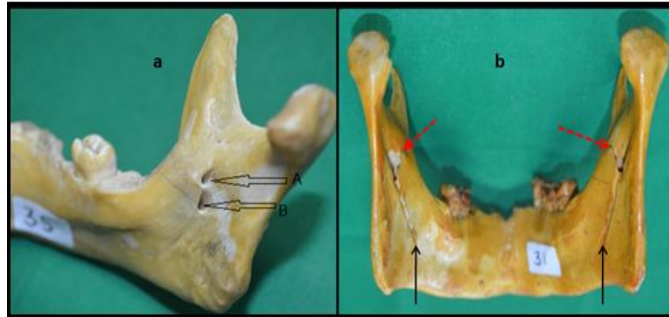


Fig. 3: Illustration showing (a) accessory mandibular foramen (where, A is accessory mandibular foramen and B is typical mandibular foramen) and (b) bilaterally deep mylohyoid groove (black arrows) and prominent lingulae (red dotted arrows)

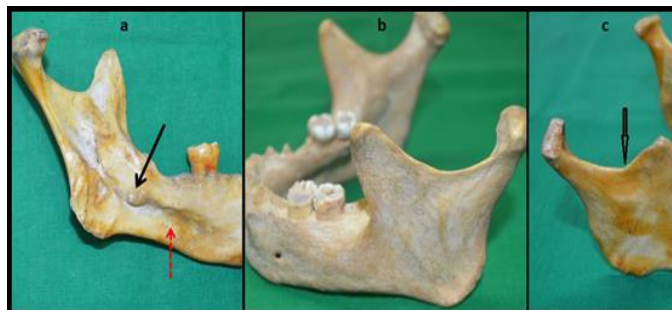


Fig. 4: Illustration showing (a) bony projection over the left mylohyoid groove or torus mandibularis (black thick arrow) with deepened submandibular fossa (red dotted arrow), (b) bilaterally square shaped ramus of the mandible with wide and shallow mandibular notch, and (c) angulated mandibular notch (arrowhead)

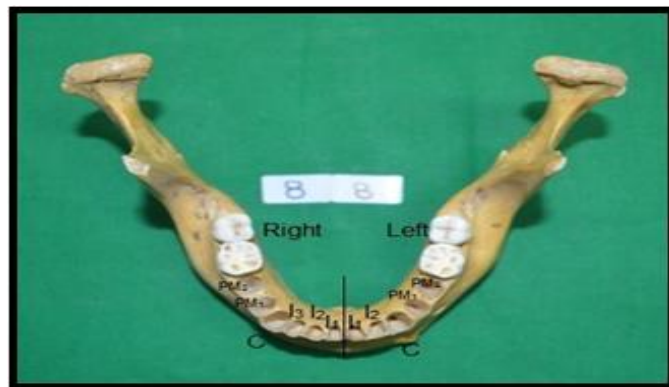


Fig. 5: Illustration showing additional alveolar socket for the incisor tooth present on the right side (I₃)

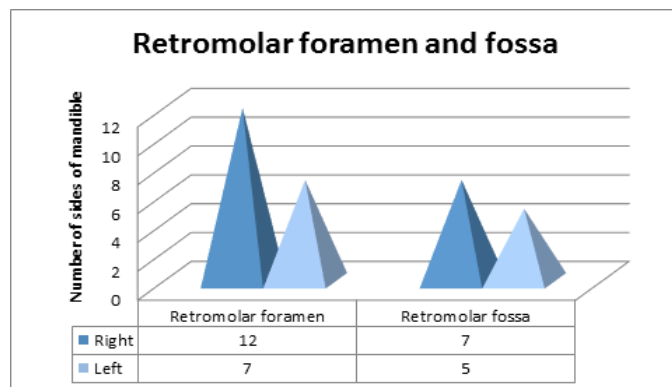


Fig. 6: Illustration showing frequency of occurrence of retromolar foramina and fossae

Discussion

1. Number of retromolar foramina (Table 3): When compared with previous studies, it is observed that retromolar foramen is commonly found with varying incidence between 3.2% and 72%. The differential origins of the population could be related to this discrepancy in frequency. The neurovascular bundle of the retromolar foramen has been observed to originate in the mandibular canal. It then penetrates into distal lamina dura of the third molar distal root. Potu *et al.*⁽⁶⁾ findings show that the distance between the retromolar foramen and third molar was within 4–11mm short range. During the third molar extraction, this close relation of retromolar foramen with third molar could lead to damage of the structures traversing through it. Also it could be a reason for postoperative hematomas due to rupturing of the vessels in retromolar foramen.⁽⁶⁾ These complications in patients with retromolar canals can be avoided by crushing the bone in the area occupied by the canal or filling the opening with bone wax.⁽³⁾

In 1974, Sutton first reported the presence of retromolar foramen with additional sensory nerve fibers. He related the failure of obtaining analgesia using classical anesthetic techniques to the presence of this foramen. In order to obtain complete anesthesia in such individuals, supplementary infiltration of local anesthetic solution into the soft tissues overlying the retromolar fossa is required. Thus, the studies of the retromolar foramen are important to avoid failure in regional anesthetic techniques for blocking the inferior alveolar nerve and buccal nerve fibers.

Pinsolle *et al.* mentioned that retromolar foramen has blood vessels. This could be reason of hematogenous spread of infection and metastasis of cancers. Keeping these observations and measurements in mind, one should be cautious when performing the following dental surgeries. This includes sagittal split osteotomies of the mandible, third molar extraction, flap lifting, diresis procedures, and placement of osseo-integrated implants.

2. Condylar defects: Jaffar *et al.*⁽²⁾ found condylar defects in 10% of mandibles studied and Azaz & Lustmann⁽³⁾ found in 12.4% of the mandibles. In our study, we found it in 3%. Although degenerative diseases contribute to these defects, they may be of dental origin such as malocclusion.

The articular surface of the mandibular condyle is tilted forward at approximately 25° to the occlusal plane and is slightly curved. Its shape varies from roughly horizontal in the edentulous to that of a gable in the coronal plane. The jaw joint is a weight-bearing joint. The commonest site of mandibular fractures is the condyle. The right condyle must support a load of over 300 N, with a vertical bite

force of 500 N on the left first molar (Osborn, 1995).⁽⁷⁾ The condyle on the working side is less loaded than the non-working condyle. This explains why the chosen site of biting is on the side of fractured condyle.⁽¹⁾

In 1961, Yale *et al.* reported about the different shapes of mandibular condyle for the first time. Initially Yale classified condylar head based on superior view into three categories namely concave, convex and flat. However later on, he simplified it into four categories namely convex, flattened, angled and rounded.⁽⁸⁾

In 1987, Tadej, Engstrom, Borrmann & Christian did a study on mandibular condyle morphology in relation to malocclusion in children. This study revealed that the condylar size in males was greater than in females. They also found that midline discrepancy significantly altered the increase in condylar size during growth.⁽⁸⁾

In 1994, Juniper evaluated shape of the condyles by surgical exposure of temporomandibular joint. This revealed that most condyles had a normal size and shape. Other varieties like excavated form, small round condyles, oblique shape and flattened condyles were also noted.⁽⁸⁾

In 2002, Neville, Damm, Allen & Bouquet revealed that anomalies in the size and shape of the condyle could be due to developmental disturbances involving the temporomandibular joint. On radiographic examination of the joint, agenesis, hyperplasia, hypoplasia and formation of a bifid condyle may be evident. Local factors, such as trauma or infection, can initiate condylar growth disturbances.⁽⁸⁾

In 2003, Ueda, Yonetsu, Ohki, Yamada, Kitamori *et al.* used high resolution CT images to classify condylar morphology as flat, round, angled, convex and concave. Convex type was observed very frequently. This was followed by angled, concave and round. In men concave type was observed predominantly, whereas in women convex type.⁽⁸⁾

In 2005, Katsavrias & Halazonetis showed that the condylar head was inclined in relation to variable shape of the condyle and inclination of the eminence and fossa height was related to variable shape of the fossa. During growth, major change in condylar size was noticed in mediolateral dimension than antero-posterior.⁽⁸⁾

In 2013, Hegde, Praveen & Shetty concluded that morphologic changes of condyle occur due to various diseases, remodeling, developmental variations, trauma, endocrine disturbances and radiation therapy. Genetic, acquired, functional factors and individuals age groups also play a role in morphologic changes of condyle. In diagnosing

temporomandibular joint diseases, the varying shapes and size of condyles is important.⁽⁸⁾

3. Accessory mandibular foramen: Accessory mandibular foramina were observed on 2.5% of the sides of mandible in the present study. It was identified since the probe did not pass through this foramen into the mandibular canal. The probe passed easily through the main foramen to the mandibular canal and emerged throughout. Choi & Han found duplication of mandibular foramina which lead to the accessory canals in 1.35% of population.⁽⁹⁾ Surgeons operating on mandibles need to know of these variations.

4. Torus mandibularis (Table 4): It is recognized as a series of bony nodules or bony ridge or lumps appearing on the lingual surface of the alveolar margin of the mandible. It is generally present in the premolar region (Hauser & DeStefano, 1989).⁽¹⁰⁾ Mandibular tori are not associated with any pathological condition. It can be easily distinguished from instances where osteological activity is the result of a pathological condition causing abnormal growth, such as trauma or tumor. It is generally manifested bilaterally, though it may be present just on one side of the mandible. There is often a degree of asymmetry between sides. The right side most commonly presents a more pronounced torus than the left side (Haugen, 1990; Seah, 1995).⁽¹¹⁾

Mayhall et al (1970) and Berry (1975) also found torus mandibularis.^(1,12) It is found in different frequencies among human populations. It is recorded during archeological assessment of skeletal remains. Since a clear pattern of genetic inheritance is lacking, mechanical stresses of the masticatory mechanism is probably responsible for this osteological response.⁽¹³⁾

5. Length of curvature of mandibular notch: The length of the curvature of the mandibular notch on the right side ranged from 30–54mm with a mean of 39.0±4.57mm and on the left side ranged from 31–56mm with a mean of 39.6±4.12mm. There was no comparative study available in the literature reviewed. Hence, our findings can be used for comparison with the values in future studies measuring length of the curvature of the mandibular notch.

6. Width of ramus of mandible: From Table 5, it is evident that the findings of Oguz & Bozkir⁽¹⁴⁾ and Aksu et al.,⁽¹⁵⁾ both from Turkey are similar. Our findings and the findings of Kositbowornchai et al, which they obtained by the panoramic radiographic study, is similar.⁽¹⁶⁾ In a study by Pillai et al. it was found that the minimum breadth of the ramus ranged from 23-36mm with a mean of 30.5mm while the maximum breadth of ramus ranged from 28-47mm with a mean of 39mm.⁽¹⁷⁾

7. Additional incisor socket: Excess in tooth number is called hyperdontia (supernumerary teeth). These could be due to disturbances in initial stages of the developing tooth. Most of the additional teeth are isolated incidents. Some occur due to syndromes like cleidocranial dysplasia. Additional tooth in permanent dentition follows additional tooth in deciduous dentition in 33% of cases. Reports in incidence of supernumerary teeth are as high as 3%. The permanent dentition is affected five times more frequently than the primary dentition. Males are affected twice as frequently as females.

Supernumerary teeth will occur 10 times more often in the maxillary arch than the mandibular arch. Approximately 90% of all single tooth supernumerary teeth are found in the maxillary arch. There is a strong predilection to the anterior region. Complications of supernumerary teeth can include delayed and/or lack of eruption of the permanent tooth, resorption of adjacent teeth, crowding, pericoronal space ossification, dentigerous cyst formation and crown resorption. The patient usually complains of food lodgment. Early diagnosis and appropriately timed treatment are important in the avoidance and prevention of these complications.⁽¹²⁾

Conclusions

In conclusion, the present analysis revealed variations in number of retromolar foramina and fossae, condylar defects, accessory mandibular foramen, deep mylohyoid grooves, torus mandibularis, wide and shallow mandibular notch and additional incisor teeth.

Conflicts of Interest

The authors have none to declare.

Acknowledgements

The authors wish to convey their sincere thanks to the Dean, Seth G. S. Medical College and K.E.M. Hospital, Mumbai and all staff members from the Department of Anatomy, Seth G. S. Medical College, Mumbai. Authors also acknowledge the immense help received from the scholars whose articles are cited and included in references of this manuscript.

References

- Collins P. Infratemporal and Pterygopalatine Fossae and Temporomandibular Joint. Standring S, editor. Gray's Anatomy: the Anatomical Basis of Clinical Practice. 40th edition. New York: Elsevier Churchill Livingstone; 2008: 527–560.
- Jaffar AA, Al-Zubaidi AF, Al-Salihi AR. Anatomical Features of Clinical Significance in Dry Mandibles. Iraqi Dental Journal. 2002; 29: 99–118.
- Azaz B, Lustmann J. Anatomical Configurations in Dry Mandibles. Br. J. Oral Surg. 1973; 2: 1–9.
- Cvetko E. Bilateral Anomalous High Position of the Mandibular Foramen: a Case Report. Surg Radiol Anat Journal. 2014; 36: 613–616.

5. Regezi J, Sciubba J, Jordan R. Abnormalities of Teeth. In: Oral Pathology: Clinical-Pathologic Correlations, 5th ed. St. Louis, MO: Saunders Elsevier; 2008: 361–376.
6. Potu BK, Kumar V, Salem AH, Abu-Hijleh M. Occurrence of the Retromolar Foramen in Dry Mandibles of South-Eastern Part of India: A Morphological Study with Review of the Literature. *Anatomy Research International*. 2014; 2014: 1–5.
7. Osborn JW. Internal Derangement and the Accessory Ligaments around the Temporomandibular Joint. *J Oral Rehab*. 1995; 22: 731–740.
8. Hegde S, Praveen BN, Shetty SR. Morphological and Radiological Variations of Mandibular Condyles in Health and Diseases: A Systematic Review. *Dentistry*. 2013; 3(1): 154.
9. Choi YY, Han SS. Double Mandibular Foramen Leading to the Accessory Canal on the Mandibular Ramus. *Surg Radiol Anat Journal*. 2014; 36: 851–855.
10. Hauser G, De Stefano GF. Epigenetic variants of the human skull. Stuttgart: E. Schweizerbart'sche Verlagsbuchhandlung (Nägele u. Obermiller). 1989.
11. Haugen LK. The tori of the human jaw skeleton. *Antropologiskeskrifter nr. 4*. Oslo: Anatomisk Institute, Universitetet i Oslo. 1990.
12. Mayhall JT, Mayhall MF. Torus mandibularis in two Northwest Territories Villages. *Am J Phys Anthropol*. 1971; 34:143–148.
13. Hassett B. Torus Mandibularis: Etiology and Bioarcheological utility. *Dental Anthropology*. 2006; 19(1): 1–14.
14. Oguz O, Bozkir MG. Evaluation of Location of Mandibular and Mental Foramina in Dry, Young, Adult Human Male, Dentulous Mandibles. *West Indian Med J*. 2002; 51: 14–16.
15. Aksu F, Zeybek G, Aksu E, Özcan E, Çapraz N, Alibeyoğlu AM. Localization and Morphometry of Mandibular Foramen. *Journal of the Faculty of Medicine*. 2007 Sept; 21 (3): 131–135.
16. Kositbowornchai S, Siritapetawee M, Damrongrungruang T, Khongkankong W, Chatrchaiwiwatana S, Khamanarong K, Chanthaooplee T. Shape of the Lingula and its Localization by Panoramic Radiograph Versus Dry Mandibular Measurement. *Surg Radiol Anat Journal*. 2007; 29: 689–694.
17. Pillai TJ, Devi TS, Devi CKL. Studies on Human Mandibles. *IOSR-JDMS*. 2014 Jan; 13(1): 8-15.
18. Sawyer DR, Kiely ML, Pyle MA. The Frequency of Accessory Mental Foramina in Four Ethnic Groups. *Arch Oral Biol*. 1998 May; 43(5): 417–420.
19. Farwell DE, Molleson TI. Excavations at Poundbury. The cemeteries. Dorchester: Dorset Natural History and Archaeological Society. 1993; 2: 1966–1980.
20. Brothwell DR, Powers R, Hirst SM, Wright SM, Gauthier S. The human biology. In: Rahtz P, Hirst S, Wright SM, editors. Cannington Cemetery. London: Society for the Promotion of Roman Studies. 2000; 131–256.
21. Schreiner KE. Zur Osteologie der Lappen. *Aschenhoug, Series B. XVII*. Oslo: Bd Inst Sammelign Kulturforskn. 1935; 161–177.
22. Corruccini RS. An examination of the meaning of cranial discrete traits for human skeletal biological studies. *Am J Phys Anthropol*. 1974; 40: 425–445.
23. Bernaba JM. Morphology and incidence of torus palatinus and mandibularis in Brazilian Indians. *J Dent Res*. 1977; 56: 499–501.