

## Bilateral multiple renal arteries with anomalous origin of ovarian arteries on both sides— A case report

Rajarshi Roy<sup>1,\*</sup>, Rajib Kundu<sup>2</sup>, Panchali Som<sup>3</sup>

<sup>1,3</sup>PG Student, <sup>2</sup>Associate Professor, Dept. of Anatomy, Institute of Post Graduate Medical Education & Research, Kolkata, West Bengal

**\*Corresponding Author:**

Email: rajarshi.bubai@gmail.com

### Abstract

**Introduction:** Knowledge of presence of supernumerary renal arteries with anomalous origin of gonadal arteries are important with increased use of laparoscopic renal surgeries and donor nephrectomy. Transplantation of kidney may be jeopardized with aberrant renal and gonadal arteries. Therefore this case report will help surgeons to understand the possible abnormalities which are very important clinically.

**Methods:** During routine dissection of abdomen of an embalmed female cadaver of about 70years of age, the renal and gonadal vascular abnormalities have been noted in the Dept. of Anatomy, IPGMER, Kolkata, India.

**Results:** Bilateral four renal arteries were found, in right side the ovarian artery originated from third renal artery from above and in left side from the lower most one.

In right side all the renal arteries originated from abdominal aorta separately, three arose above the superior mesenteric artery and one below. The upper three renal arteries entered through renal hilum, crossing the inferior vena cava (IVC) from behind but the fourth one entered through the lower pole after crossing the IVC anteriorly.

In left side the upper three arose from a common arterial trunk from abdominal aorta as early division of main renal artery and the fourth one originated separately from abdominal aorta. The first one entered the left kidney through upper pole while the rest through hilum.

**Conclusions:** Though the variations of renal and gonadal vessels may be silent/undiagnosed throughout the life, their presence may result in vascular injury of any additional vessels during renal /retroperitoneal surgery.

**Keywords:** Accessory Renal Artery, Anomalous Gonadal Artery, Multiple Renal Arteries.

### Introduction

The ovarian arteries are branches of the abdominal aorta (AA) and originate below the renal arteries. Each descends behind the peritoneum and at the level of pelvic brim crosses the external iliac vessels to enter the true pelvic cavity. Here the artery turns medially in the ovarian suspensory ligament and splits into a branch to the mesovarium that supplies the ovary. The ovarian vein drains in inferior vena cava on the right side and in the renal vein on the left side.

Single renal artery arises at right angle from each side of the aorta slightly below the origin of superior mesenteric artery (SMA). Each artery reaches the hilum of the kidney between the renal vein in front and pelvis of the ureter behind. In about 70% of individual there is one renal artery on each side and in 30% of individual have accessory renal artery.<sup>(1)</sup> The accessory renal artery may arise from aorta or it may arise from celiac, superior mesenteric, common iliac artery. They are the persistent embryonic lateral splanchnic arteries. In the present case report we are describing anomalous origin of both ovarian arteries and presence of multiple renal arteries on each side.

### Materials and Methods

The said abnormalities were noted during routine dissection of abdomen of an embalmed female cadaver of about 70years of age in the Department of Anatomy,

I.P.G.M.E & R, Kolkata, India during the academic session 2015-16.

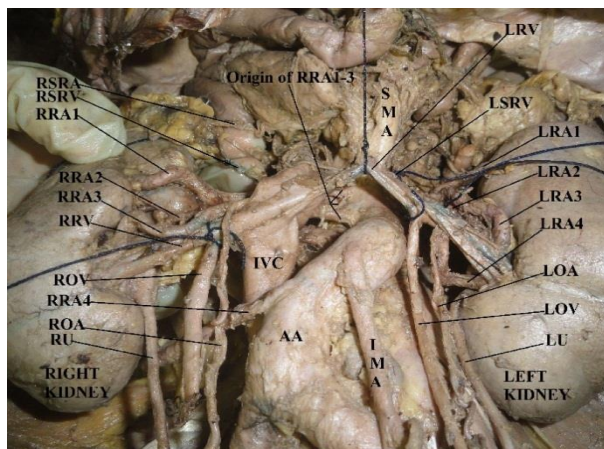
### Results

During routine dissection of posterior abdominal wall in a 70 year old embalmed female cadaver for academic session 2015-16 at IPGMER, Kolkata we have found that on the right side there were four renal arteries (RRA1-4, Fig. 1 & 2). All of them were arising from abdominal aorta separately (Fig. 1). Three of them arose below the origin of superior mesenteric artery and above the inferior mesenteric artery (IMA in Fig. 1 & 2), but the lower most originated below the origin of inferior mesenteric artery before the bifurcation of abdominal aorta. The upper three renal arteries were entering through right renal hilum. Hence, one of them was main renal artery and other two were accessory renal arteries. The right ovarian artery (ROA in Fig. 1 & 2) was arising from the right third renal artery (RRA3). The right fourth one was aberrant renal artery and was arising from abdominal aorta below inferior mesenteric artery and entering through the lower pole after crossing the inferior vena cava (IVC in Fig. 1 & 2) anteriorly. All the upper three right renal arteries crossed the inferior vena cava from behind whereas the fourth right renal artery crossed inferior vena cava anteriorly but behind the right ovarian vein (ROV in Fig. 1 & 2) & artery and right ureter (RU).

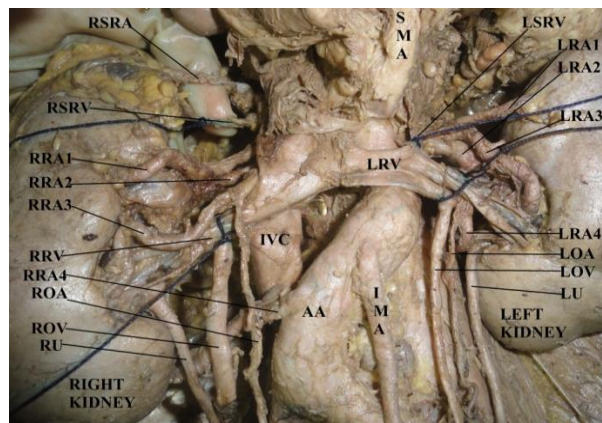
On the left side there were also four renal arteries (LRA1-4, Fig. 1 & 2). The upper three left renal arteries were arising from a common arterial trunk from abdominal aorta between the origin of superior and inferior mesenteric arteries and hence may be regarded as early division of main renal artery. The first one was entering the left kidney through upper pole. The second and third renal arteries arose from common trunk and entering into the left kidney through left hilum. The fourth one was arising from abdominal aorta below the origin of common trunk between the origin of superior and inferior mesenteric arteries and passing between two tributaries of left renal vein (LRV in Fig. 1 & 2) and entering through the left renal hilum.

The left ovarian artery (LOA in Fig. 1 & 2) was arising from the fourth renal artery. Both the right & left supra renal arteries (LSRA & RSRA in Fig. 1 & 2) were found normal in origin and number on both sides.

Both the supra renal veins (RSRV & LSRV in Fig. 1 & 2), renal (RRV & LRV in Fig. 1 & 2) and ovarian veins (ROV & LOV in Fig. 1 & 2) were found draining normally. Ureters on both the sides (RU & LU in Fig. 1 & 2) were found to be normal. The abdominal aorta after the origin of inferior mesenteric artery was found to be deviated on the right side and overridden the inferior vena cava before dividing into common iliac arteries.



**Fig. 1: Contents of posterior abdominal wall showing both the kidneys with their vascular connections and origin of right renal arteries from abdominal aorta along with other adjacent structures**



**Fig. 2: Contents of posterior abdominal wall showing both the kidneys with their vascular connections along with other adjacent structures**

### Discussion

A fare number of variations in the origin and course of renal artery have been reported previously. Variations in origin of gonadal arteries have been also reported. But this case is quite rare as this presents bilateral multiple renal arteries with bilateral variation in origin of ovarian arteries.

In 30% cases multiple renal arteries are seen unilaterally and in 10% patients it's seen bilaterally. Accessory renal arteries usually originate from the aorta or iliac arteries somewhere between the levels of T11 to the level of L4 vertebra. In extreme cases, they might origin even from the lower thoracic aorta or from lumbar or mesenteric arteries. Accessory renal arteries entering through either pole of the kidneys are usually shorter than accessory renal arteries entering through hilum of the kidneys, which are usually similar in size to a single renal artery.<sup>(2)</sup> This corroborates with our findings, where in both the sides, the polar arteries were noted to be shorter than the hilar arteries.

Singh et al. reported the presence of accessory renal arteries, one on each side, during routine dissection in an elderly female cadaver. The right accessory renal artery of passed anterior and the left one posterior to the ureters, whereas both the ovarian arteries originated from the accessory renal arteries of respective sides.<sup>(3)</sup>

It is well known that renal vessels, mainly arteries exhibit a high degree of variations. Many studies have been carried out and cases were reported about these variations. Kaneko et al. have studied 190 cadavers and described that in 2.4% cases the additional renal artery emerged below the inferior mesenteric artery in the right side and in 1.8% cases in the left side.<sup>(4)</sup>

An angiographic evaluation of 855 cases by Ozkan U et al has showed different renal artery variations. They reported multiple arteries in 24%, bilateral multiple arteries in 5% and in 8% cases early division of the renal artery were noted. In 16% cases additional renal arteries found in right side and 13% in the left

side of cases. According to the study by Ozkan U et al out of all the extra renal arteries noted, 49% were accessory where as 51% were aberrant. Though, in approximately 74% of cases renal arteries were found to be normal.<sup>(5)</sup>

Pestemalci et al reported one case of bilateral triple renal arteries.<sup>(6)</sup>

Felix et al in 1912 has discussed and explained the embryologic explanation of these arterial variations in details. He opined that in an 18 mm foetus, nine pairs of lateral mesonephric arteries arising from the dorsal aorta supplies the developing mesonephros, metanephros, suprarenal glands and gonads. These arteries were grouped into three groups, cranial (first and second), middle (third to fifth) and caudal (sixth to ninth). The renal arteries usually develop from the middle group of arteries. If more than one arteries of the middle group remains, they present as multiple renal arteries. Also, he described that the gonadal artery usually arises from the caudal group of arteries though they may arise from other groups also in some cases.<sup>(7)</sup>

In the present case, the ovarian artery on the right side originated from 3rd of the fourth renal arteries and the left ovarian artery originated from the lower most of the renal arteries. Therefore, we believe that they have been derived from the middle group as well.

There are variations in gonadal arteries with respect to their origin, number and course. They could be seen to arise from renal, suprarenal or lumbar arteries instead of usual origin from the abdominal aorta. In rare cases they may be missing also. The abnormality may be in one side or both in some cases.<sup>(8)</sup>

In a study by Pai et al, the main or accessory renal artery gave origin of gonadal artery in 8.8% of sides explored.<sup>(9)</sup>

The above findings corroborates with that of Shoja et al, who depicted that the gonadal artery originated from the main or accessory renal artery in 14% of cases and it was also observed that in 7% cases the origin of gonadal artery was from inferior polar artery, which was the most common occurrence.<sup>(10)</sup>

With the advent of the laparoscopic surgery and increased incidence of renal transplantation, clinical importance of the anatomy of accessory renal artery is gradually increasing; as during laparoscopic urological surgical procedures around the pelvi ureteric junction, anomalies of the renal arteries can lead to severe haemorrhagic complications and presence of the unnoticed accessory renal arteries can cause vascular obstructions at the established anastomotic sites.

With the increasing demand for renal transplantations, living donor grafts have now become the major source for the source of the donor pool for renal transplant. It has now become a necessity to do successful allograft with multiple arteries. In the past decade, even though being considered as a relative contraindication because of the increased risk of complications and being more complex compared to

transplantation with single renal arteries, allograft with multiple renal arteries can be implanted these days with outcome which are comparable to those with single renal arteries by various surgical techniques which may be different on case to case basis. Nevertheless, the knowledge of variations of origin of renal and gonadal vessels may greatly contribute to the success of surgical and invasive procedures like therapeutic embolisation and angioplasties. In aortic surgery dissection of Abdominal Aorta may result in vascular injury of any accessory renal vessel if not properly identified. So, Multi Detector Computer Tomography (MDCT), angiography and arteriography should be performed prior to every nephrectomy, retroperitoneal surgery to ascertain the possible anomaly/variations.

**Disclosure of potential conflicts of interest:** Nothing to declare.

**Funding:** This study was not funded by any organisation/individual. The dissection done was part of undergraduate teaching curriculum of the institute.

**Conflict of Interest:** None.

**Consent:** For this type of cadaveric study formal consent is not required.

## References

1. Standring S. 2016. Gray's Anatomy; Anatomical basis of clinical practice. 41th ed. London: Elsevier. pp 1243-1246.
2. Kadir S. 1986. Angiography of the kidneys. In: Kadir S, ed. Diagnostic angiography. Philadelphia, Saunders. 445-495.
3. Singh G, Ng YK, Bay BH. 1998. Bilateral accessory renal arteries associated with some anomalies of the ovarian arteries: a case study. Clin Anat.11:417-420.
4. Kaneko N, Kobayashi Y, Okada Y. 2008. Anatomic variations of the renal vessels pertinent to transperitoneal vascular control in the management of trauma. Surgery. 143:616-622.
5. Ozkan U, Oguzkurt L, Tercan F et al. 2006. Renal artery origins and variations: angiographic evaluation of 855 consecutive patients. Diagn Interv Radiol. 12:183-186.
6. Pestemalci T, Mavi A, Yildiz YZ, Yildirim M, Gumusburun E. 2009. Bilateral triple renal arteries. Saudi J Kidney Dis Transpl. 20:468-470.
7. Felix W. 1912. Mesonephric arteries (aa. mesonephricae). In: Kiebel F, Mall FP eds. Manual of human embryology Vol 2. Philadelphia, Lippincott. 820-825.
8. Mijac M, Goldner B, Joksimović B, Lolić-Draganić V. 1983. Variations in the origin of ovarian and testicular arteries. SrpArhCelokLek. 111:609-15.
9. Pai MM, Vadgaonkar R, Rai R et al. 2008. A cadaveric study of the testicular artery in the South Indian population. Singapore Med J. 49(7):551-5.
10. Shoja MM, Tubbs RS, Shakeri AB, Oakes WJ. 2007. Origins of the gonadal artery: Embryologic implications. Clin Anat. 20(4):428-32.doi: 10.1002/ca.20438.