

## Study of incidence of supra trochlear foramen in humerii and its surgical and orthopedic significance in Telangana region

D. NagaJyothi<sup>1,\*</sup>, S. Saritha<sup>2</sup>, N. Hima Bindu<sup>3</sup>, T. V. Ramani<sup>4</sup>, Gayatri. P<sup>5</sup>

<sup>1,4,5</sup>Assistant professor, <sup>2</sup>Professor & HOD, <sup>3</sup>Lecturer, Dept. of Anatomy, KAMS&RC, Hyderabad, Telangana

**\*Corresponding Author:**

Email: jyothidandu9@gmail.com

### Abstract

**Introduction:** The Supra trochlear aperture is situated on thin transparent bony plate which separates the Olecranon fossa and Coronoid fossa of the humerus. The Supra trochlear foramen (STF) is relatively common, seen in some humerii.

**Materials and Methods:** The current study was done in 108 dried humerii (right 45 and left 63) from the Anatomy Department, Kamineni Academy of Medical Sciences and Research Centre, Hyderabad, Gandhi Medical College, Secunderabad and Osmania Medical College, Hyderabad. The presence of STF, its different shapes and the vertical and transverse diameter were observed. In bones where the foramen was not present, translucency and opacity of Supra trochlear septum were noted.

**Results and Conclusion:** The supra trochlear foramen was seen in 34 humerii (31.4%) and 74 humerii (68.5%) were without STF. Among 74 humerii, translucency supra trochlear septum was seen in 23 (21.2%) and the rest opaque septum (normal) was seen in 51 humerii (47.2%). The supra trochlear aperture was more common on the left side about 23 in number (21.3%) than on the right side which was 11 in number (10.1%). The different shapes like oval, round and triangular were also observed and most common shape is oval.

We attempted to enlighten the knowledge of presence of Supra trochlear foramen and translucent supra trochlear septum in the dry humerii. These bony features are important for anatomists, orthopedicians and radiologists in their routine practical knowledge and interpretation in their respective areas.

**Keywords:** Supratrochlear Foramen (STF), Humerus, Coronoid Fossa, Bony Septum, Olecranon Fossa.

### Introduction

The Humerus is the upper arm bone having an upper end with head, greater tubercle and lesser tubercle. The Coronoid fossa above the Trochlea, Radial fossa above the Capitulum and Olecranon fossa present posteriorly at the lower end. The Coronoid and Olecranon fossae normally separated by a thin plate of bone upto 7 years of age. In certain bones this plate is perforated as supra trochlear foramen. Supra trochlear fractures are common among children and these variations play a crucial role in treatment of fractures.

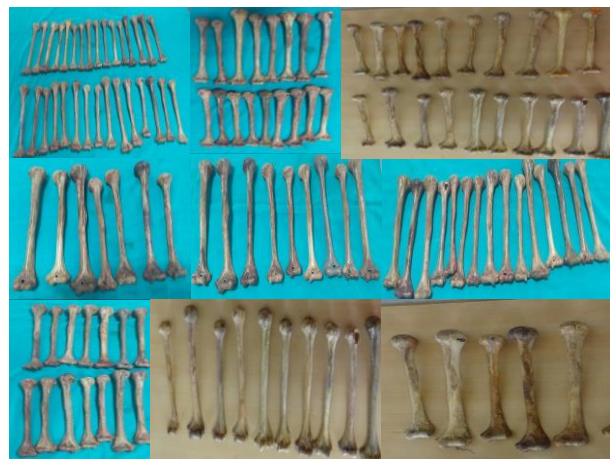Therefore anatomical importance of STF is significant in surgical and orthopedic practice.

The paper discusses the incidence, different shapes and diameters of STF of humerii and transparent supra trochlear plate between the Condylar and Olecranon fossa.

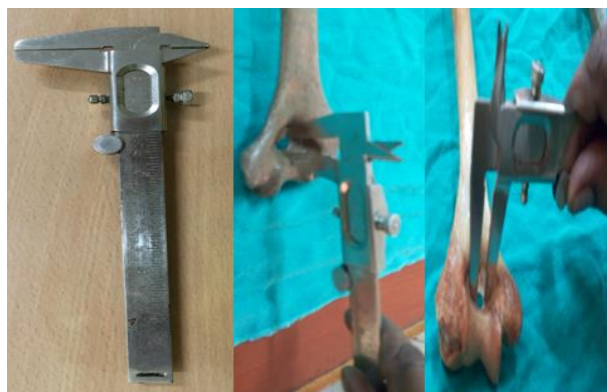### Materials and Methods

A total 108 (right 45 and left 63) adult dried human humerii of unknown origin with no pathology, obtained from the bone bank of the Department of Anatomy and Forensic Medicine; Kamineni Academy of Medical Sciences and Research Centre, Hyderabad, Gandhi Medical college, Secunderabad and Osmania Medical college, Hyderabad. The presence of STF and different shapes were noted and classified into oval, round and triangular. Its transverse and vertical diameter was measured using Digital Vernier Calipers. In bones where foramen was absent, the translucency and opacity of the supra trochlear septum were observed with the help of

transmitted light from posterior to anterior. The variations of the STF, its different shapes and diameter and translucency of supra trochlear septum were documented, tabulated and photographed.



**Fig. 1: Showing the master picture of 108 humerii**



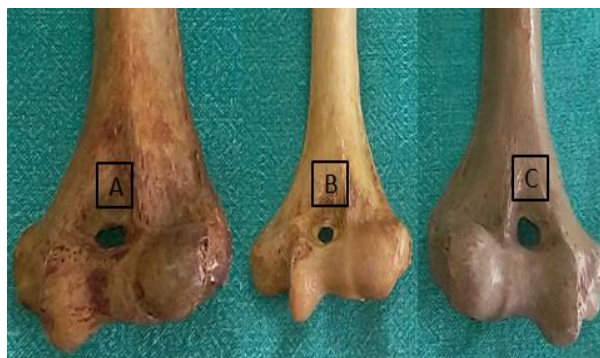**Fig 2: Measurement of vertical and transverse diameter of STF using the vernier calipers**

**Observations and Result**

**Table 1: Incidence and sidedness of STF (34 humerii) in our study of 108 (right 45 and left 63) humerii**

Right	Left	Total
Number and percentage	Number and percentage	Number and percentage
11 and 10.1%	23 and 21.3%	34 and 31.4%

Out of 108 bones studied, we observed Supra trochlear foramen in 34 humerii with incidence of 31.4%. The occurrence of supra trochlear foramen on the right side was 10.1% (11 out of 34) and on the left side was 21.3% (23 out of 34). The study shows the frequency supra trochlear foramen on left side is more common (Table 1). In 74 humerii (68.6%) the supra trochlear foramen was absent.



**Fig 3: Showing (A) Oval (B) Round (C) Triangular shape of STF from anterior aspect**

**Table 2: Incidence of different shapes of Supra trochlear foramen in 34 humerii (31.4%)**

Shape	Right(n=13)	Left (n=21)	Total(n=34)
	Number & Incidence (%)	Number & Incidence (%)	Number & Incidence (%)
Oval	7 & 53.8 %	14 & 66.6%	21 & 61.7%
Round	3 & 23%	5 & 23.8%	8 & 23.5 %
Triangle	3 & 23%	2 & 9.5%	5 & 14.7%

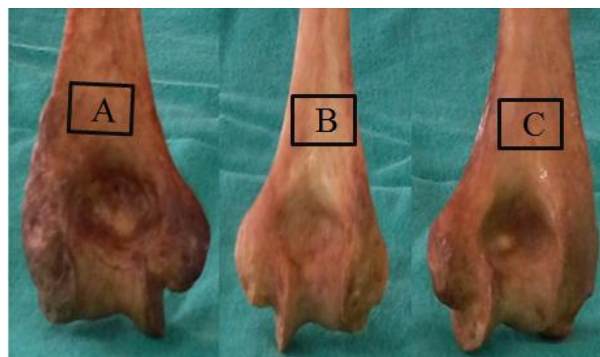
The shape of Supra trochlear foramen varies in different humerii. Three types of shapes were observed (i.e) Oval, Round and Triangular (Fig 3).Oval Supra trochlear foramen is common in our study. The STF was Oval shape in 21 humerii and percentage is about 61.7%, round shape in 8 humerii and percentage about 23.5% and triangular shape in 5 humerii, percentage about 14.7%.

3.06±0.76mm and 4.58±0.97mm respectively. Therefore in present study we noticed, that the mean transverse diameter of Supra trochlear foramen on the left side is larger.

**Table 3: Mean vertical and transverse diameter using Digital Vernier Callipers**

Side	Vertical diameter (mm)	Transverse diameter(mm)
Right	3.11±0.81	4. 43±0.84
Left	3.06±0.76	4.58±0.97

The mean vertical diameter and transverse diameter on the right side was 3.11±0.81mm and 4.43±0.84mm and mean vertical and transverse on the left side was



**Fig. 4: Photograph showing translucent supratrochlear septum (A, C) and normal opaque supratrochlear septum (B) taken in P-A view**

**Table 4: Presence of Opaque septum and thin transparent plate between Coronoid and Olecranon fossae in 74 humerii (68.5%) out of 108 humerii in our study**

Variation	Right (n=32)	Left (n=42)	Total (n=74)
	Number & percentage	Number & percentage	Number & percentage
Translucent septum	10 & 31.2%	13 & 30.9%	23 & 31%
Opaque septum	22 & 68.7%	29 & 69%	51 & 68.9%

The total translucency of septum between Coronoid and radial fossa were seen in 23 out of 74 humerii (31%), 13 on left (30.9%) and on right side 10 (31.2%). Opaque septum was seen in 51 humerii (68.9%), 29 on the left side (69%) and on the right side 22 (68.7%).

**Table 5: Frequency of supra trochlear foramen, translucency septum and opaque septum in 108 humerii**

Variations	Total Number	Incidence (%)
Supra trochlear foramen	34	31.4%
Translucency septum	23	21.2%
Opaque septum	51	47.2%

**Table 6: Number and percentage of supra trochlear foramen, translucency septum and opaque septum on Right side and left side out of 108 humerii**

Variation	Right side	Left side	Total (108 humerii)
Supra trochlear foramen	11 & 10.1%	23 and 21.3%	34 & 31.4%
Translucent septum	10 & 9.2%	13 & 12%	23 & 21.2%
Opaque septum	22 & 20.3%	29 & 26.8%	51 & 47.2%

The incidence and percentage of STF was seen in 34 humerii (31.4%), translucent septum found in 23 humerii (21.2%) and opaque septum was noted in 51 humerii (47.2%) out of 108 humerii respectively.

**Table 7: Incidence of comparative sidedness of STF in Indian population**

Population study	Right Side	Left side	Incidence (%)
Eastern Indians (Chatterjee 1968)	22	35	27.4%
Sout Indians(Singhal &Rao, 2007)	22	20	28%
Nort Indians(Singh &Singh 1972)	24	31	27.5%
NorthIndians(Rakesh Kumar etal, 2012)	20.22	28.13	24.1
Present study(2016)	11	23	31.4%

## Discussion

The STF is an anatomical variation must not be misinterpreted in injuries to the elbow. The knowledge about supratrochlear foramen may be of clinical significance to surgeons, anthropologists, osteologists and may have a Forensic importance.

The STF otherwise called as intercondylar foramen as it is located between two humeral condyles. Meckel was the first to describe the supra trochlear foramen in 1825.<sup>(2)</sup> In higher primates the perforation is more frequent than man, described by Hardlicka.<sup>(3)</sup> In different races, the incidence of STF varies from 6% to 60%.

It is not found before the age of 6 years supra trochlear foramen usually bilateral, larger on the left side and is more common in females. The higher occurrence of STF in females may be due to inward curvature of the female elbow angle was suggested by Mall.<sup>(5)</sup>

Mays suggested that the perforation is the result of hyper flexion of elbow joint which resorbs the humeral

septum when the Coronoid process of ulna make contact with it.<sup>(6)</sup>

The STF is considered as an atavistic character found frequently in primates.<sup>(3)</sup> Darwin mentioned STF in humans as one of the characteristic feature that shows man's close relationship to lower animals.<sup>(7)</sup> In Indian population the incidence is different in different regions. In North Indians it is 27.5%, in South Indians 28%, in Eastern Indians it is 27.4% and central Indians 32%. The global statistics shows in Americans the incidence of STF is 6.9%, Egyptians 7.9%, in Japanese the incidence is 18.1%.<sup>(8)</sup>

Singh and Singh observed the frequency of STF on the left side 31% and on the right side 24%.<sup>(9)</sup>

Singhal et al also noticed translucent supra trochlear septum in 66% of South Indian origin.

The present study includes Telangana population with an incidence of STF 31.4% which is lower than the findings of Singh and Singh. We also noticed supra trochlear translucent septum in 21.2% of humerii which

is lower than Singhal et al and Opaque septum in 47.2% of humerii.

In majority of humerii with supra trochlear foramen, the shape was oval (61.7%) followed by round, triangular which strengthens the previous findings of Singhal et al (82%).<sup>(4)</sup>

In current study we noted, the mean transverse diameter of STF on left side is larger than on the right side. This finding was similar to the previous reports of Ozturk A et al<sup>(10)</sup> and Senem Erdogmus et al.<sup>(11)</sup>

According to Senem Erdogmus et al, the cause of STF in the humerus may be because of an epigenetic character, mechanical pressure during hyper extension, disturbance in the calcium metabolism in adults and in child hood from excessive cancellous bone resorption and also due to impingement of coronoid and olecranon processes on the intercondylar septum.<sup>(11)</sup> The supracondylar fracture of the humerus is most common fracture seen in pediatric age group which requires a proper pinning technique for stable fixation.<sup>(12)</sup> Because of occurrence of STF in Indian population is more, needs specific focus during intra medullary nailing procedures of humerus. The presence of STF makes it more difficult to plan out proper surgical procedures. The medullary canal is narrow in the region of STF which makes the retrograde nailing more difficult and increases the chance of secondary fracture of distal end of humerus. In our study the prevalence of supra trochlear foramen is more common on left side. Our results also support previous reports.<sup>(8)</sup>

According to Hirsh (1927) the thin plate of bone between the Olecranon and Coronoid fossa is always present until the age of seven years after which the bony septum occasionally becomes absorbed to form the STF.<sup>(13)</sup>

Earlier studies have suggested that STF may be hereditary, phylogenetic trait with evolutionary significance.

## Conclusion

In cases of humeral fractures of supra trochlear foramen the orthopedicians must keep in mind the surgical potential application. This study will be helpful for surgeons, orthopedicians, radiologists and anthropologists. Prior anatomical knowledge about the presence of STF may check erroneous interpretation of X-rays by radiologists.

## References

1. A. K. Datta. Essentials of Human Anatomy (upperlimb and lower limb) 8<sup>th</sup> Ed. Current books International; 2008:12-13.
2. Meckel JH (1825) cited by Kate BR, Dubey PN. A note on the septal apertures in the humerus of central Indians. Eastern Antropologist 1970.33:105-110.
3. Hardlicka A. The humerus septal apertures. Anthropologie 1932;10:34-96.
4. Singhal S, Rao V. Supratrochlear foramen of the humerus. Anat Sci Int 2007;82:105-107.

5. Mall (1905) cited by Chatterjee KP. The incidence of perforation of Olecranonfossa in the humerus among Indians. Eastern Antropologist 1968;21:270-284.
6. Mays S. Septal aperture of the humerus in a mediaeval human skeletal population. American Journal Physical Anthropology. 2008;136:432-440.
7. Sunday OO, Olusegun OS, Oluwabunmi BM. The Supratrochlear Foramen of the Humerus: Implications for intramedullary nailing in distal Humerus. Journal of Biology, Agriculture and Healthcare. 2014;4(7):136-139.
8. Rakesh Kumar Diwan, Archana Rani, Anita Rani, Jyoti Chopra, AK Srivastava, PK Sharma, Rakesh Kumar Verma & Arvind Kumar Pankaj. Incidence of supratrochlear foramen of humerus in North Indian Population. Biomedical Research 2013;24(1):142-145.
9. Singh, Singh SP. A study of the supratrochlear foramen in the humerus of North Indians. J Anat Soc India 1972;21:52-56.
10. Ozturk A, Kutlu C, Bayraktar B, Zafer ARI, Sahinoglu K. The supra trochlear foramen in the humerus (Anatomical study) st Tp Fak. Mecmuas. 2000;63:72-6.
11. Senem Erdogmus, Munevver Guler, Serpil Eroglu and Nizami Duran. The Importance of the supratrochlear foramen of the humerus in humans. Med Sci Monit 2014;20:2643-2650.
12. Akpınar F, Aydınlioğlu A, Tosun N, Dogan A, Tunal O. A morphometric study on the humerus for intramedullary fixation. Tohoku J ExpMed.2003;199:35-42.
13. Nayak SR, Das S, Krishnamurthy A, PrabhuL V, Potu BK. Supratrochlear foramen of the humerus: An anatomico-radiological study with clinical implications. Ups J Med Sci. 2009;114:90-4.