

Analysis of the vascular pattern in the superficial palmar arch formation

Betty Anna Jose^{1,*}, Shashi Rekha M.², Surendra Babu T.³

¹Associate Professor, ²Professor, ³Tutor, Dept. of Anatomy, Vydehi Institute of Medical Sciences & Research Centre, Bangalore, Karnataka

***Corresponding Author:**

Email: bettyannacj@gmail.com

Abstract

Background: The superficial palmar arch (SPA) is the main source of arterial supply to the palm. It is an arterial arcade formed mainly by the ulnar artery and is completed by the superficial palmar branch of the radial artery or princeps pollicis artery or radialis indicis artery or median artery. The knowledge about the variations in the formation of SPA is important in reconstructive hand surgery and in radial artery grafts.

Objective: The objective of the present study is to identify the arterial patterns in the formation of superficial palmar arch and classify according to its formative tributaries.

Material and Methods: The study conducted on 69 formalin fixed hands at Vydehi Institute of Medical Sciences and Research Centre, Bangalore. The vascular pattern of superficial palmar arch was recorded and classified according to the variations.

Results: It was found that 96% of SPA were complete and 4% incomplete. Based on Coleman and Anson classification, type A arch was identified in 39%, type B in 17%, type C in 9%, type E in 31% and type G in 4%. Another finding was in 35% cases, the ulnar artery was highly tortuous in its course in the palm. A thin collateral or additional branch was found in 31% of the SPA.

Conclusion: These findings on the variations of SPA is essential in microvascular surgery and radial artery harvesting in coronary artery bypass graft procedure.

Keywords: Superficial Palmar Arch, Radial Artery, Ulnar Artery, Median Artery.

Introduction

The knowledge about the variations in the vascular pattern in different parts of the body is very much important in the field of micro vascular surgery for revascularization and tissue transplantation. One such variation with clinical and surgical implication is the arterial supply of hand. The main arterial supply of hand is by the superficial palmar arch formed by the branches of radial artery and ulnar artery. The radial artery is widely selected as an arterial bypass conduit in coronary artery bypass graft procedure. If the ulnar artery or persistent median artery is sufficient for the proper arterial supply in hand, the radial artery is a non-essential vessel and can be used in grafting. But if these two arteries are not compensating the supply of radial artery, its harvesting can induce a risk by resulting ischemia of the soft tissues in hand.⁽¹⁾

The objective of the present study is to identify the variations in the formation of superficial palmar arch (SPA) and classify according to the formative tributaries.

Materials and Methods

A total number of 69 adult hands, 27 right and 52 left ones, from embalmed human cadavers, used for routine dissection by undergraduate medical students, fixed in 10% formaldehyde solution were dissected. Two horizontal incisions were made, one at the wrist joint and another incision along the root of fingers. A vertical incision was made from the middle of the wrist to the 3rd metacarpophalangeal joint. The skin of the palm and the palmar aponeurosis was reflected. The surrounding

adipose tissue was removed to view the superficial palmar arch and its branches.

The images of the dissected hands were captured. The superficial palmar arches were studied, and the variations found were compared with previous studies.

Results

Among the 69 hands, the complete arch (Fig. 1) was observed in 66 hands (96%) and incomplete arch in 4% hands with right laterality. The right hands showed 36% of the complete arch and the remaining 64% were seen in left sided hands. The SPA were further divided into different types according to the Coleman and Anson classification. The type A arch or the classical radio ulnar arch was identified in 39%, type B formed entirely by ulnar artery in 17%, type C the mediano-ulnar arch in 9%, type E (Fig. 2) where ulnar artery anastomose with a branch from the deep arch in 31% and type G in 4%. In type G, which is an incomplete arch only ulnar artery was involved without supplying to thumb and index finger. The variations were found more commonly at the radial side of the SPA.

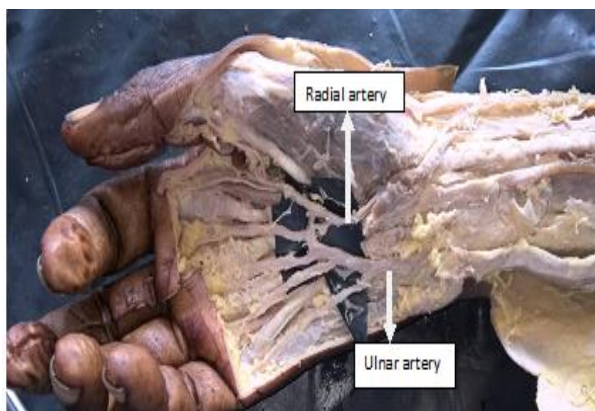


Fig. 1: Shows complete arch by the radial and ulnar arteries

Another finding was that, in 35% case, the ulnar artery was highly tortuous (Fig. 2) in its course in the palm. A thin collateral or additional branch (Fig. 2) was found in 31% of the SPA. Among the arches with supplementary branch, 50% of the hands showed tortuosity in the ulnar artery. In 9 hands, additional branch was observed, without any tortuosity in the ulnar artery. The chi-square test did not show any significant association between additional branch in the SPA and tortuous ulnar artery ($p > 0.05$).

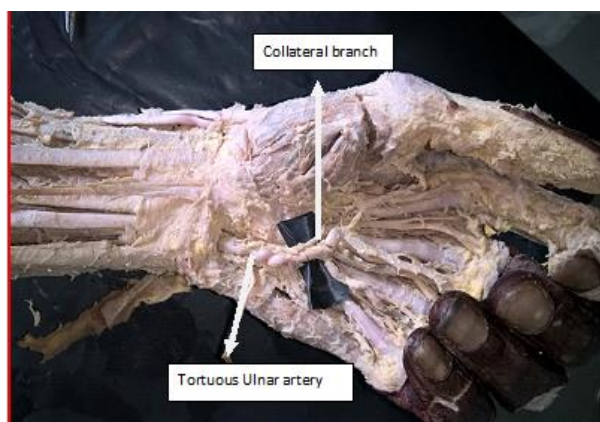


Fig. 2: Shows type E superficial palmar arch

One hand showed radio-ulnar type of SPA with equal contribution from both the arteries and two arteries are connected by a communicating branch which gives an H-shaped appearance as shown in Fig. 3. The ulnar artery showed comparatively larger diameter than its counterpart in 60 hands (87%). The radial and ulnar arteries were equal sized in 6 hands (9%) and larger radial artery was found in 3 hands (4%). These 9 hands showed classical radio-ulnar SPA or type A arches.

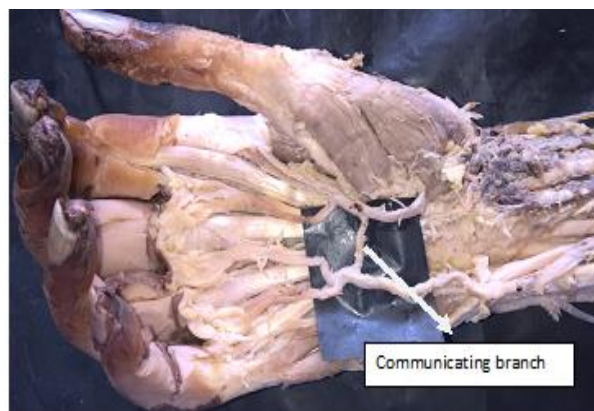

Fig. 3: Shows H-shaped Superficial palmar arch

Discussion

The SPA is an arterial arcade between radial and ulnar arteries located in the palm, deep to the palmar aponeurosis and superficial to the flexor tendons. It is formed mainly by the ulnar artery. At the other end, the arch is completed normally by anastomosing with the superficial branch of radial artery. In other subjects, the ulnar artery is anastomosing with the arteria radialis indicis, or princeps pollicis artery. Occasionally the ulnar artery anastomose with the arteria nervi mediana. In about one third of the subjects, the arch is formed only by the ulnar artery.⁽²⁾ This indicates the possible variations in SPA formation. So it is always interesting to note that which is the most commonly observed variation in each study, as it varies according to race.⁽³⁾

Many studies have been conducted to classify the variations in SPA. There are different classifications put forth in literature based on the formative vessels and its size. The most commonly used classifications are by Gelman et al,⁽⁴⁾ Adachi,⁽⁵⁾ Huber⁽⁶⁾ and Coleman and Anson.⁽⁷⁾

Gelman et al⁽⁴⁾ classified the SPA into complete or incomplete arch. If an anastomosis is present between the formative tributaries of the arch, it is considered as a complete one and in incomplete one such anastomosis is absent. The present study showed 96% complete arches and 4% incomplete arches. Our study showed a similar result of the study by Ikeda et al.⁽⁸⁾ The presence of complete arch varies from 45% to 96.4% in different population as showed in Table 1. In a study by Nasar et al.⁽⁹⁾ 91.39% complete classical arch, 4.35% ulnar type and in 4.45% SPA was absent. Patnaik et al.⁽¹⁰⁾ found double SPA in 6% of hands. The remaining 94% were single SPA with 78% complete arches and 16% incomplete arches. The current study is in accordance with the result of study by Vidya et al.⁽¹¹⁾ and Suma et al.⁽¹²⁾ The Indian studies showed high percentage of complete arches when compared to the other populations (Table 1).

Table 1: Showing the distribution of complete and incomplete arches in various studies

Study	Country	Sample size	SPA type in percentage	
			Complete arch	Incomplete arch
Coleman ⁽⁷⁾	USA	650	78.5	21.5
Ikeda ⁽⁸⁾	Japan	220	96.4	3.6
Al-Turk ⁽¹³⁾	USA	50	84	16
Loukas ⁽³⁾	USA	200	78	16
Fazan ⁽¹⁴⁾	Brazil	46	48	52
Bilge ⁽¹⁵⁾	Turkey	50	86	14
Sarkar ⁽¹⁶⁾	Singapore	42	45	55
Patnaik ⁽¹⁰⁾	India	50	78	16
Vidya ⁽¹¹⁾	India	50	92	8
Suma ⁽¹²⁾	India	20	95	5
Joshi ⁽¹⁷⁾	India	100	82	18
Present	India	69	96	4

According to Adachi, there are 3 types of SPA. Type I or ulnar arch, has minimal or no contribution from the radial artery. Type II or radio-ulnar arch has contribution from radial and ulnar arteries and type III or median-ulnar in which median artery is replacing the radial artery.⁽⁵⁾ The current study identified 17% type I, 39% type II and 9% type III superficial palmar arches.

Huber explained two types of arches. In type 1, additional branches from forearm participate in SPA or it replaces the radial artery. The type 2 is not a true arch as there is no anastomosis and each artery independently supply the digits.⁽⁶⁾ According to this classification incomplete arches and arch formed by a single artery belong to type 2 and remaining all categories are included in type 1. According to this, 79% arches of present study is included in type 1 and 21% is in type 2.

Coleman and Anson (1961) classified the superficial palmar arches mainly into group I complete arch and group II incomplete arch. Anastomosis is present in group I and is further divided into 5 types (A, B, C, D, E) based on the contributing arteries. Type A is the classical radio ulnar arch formed by superficial palmar branch of radial artery and the larger ulnar artery. Type B is formed only by ulnar artery and Type C is the median ulnar arch formed by ulnar artery and an enlarged median artery. Type D is the Radio-Median-Ulnar arch and Type E is initiated by ulnar artery and is completed by branch from deep arch. In group II, formative vessels do not anastomose and is divided into 4 types (F, G, H, I) based on the arteries. Type F in which

ulnar artery and superficial branch of radial artery takes part without anastomose, Type G only ulnar artery is involved but not supplying the thumb or index finger. Type H is the median-ulnar type without anastomosis and in type I, the radial, median and ulnar arteries give origin to superficial vessels without anastomosis.^(7,12)

As per this Coleman and Anson classification, our study showed 39% type A arch or the classical radio ulnar arch, type B in 17%, type C in 9%, type E in 31% and type G in 4%. In type G, which is an incomplete arch only ulnar artery was involved without supplying to thumb and index finger. The variations were found more commonly at the radial side of the SPA. In a study⁽¹¹⁾ of 50 hands, type A was more common (86%) and type B in 6% and found incomplete arch in 8% with type F in 6% and type H in 2% hands.⁽¹¹⁾ Loukas et al⁽³⁾ identified type A in 40 %, type B in 35%, type C in 15%, type D in 6% and type E in 4% in a study of 200 hands for anatomical variations of SPA. The variations in different studies could be due to the sample size and ethnic and gender differences.⁽³⁾ The classification of complete arches in the previous studies is shown in the Table 2. The distribution of complete arches found in the present study is in accordance with the study by Moraes et al.⁽¹⁸⁾ and Loukas et al.⁽³⁾ showed in Table 2. Ottone et al. found that the most common pattern SPA in his study was Ulnar type (44.1%).⁽¹⁹⁾ In our study, the most common pattern was radio-ulnar type (39%) and in 17% ulnar pattern was seen.

Table 2: Showing the distribution of complete arches in various studies

Study	Complete SPA Distribution in %			
	Radio-ulnar	Ulnar	Median-ulnar	Radial-median-ulnar
Ottone ⁽¹⁹⁾	43	20.9	-	-
Jaschtschinski ⁽²⁰⁾	27	38	3	0.5
Adachi ⁽⁵⁾	32	59	9%	-
Coleman and Anson ⁽⁷⁾	34.5	37	3.8	1.2

Karlsson ⁽²¹⁾	32	64	4	-
Al- Turk ⁽¹³⁾	78	-	4	2
Patnaik ⁽¹⁰⁾	76	2	-	-
Moraes ⁽¹⁸⁾	63.33	23.34	13.3%	-
Loukas ⁽³⁾	40	35	15	6.1
Joshi ⁽¹⁷⁾	30	66	4	-
Present study	39	17	9	-

In 6 hands of the current study it was found that the SPA was formed only by the superficial branch of ulnar artery and the same branch or the arch gave origin to four common palmar digital arteries. The first common palmar digital artery is divided to form the radialis indicis and princeps pollicis arteries to supply the lateral one and half fingers. The second, third and fourth common palmar digital arteries supply the medial three and half fingers. It was also noticed that in these cases of variation, the ulnar artery was tortuous while it entered the palm. The origin of first common palmar digital artery from superficial branch of ulnar artery is a rare variation. Vollala et al.⁽²²⁾ reported a similar case, but not mentioned about the tortuosity. Another case with unusual pattern of SPA was reported by Saxena et al.,⁽²³⁾ in which SPA is formed solely by ulnar artery and is completed after joining the radial artery proper on the dorsolateral aspect of the hand as the superficial branch of radial artery was absent and the arch gave origin to 3 common palmar digital arteries to the second, third and fourth spaces and one proper digital artery to the ulnar side of little finger. According to the study by Suman et al.⁽²⁴⁾ the SPA is formed only by ulnar artery in 50% of the hands. The occlusion of ulnar artery can cause ischemic changes in hand especially in which the SPA is completed only by ulnar artery. This is seen in hypothenar hammer syndrome, in those who use hand as a hammer.

In our study we found a variation in which the radialis indicis artery originated from the superficial palmar arch as its terminal branch. Then this radialis indicis artery is communicating by a thin branch from the princeps pollicis artery to complete the arch. The princeps pollicis artery was a branch of radial artery. Another interesting feature identified was that radial artery supplying the lateral two and half fingers and medial two and half fingers by ulnar artery. Proximal to the digital branches the radial artery is and connected to the ulnar artery by a communicating branch and gives a H- shaped appearance.

Despite many studies described the variations in the arterial pattern and formulated the classification based on different aspects, the tortuous ulnar artery in the palm and additional arched branch from ulnar artery connecting the lateral end of the arch identified in the current study has rarely been reported in other studies. Few studies found that a small branch of the radial artery arising from the dorsal surface of the first dorsal interosseous muscle distal to the insertion of the adductor

pollicis muscle passing into the palm and joins the ulnar artery to complete the SPA.^(23,25) The study by Loukas et al. showed only in 4% of subjects, SPA is completed by a communicating branch of the deep palmar arch.⁽³⁾ Buxton et al. identified in all the 50 hands included in the study showed at least one major branch connecting the radial and ulnar arteries.⁽²⁵⁾ The present study showed in 31% of the SPA, a thin collateral or additional branch connecting the regions of the arch.

In our study, the ulnar artery showed comparatively larger diameter than its counterpart in 60 hands (87%). The radial and ulnar arteries were equal sized in 6 hands (9%) and larger radial artery was found in 3 hands (4%). These 9 hands showed classical radio-ulnar SPA or type A superficial palmar arch. The morphometric study by Govsa et al. reported that ulnar artery was the dominant vessel in the palm.⁽¹⁵⁾

The current study deals with the usual and unusual patterns in the vascular architecture of SPA. The formation of superficial palmar arch is highly variable mainly in the radial artery contribution. The absence of the branches of the radial artery or its replacement by other arteries and the size of the arteries involved in the superficial palmar arch formation can cause the variations. This information is crucial in microsurgical procedures of hand and harvesting the radial artery for coronary artery bypass graft. The awareness about such variations may help to prevent the possible complications in medical emergency. These variations can be detected by modified Allen's test, Doppler ultrasonography, pulse oximetry and arterial angiography before surgical interventions. The knowledge about variations in the SPA is essential to detect the collateral circulation, in cases of arterial obstruction.

Reference

1. Ruengsakulrach P, Eizenberg N, Fahrner C, Fahrner M. Anatomic assessment of hand circulation in harvesting the radial artery. *J Thor Cardio Surg.*2001;122:178-80.
2. Gray's Anatomy: The anatomical basis of clinical practice, wrist and Hand.39th ed. Susan Standing London: Elsevier Churchill Livingstone;2006:926-31.
3. Loukas M, Holdman D, Holdman S, Anatomical variations superficial and deep palmar arches. *Folia Morphol.*2005;64:78-83.
4. Gellman H, Botte MJ, Shankwiler J, Gelberman RH. Arterial patterns of the deep and superficial palmar arches. *Clin Ortho Relat Res.*2001;383:41-46.
5. Adachi B: Das arterien system der japaner, Kenkyusha, Kyoto.1928:365,368,389.

6. Huber, G.C.: Piersol's Human Anatomy. In: The Vascular System. 9th Edn. Vol. I, J.B. Lippincot Co. Philadelphia, 1930:785-91.
7. Coleman SS, Anson BJ: Arterial patterns in the hand based upon the study of 650 specimens. *Surg. Gyn. Obst.* 1961;113:409-424.
8. Ikeda A, Ugawa A, Kazihara Y, Hamada N. Arterial patterns in the hand based on a three-dimensional analysis of 220 cadaver hands. *J Hand Surg.*1988;13:501-509.
9. Nasar A, Anita, Haque M, Mohammad N. Uncommon branching pattern and absence of superficial palmar arch with clinical implications. *Int. J Curr Med and AppliedSci.*2015;6(3):213-217.
10. Patnaik V, Kalsey G, Rajan SK. Palmar arterial arches- A morphological study. *J Anat Soc. India.*2002;51(2):187-193.
11. Vidya R, Anil kumar R, Aruna S et al. A cadaveric study on anatomical variations of the superficial palmar arch. *Int. J Med Res Health Sci.*2014;3(1):144-148.
12. Suma MP, Vijay K S, Priya R. An anatomical study of superficial palmar arch. *Int. J Anat Res* 2014;2(4):735-39.
13. Al-TurkM, Metcalf WK. A study of the superficial palmar arteries using the Doppler Ultrasound Flowmeter. *J Anat*,1984;138:27-32.
14. Fazan V, Borges C, Silva J et al. Superficial palmar arch: an arterial diameter study. *J. Anat.*2004;204:307-11.
15. Bilge O, Pinar Y, Ozer M A, Govsa F. Amorphometric study on the superficial palmar arch of the hand. *Surg Radiol Anat.*2006;28(4):343-50.
16. Sarkar A, Dutta S, Bal K, Biswas J. Handedness may be related to variations in palmar arterial arches in humans. *Singapore Med J.* 2012 Jun;53(6):409-12.
17. Joshi S B, Vatsalaswamy P, Bahetee B H. Variation in Formation of Superficial Palmar Arches with Clinical Implications. *J Clin and Diagnostic Res.*2014;8(4):6-9.
18. Moraes S, Araujo TN, Silva AR et al. Morphologic variations of the superficial palmar arc. *Acta Cir Bras.* 2003;18:183-8.
19. Ottone N E, Primum N, Dominguez M et al. Analysis and clinical importance of superficial arterial palmar irrigation and its variants over 86cases. *Int. J Morphology.*2010;28(1):157-64.
20. Jaschtschinski SN. Morphologie and Topography des Arcus volaris sublimis and profundus de Menschen. *Anat Hefte.*1897;7:161-88.
21. Karlsson S, Niechajev I A. Arterial anatomy of the upper extremity. *Acta Radiol.*1982;23:115-21.
22. Vollala V R, Nagabhooshana S, Rao M et al. Unorthodox superficial palmar arch observed in a South Indian cadaver: a case report. *Cases Journal.*2009;2:6362.
23. Saxena A, Agarwal K, Ray B, Pyrtuh S.A Rare Finding of the Superficial Palmar Arch-Developmental and Clinical Significance. *J Clin and Diagnostic Res.*2013;7(4):706-708.
24. Suman U, Jayanthi K S. A study of complete superficial palmar arches formed entirely by ulnar artery. *J. Anat. Soc.India.*2011;60(2):199-201.
25. Ruengsakulrach P, Eizenberg N, Fahrer C et al. Surgical implications of variations in hand collateral circulation: anatomy revisited. *J Thorac. Cardiovasc. Surg.*2001;22(4):682-6.