

Incidence of palmaris longus muscle and tendon variations: a cadaveric study

Pabbati Raji Reddy

Associate Professor, RVM Institute of Medical Sciences & Research Center, Telangana

Email: pabbatirajireddy@gmail.com

Abstract

Introduction: Palmaris longus muscle is one of the most variable muscles of the human body. Complete agenesis, variation in the location and form of the fleshy portion, aberrancy in attachment, duplication or triplication, accessory tendinous slips, replacing elements are some of the variations commonly encountered. Due to the large variability of the Palmaris longus muscle, we had undertaken this study to estimate the prevalence of this variation in our geographical area.

Materials and Methods: A total of 32 cadavers, i.e. 64 upper limbs were dissected for the assessment of Palmaris longus muscle. The length and the circumference of the muscle belly of the Palmaris longus muscle, was noted. The most distal point on the muscle tendon to the point where the tendon crosses the line joining the pisiform bone and the tubercle of the scaphoid bone was measured to assess the length of the muscle. The width of the tendon was measured based on the aponeurosis. Finally, the length of the forearm was measured from the tip of the olecranon process to the styloid process of the ulna.

Results: Out of the 32 cadavers, 23 were males with a total of 46 upper limbs which were used for discussion, 9 were females with 18 upper limbs. The mean length of the muscle in males was 124mm while in females, it was only 86.2mm. There was not much difference in the length and width of the tendon in both the sexes. 4.3% of males and 5.5% of the females had Palmaris longus muscle agenesis. Other deformities were high aponeurosis, slender long Palmaris longus tendon, digastric palmaris longus muscle with a single tendon, fusion of palmaris longus muscle belly with the flexor digitorum superficialis muscle with one case each.

Conclusion: The Palmaris longus muscle is quite prevalent among the population in our area, as observed by the dissection of the cadavers. As Palmaris muscle and the tendon is normally used for tendon replacement, a proper understanding of the variations in the muscle is important.

Keywords: Palmaris longus muscle, Tendon, Deformity, Cadavers

Introduction

Palmaris longus is a fusiform shaped, slender muscle, which originates from the medial epicondyle of the humerus and from adjacent intermuscular septa and deep fascia. It is one of the thinnest flexor muscles of the carpus and is situated in the anterior region of the forearm. It occupies the region that lies medial to the radial flexors of the carpus and lateral to the flexor carpi ulnaris, thus covering posterior part of the superficial flexor digitorum¹. Its arterial supply is by a small branch from the anterior ulnar recurrent artery. It is innervated by the median nerve. It is a phylogenetically a degenerate metacarpophalangeal joint flexor².

It is one of the most variable muscles of the human body. Complete agenesis, variation in the location and form of the fleshy portion, aberrancy in attachment, duplication or triplication, accessory tendinous slips, replacing elements are some of the variations commonly encountered³⁻⁵. These variations are important clinically as they may cause compartment syndrome of the forearm, and the wrist, carpal tunnel syndrome, Guyon's syndrome and chances of misinterpretation in images by the radiologists. It is also a landmark in operations on forearm and wrists and its tendon can be used as a graft⁶⁻⁸.

Complete absence of the muscle has been reported in earlier studies⁹⁻¹¹. The non-preferred hand dominance

was shown to be one of the criteria for absence of the muscles. The Palmaris longus muscle was more likely to be absent in non-dominant hand¹². Hereditary was another cause of absence of the muscle. In Caucasian population, a unilateral absence was found in 16% and bilateral absence in 9%, and males were found to be more affected¹³⁻¹⁵.

Due to the large variability of the Palmaris longus muscle, we had undertaken this study to estimate the prevalence of this variation in our geographical area

Material and Methods

This study was conducted by the Department of Anatomy at Medicity institute of medical sciences during the period of two years. A total of 32 cadavers, brought to the Department of anatomy were taken into consideration.

The cadavers were injected with preservative liquids by body injector and then placed in tank solution. A total of 64 upper limbs were dissected for the assessment of Palmaris longus muscle.

The length of the muscle belly was noted in each of the cadavers by measuring the distance from the tip of the medial epicondyle to the most distal point of the muscle tendon border.

The circumference of the muscle belly was measured around the mid-point of the muscle. The most distal point on the muscle tendon to the point where the tendon crosses the line joining the pisiform bone and the tubercle of the scaphoid bone was measured to assess the length of the muscle. Width of the tendon was measured 5 cm proximal to the apex of palmar aponeurosis. The Intra muscular part of the tendon was measured from the most proximal point to the most distal point of the muscle tendon border. Finally, the length of the forearm was measured from the tip of the olecranon process to the styloid process of the ulna.

Any morphological aberrations found in the tendon were judiciously noted.

Statistical analysis was based on the mean; deviation; squared deviation; standard deviation and ranges

Results

Out of the 32 cadavers, 23 were males with a total of 46 upper limbs which were used for discussion, 9 were females with 18 upper limbs (Fig. 1).

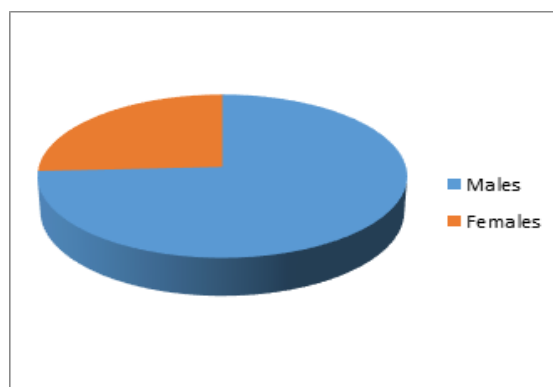


Fig. 1: Sex wise distribution of the cadavers

Out of the 46 upper limbs of the males, there were 2 cases, where tendons were absent unilaterally. Both were on the left hands accounting for 4.3% of the cases. Among the females, one case (5.5%) had Palmaris longus agenesis on the left hand.

The length of the forearm was more than that of the females, as was the length of the Palmaris longus muscle. The mean length of the muscle in males was 122.18 mm while in females, it was only 84.2mm. There was not much difference in the length and width of the tendon in both the sexes (Table 1).

Table 1: Measurements of the muscle and tendon in the cadavers

Parameter	Males		Females	
	Length in mm (SD)	Range in mm	Length (SD)	Range
Length of forearm	269.97 (± 7.52)	267.40-271.56	250.33 (± 8.48)	246.02-255.64
Length of Palmaris longus muscle	122.18 (14.18)	117.56-127.6	84.2 (8.58)	80.95-88.76
Circumference of muscle belly	31.23(5.33)	27.59-30.67	24.88 (4.97)	23.77-27.13
Length of the tendon	155.01 (11.1)	147.32-155.61	150.2(16.60)	144.84-161.47
Width of the tendon	3.2(0.62)	3.00-3.51	3.83(0.59)	3.44-4.01
Length of Intramuscular part of tendon	23.21 (2.97)	21.53-25.39	21.47(3.62)	19.97-25.07

In the present study, there were 2 cases of agenesis of the Palmaris longus muscle and tendon in the male (4.3%) and 1 case in females (5.6%).

A number of variations were observed in the Palmaris longus muscle in 6 cases:

High aponeurosis: In one of the cadavers the tendon of Palmaris longus showed aponeurotic expansion 3 inches above the palm, i.e. in the distal 1/4th of the fore

arm. The length and breadth of the aponeurotic expansion measured about 5x3 cm. This wide aponeurotic sheath of Palmaris longus tendon formed in the lower 1/4th of the forearm covered the median nerve like a protective sheet. Later it is divided into two slips and merged with the deep fascia of the wrist (Fig. 2)



Fig. 2: High aponeurosis of the Palmaris longus muscle

This type of variation of Palmaris longus tendon expansion in the forearm has not been reported so far.

In another case the aponeurotic expansion of the tendon of Palmaris longus was very extensive in length and width occupying 3 inches of the forearm.

Slender rounded palmaris longus tendon: Thread like, slender rounded Palmaris longus tendon was observed in 2 cases. Muscle belly was very slender and Short (Fig. 3).

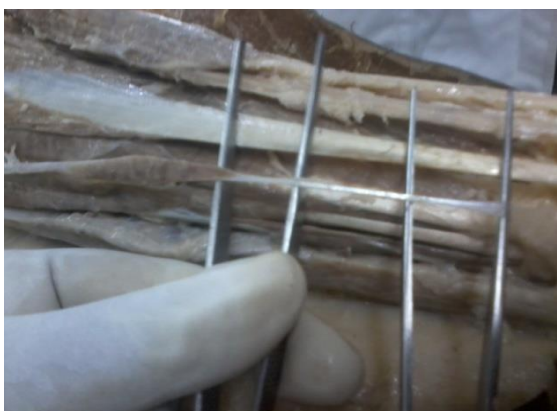

Fig. 3: Slender rounded Palmaris longus tendon

Digastric palmaris longus muscle with a single tendon: Intermediate tendon with two muscle bellies-Upper and Lower. There are present in the upper half of the forearm. In the lower half of forearm the Palmaris longus tendon was normal and in the palm the formation of aponeurosis was noted (Fig. 4).



Fig. 4: Palmaris longus with 2 muscle bellies

Fusion of palmaris longus muscle belly with the flexor digitorum superficialis muscle: The muscle belly of Palmaris longus fused with the muscle belly of the flexor digitorum superficialis throughout its entire extent. The picture shows that the Palmaris longus muscle is split open from the flexor digitorum superficialis (Fig. 5).



Fig. 5: Fusion of palmaris longus muscle belly with the flexor digitorum superficialis muscle

Discussion

Palmaris longus is a superficial flexor of the forearm, which arises from the medial epicondyle of humerus by the common flexor origin, from the intramuscular septum present adjacently and also form the antebrachial fascia¹⁶. It converges on a long tendon, which passes anterior (superficial) to the flexor retinaculum. A few fibres leave the tendon and interweave with the transverse fibres of the retinaculum, but most of the tendon passes distally. As the tendon crosses the retinaculum it broadens out to become a flat sheet which becomes incorporated into the palmar aponeurosis¹⁷.

The Palmaris longus muscle is known to be one of the most variable muscles in the human body. It is classified as a phylogenetically retrogressive muscle i.e. the one that has a short belly and a long tendon¹⁸. It is known to exist only in the mammals, especially in those where the fore limb is used as an organ of ambulation¹⁹.

Agenesis or absence of the Palmaris tendon has been reported in several textbook to be around 15%^{2,20,21}.

We found a prevalence of 4.3% in this cadaveric study. This was in contrast to many other studies where the incidence was far higher. In a study among the North American Caucasians, a prevalence of 24% of agenesis of Palmaris longus muscle was observed²², while in a study in Pennsylvania; a prevalence of 23% was reported²³. A higher prevalence of 31.25% was observed in the Nigerian population, which was either unilateral or bilateral²⁴.

The results of our study was in accordance with many other studies. In Japanese population, an incidence of 3.4% was observed²⁵ while in Chinese population 4.6% incidence was seen²⁶. A very low prevalence of 0.6% was observed in the Korean population²⁷.

Although the tendon is continuous with the Palmaris muscles, histological studies have shown that the development of the two structures is independent to each other and do not share a common origin. That is probably why there is a great variation in the attachment of these two structures³⁴.

Our study revealed a high aponeurotic expansion, 3 inches above the palm, i.e. in the distal 1/4th of the forearm. This wide aponeurotic sheath of Palmaris longus tendon formed in the lower 1/4th of the forearm covered the median nerve like a protective sheet. Later it was divided into two slips and merged with the deep fascia of the wrist.

Duplicate muscle bellies were observed in one case in our study in a male cadaver amounting to 2.2%. The incidence for duplicate Palmaris longus muscle was observed to be between 1.9% - 2.5% in Japan in several studies^{25,28,29}. Amongst the Russians, it was observed to be 3.1%³⁰ and 0.8% among the Americans⁵.

In some cases, the muscle bellies were found to be two or three headed due to the reversal of Palmaris longus muscle^{18,31,32}.

One case in our study had Palmaris longus muscle fused with the flexor digitorum superficialis muscle. A similar result was observed by Koopuz et al, who reported the fibres of Palmaris longus muscle joined to the flexor digitorum superficialis³³.

One of the most popular muscles used in tendon grafts is the Palmaris longus muscle, due to its length and diameter and also as it can be used without functional deformities. The long flexors of the fingers and flexor pollicis longus tendon are the ones that are replaced by Palmaris longus muscle³⁴.

Conclusion

In our geographical area, agenesis of Palmaris longus muscle was the predominant deformity observed compared to the rest. The other deformities observed were high aponeurosis, slender long Palmaris longus tendon, digastric palmaris longus muscle with a single

tendon, fusion of palmaris longus muscle belly with the flexor digitorum superficialis muscle.

References

1. Stecco C, Lancerotto L, Porzionato A, Macchi V, Tiengo C, Parenti A, et al. The palmaris longus muscle and its relations with the antebrachial fascia and the palmar aponeurosis. *Clin Anat*. 2009;22(2):221-9.
2. Standring S. *Gray's anatomy*, 40th edn. Elsevier Churchill Livingstone, Edinburgh, 2008. p. 847. 2.
3. Natsis K, Levva S, Totlis T, Anastasopoulos N, Paraskevas G. Three-headed reversed palmaris longus muscle and its clinical significance. *Ann Anat*. 2007;189:97-101. [PubMed]
4. Paraskevas G, Tzaveas A, Natsis K, Kitsoulis P, Spyridakis I. Failure of palmaris longus muscle duplication and its clinical application. *Folia Morphol (Warsz)* 2008;67:150-153. [PubMed]
5. Reimann A, Dasele E, Anson B, Beaton L. The Palmaris longus muscle and tendon. A study of 1600 extremities. *Anat Rec*. 1944;89:495-505.
6. Acikel C, Ulkur E, Karagoz H, Celikoz B. Effort-related compression of median and ulnar nerves as a result of reversed three-headed and hypertrophied palmaris longus muscle with extension of Guyon's canal. *Scan J Plast Reconstr Surg Hand Surg*. 2007;41:45-47.
7. Bencteux P, Simonet J, el Ayoubi L, Renard M, Attignon I, Dacher JN, et al. Symptomatic palmaris longus muscle variation with MRI and surgical correlation: report of a single case. *Surg Radiol Anat*. 2001;23:273-275.
8. Polesuk BS, Helms CA. Hypertrophied palmaris longus muscle, a pseudomass of the forearm: MR appearance--case report and review of the literature. *Radiology*. 1998;207:361-362.
9. Sankar KD, Bhanu PS, John SP. "Incidence of agenesis of palmaris longus in the Andhra population of India," *Indian Journal of Plastic Surgery*, 2011; 44(1):134-138.
10. Kigera JWM and Mukwaya S, "Frequency of agenesis Palmaris longus through clinical examination--an East African study," *PLoS ONE*, vol. 6(12) Article ID e28997, 2011.
11. Sater MS, Dharap AS, Abu-Hijleh MF, "The prevalence of absence of the palmaris longus muscle in the Bahraini population," *Clinical Anatomy* 2010; 23(8): 956-961.
12. Eric M, Koprivčić I, Vučinić N, "Prevalence of the palmaris longus in relation to the hand dominance," *Surgical and Radiologic Anatomy*, 2011;33(6):481-484.
13. Kose O, Adanir O, Cirpar M, Kurklu M, Komurcu M. "The prevalence of absence of the palmaris longus: a study in Turkish population," *Archives of Orthopaedic and Trauma Surgery*, 2009;129(5):609-611.
14. Sebastin J, Lim AYT, Wong HB, "Clinical assessment of absence of the palmaris longus and its association with other anatomical anomalies--a Chinese population study," *Annals of the Academy of Medicine Singapore*, 2006;35(4):249-253.
15. Mbaka GO and Ejiwunmi AB, "Prevalence of palmaris longus absence--a study in the Yoruba population," *Ulster Medical Journal*, 2009;78(2):90-93.
16. Iqbal S, Iqbal R, Iqbal F. Bitendinous Palmaris Longus: Aberrant Insertions and Its Clinical Impact - A Case Report. *J Clin Diagn Res*. 2015 May;9(5): AD03-AD05.
17. Necdet K, Selda Y, Develi S, Ozan H, Yazar F. Morphometric analysis of the palmaris longus muscle: a fetal study. *Anatomy* 2012;2:42-47

18. Koo CC, Roberts AH. The palmaris longus tendon. Another variation in its anatomy. *J Hand Surg Br* 1997;22:138-9.
19. Vanderhooft E. The frequency and relationship between the palmaris longus and plantaris tendons. *Am J Orthop* 1996;25:38-41.
20. Sinnatamby CS. *Last's anatomy. Regional and applied.* 10th ed. Edinburgh: Churchill Livingstone; 1999. p. 63.
21. Moore KL, Dalley AF. *Clinically oriented anatomy.* 4th ed. Philadelphia: Lippincott Williams & Wilkins; 1999. p. 737.
22. Troha F, Baibak GJ, Kelleher JC. Frequency of the palmaris longus tendon in North American Caucasians. *Ann Plast Surg* 1990; 25:477-8.
23. Wehbe MA. Tendon graft donor sites. *J Hand Surg Am* 1992;17:1130-2.
24. Kayode AO, Olamide AA, Blessing IO, Victor OU. Incidence of palmaris longus muscle absence in Nigerian population. *Int J Morphol* 2008;26:305-308.
25. Adachi B. Beiträge zur Anatomie der Japaner. XII. Die Statistik der Muskel varietäten. *Zeitsch Morphol Anthropol* 1909;12:261-312.
26. Sebastin SJ, Puhaindran ME, Lim AY, Lim IJ, Bee WH. The prevalence of absence of the palmaris longus - A study in a Chinese population and a review of the literature. *J Hand Surg Br* 2005;30:525-7.
27. Eriç M, Krivokuça D, Savović S, Leksan I, Vuciniç N. Prevalence of the palmaris longus through clinical evaluation. *Surg Radiol Anat* 2010;32:357-61.
28. Caughell KA, McFarlane RM, McGrouther DA, Martin AH. Developmental anatomy of the palmar aponeurosis and its relationship to the palmaris longus tendon. *J Hand Surg Am.* 1988;13:485-93.
29. Koganei Y, Arai H, Shikunami J. Varietätenstatistik der musc. Tokyo Igakkai Zasshi 1903;17:127-131.
30. Sato Y, Takeuchi R, Umeno K, Chen S, Takafuji T. A contribution to the study of the M palmaris longus. *Acta Anat Nippon* 1974;19:318-319.
31. Gruber W. Über die varietäten des musculus an palmaris longus. *Meml'Acad Imp Sci St Petersburg* 1868;S711:1-26
32. Yeldez M, fiener M, Aynac› O. Three-headed reversed palmaris longus muscle: a case report and review of the literature. *Surg Radiol Anat* 2000;22:217-9.
33. Kopuz C. Yenidoanlarda m. palmaris longus'un morfolojikolarak incelenmesi. *Morfoloji Dergisi* 1999;7:6-9.
34. Thejodhar P, Potu BK, Vasavi RG. "Unusual palmaris longus muscle". *Indian Journal of Plastic Surgery* 2008;41(1):95-6