

The better version of routine tissue processing technique-modified tissue processing

Shalini Gupta^{1,*}, Prateek Gautam², Bindu Singh³

^{1,2}Lecturer, ³Associate Professor, BRD Medical College, Gorakhpur, Uttar Pradesh

***Corresponding Author:**

Shalini Gupta

Lecturer, BRD Medical College, Gorakhpur, Uttar Pradesh

Email: guptasalini22@yahoo.com

Abstract

We all know that “necessity is the mother of all inventions”, this applies very well to this technique. This experiment was carried out to overcome the drawbacks of routine tissue processing like difficult procurement, shrinkage, dull intensity of color, hardening etc. During routine tissue processing paraffin embedding is done before sectioning and the tissue has to undergo the process of fixation and dehydration in order to get prepared for sectioning. Very commonly used dehydrating agent which is considered to be a good one is ethyl alcohol but its purchase is subjected to many restrictions and causes shrinkage and hardening of tissue. Owing to this drawback of ethyl alcohol various other dehydrating agents were launched and used. We have tried a combination of isopropyl alcohol with acetone (3:1) and compared the section with routine tissue processing method. Sections prepared were stained with hematoxylin and eosin. The results obtained were much better than the routine technique when compared as well the modified technique was found to be cost effective as well.

Keywords: Ethyl alcohol, Neutral Buffered formalin, Acetone, Isopropyl alcohol, Modified processing

Introduction

The dawn of 21st century heralds the coming age of molecular medicine and era of preventive medicine. Physical examination alone can no longer suffice for clinching a diagnosis and light microscopy need to be strengthened by ultra-structural analysis for evaluation of disorder.^[1]

Histology is the study of tissue which involve investigation of microscopic anatomy or architecture of more specialized tissue.^[2]

Stabilized tissues must be adequately supported before they can be sectioned for microscopically examination. Whilst they may be sectioned following a range of preparatory freezing methods, tissues are more commonly taken through a series of reagents and finally infiltrated and embedded in a stable medium which when hard, provides the necessary support for microtomy. This treatment is termed tissue processing.

The quality of structural preservation seen in the final stained and mounted section is largely determined by the choice of fixative and embedding medium. During tissue processing loss of cellular constituents and shrinkage or distortion should be minimal. After fixation, post-fixation and preparatory procedures, the four main stages in the paraffin method are dehydration, clearing, infiltration and embedding.

Each step of tissue processing is of utmost importance from procurement till final mounting. Out of every step of tissue processing dehydrating agents were among the most noxious and highly inflammable chemicals found in laboratory of histology.

From decades formalin as fixative, ethanol as a dehydrating agent, had been the first choice in spite of its drawbacks like hardening and shrinkage of tissue,

highly inflammable, difficult procurement, high price and tissue brittleness.

Most methods currently used to manipulate tissues for microscopic examination were developed in the early 1900s.^[3]

Here also we did an experiment in the department by replacing the routine formalin as a fixating agent by neutral buffered solution and ethanol with a combination of Isopropyl alcohol and acetone (Ratio 3:1) in various grades without compromising the quality, but at same time overcoming the drawbacks.

Aims & Objectives

1. To overcome the drawbacks faced during routine tissue processing technique.
2. To evolve a method which is more cost effective and time saving than routine method.

Material and Method

The present study was conducted in the Department of Anatomy, BRD medical college, Gorakhpur.

Fresh specimens of lymph node, ileum, pancreas, hyaline cartilage and spleen were procured from the postmortem house without any external identifiable pathology. They were then divided into 2 groups.

Tissues in **Group A** were fixed in 10% formalin for a duration of one week. Dehydrating agent used is ethanol in grades of 50%, 70%, 90%, Absolute for 60 mins each and was stained with hematoxylin and eosin.

Tissue in **Group B** were fixed in Buffered formalin for 72 hrs. Dehydrating agent used is a combination of isopropyl alcohol and acetone in ratio of 3:1 in grades of 70%, 90% and absolute for 30 mins each and was stained using Hematoxylin and eosin.

Rest of the further procedure like clearing with xylene, embedding and impregnation with paraffin wax, dewaxing, and final mounting remain common for both Group A and B.

Slides were prepared and shown to 10 faculty members, 10 technical staff for report about the various criteria of slides of both group A & group B on cellular clarity, cytoplasmic details, nuclear clarity, color intensity, connective tissue.

Observation

Grades: Score from 1-10 was being given by the observers to both the slides which was being recorded in table after calculating the mean score.

Table 1

S. No	Criteria	Better	Poor	Same
1.	Cellular Clarity	13	4	3
2.	Cytoplasmic Details	14	4	2
3.	Nuclear Clarity	17	3	-
4.	Color Intensity	16	-	4
5.	Connective tissue	12	3	5
6.	Overall Cost	18	-	2
7.	Time consumption	20	-	-

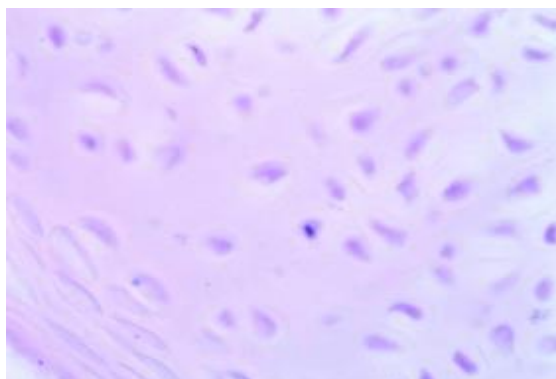
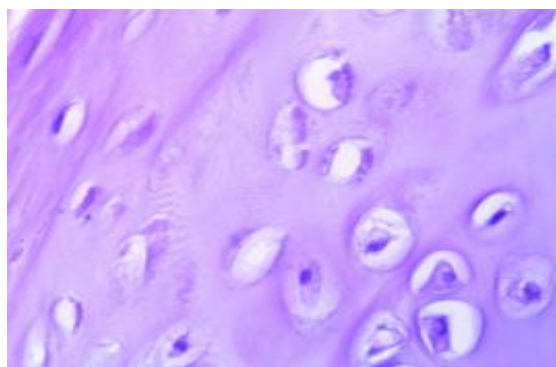


Fig. 1: Hyaline cartilage (Routine)



(Modified)

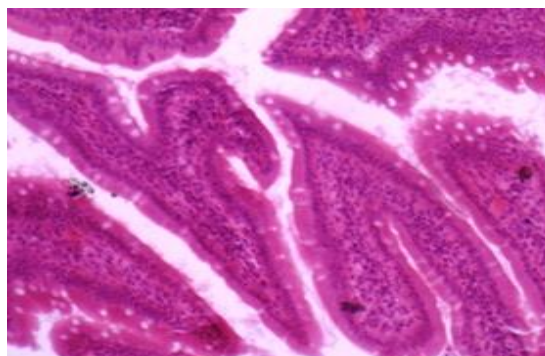
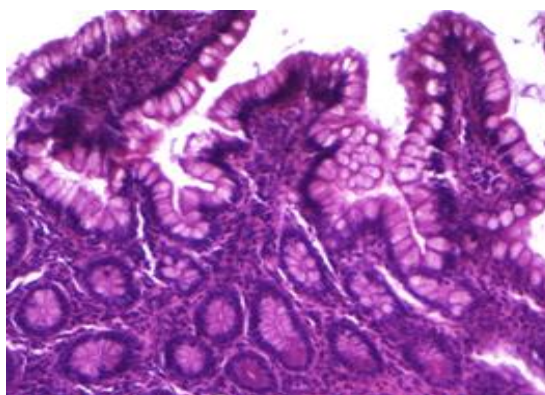


Fig. 2: Ileum (Routine)



(Modified)

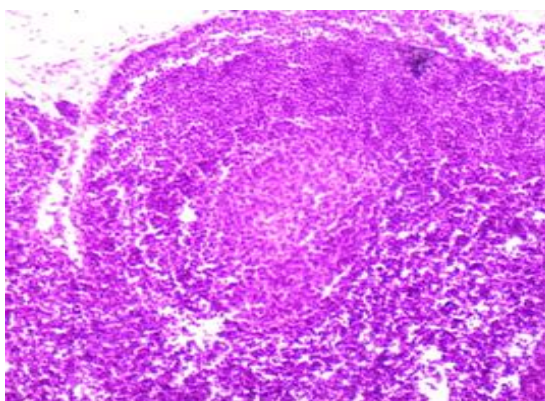
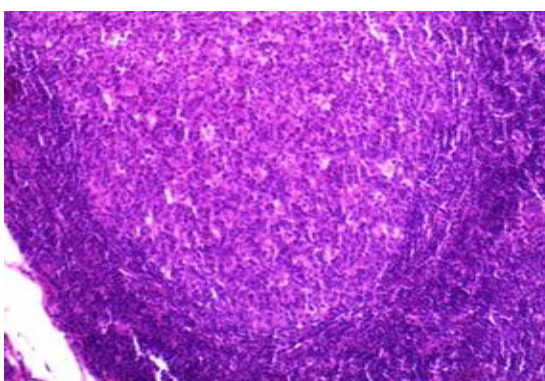


Fig. 3: Lymph Node (Routine)



(Modified)

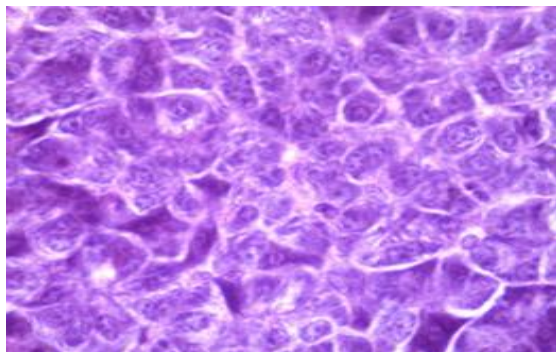
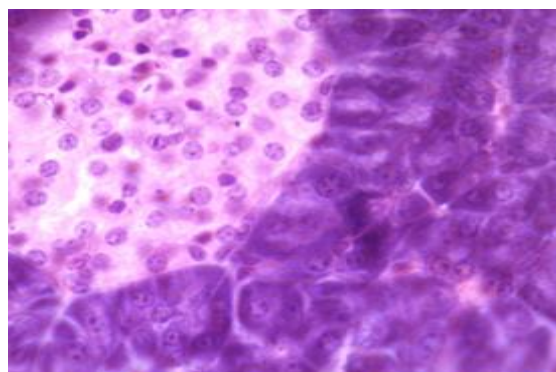


Fig. 4: Pancreas (Routine)



(Modified)

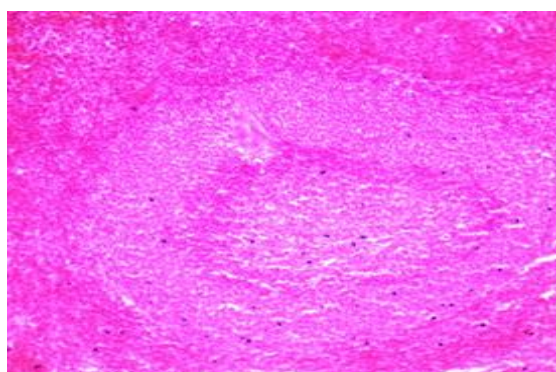
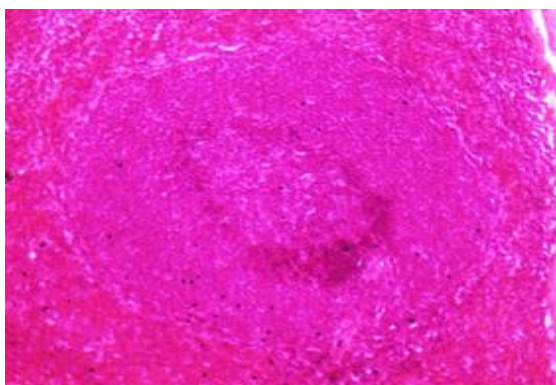


Fig. 5: Spleen (Routine)



(Modified)

Table 2: Time comparison chart

S. No	Steps	Routine	Modified
1.	Fixation	1 wk in formalin	72 hrs in buffered formalin
2.	Dehydration (total)	Approx. 5hrs	Approx. 2.5 hrs
3.	Clearing (total)	3hrs	1.5hrs
4.	Rehydration	8-10min	4-5min
3.	Staining (Total)	Approx 10 mins	Approx 8 mins
4.	Total Time	Approx 176 hrs	Approx 76 hrs

Table 3: Cost comparison chart

S. No.	Reagents	Routine technique		Modern technique	
		Amount used	Cost (Rs)	Amount used	Cost (Rs)
1.	Formalin	1.5 lit	690	1.5 lit	690
2.	Ethanol	1.5 lit	1800		
3.	Isopropyl alcohol			1.5 lit	1000
4.	Acetone			½ lit	360
	Total	3 lit	2490	3.5 lit	2050

Total estimate of routine technique was about Rs 2,490 while that of modified technique was Rs 2,050

Result & Discussion

Based on observation following results were obtained:-

- The overall time duration by this method of tissue processing was almost reduced to half.
- Cellular, cytoplasmic, nuclear details, color intensity was better.
- Cost effective

For almost 100 years, the steps followed to prepare tissues for microscopic review have remained practically unchanged.^[4]

Formaldehyde-Fixed Paraffin-Embedded tissue (FFPE) is the product of a century old histopathology practice. However, tissue processed by this system has limited application beyond routine histology and immunohistochemistry^[5].

Substantial shortcomings associated with this practice include at least a one day delay in providing the diagnosis,^[6,7] reagent toxicity, and degradation of nucleic acids^[8].

The method reported here reproducibly yield histologic material of similar or superior quality to that provided by time honored conventional processing. It has many advantage & potential for preserving of molecular integrity of specimen that might be used for subsequent studies.

Similar study was done by Buesa R.J^[9] in department of pathology, Miami using mineral oil as dehydrating agent. They produced results which were almost similar to our results, however the cost factor was not considered there.

Conclusion

It has always been a tough job for histopathologist specially to give results in less time without compromising the quality. In such situation the above method would prove to be a boon for them.

References

1. Singh. D.R. Principles & technique in histology microscopy & photomicrography; CBS publisher;2006.
2. Drury R.A.B & Wallington E.A; Carleton histological technique 5thedition.Oxford University Press, Oxford 1967;pg1.
3. Cox ML, Schray CL, Luster CN, Stewart ZS, Korytko PJ, Khan KNM, et al. Assessment of fixatives, fixation and tissue processing on morphology and RNA integrity. *Experimental and Molecular Pathology*.2006;80:183–91.
4. Morales AR, Nassiri M, Kanhoush R, Vincek V, Nadji M. Experience with an automated microwave-assisted rapid tissue processing Method. Validation of Histologic Quality and Impact on the Timeliness of Diagnostic Surgical Pathology. *Am J Clin Pathol*. 2004;121:528–36.
5. Nassiri M, Ramos S, Zohourian H, Vincek V, Morales AR, Nadji M. Preservation of biomolecule in breast cancer by a formalin free histology system. *BMC Clinical Pathol*. 2008;8:1045–56.
6. Zarbo RJ, Gephardt GN, Howanitz PJ. Intra-laboratory timeliness of surgical pathology reports. *Arch Pathol Lab Med*. 1996;120:234–44.
7. Novis DA, Zarbo RJ, Saladino AJ. Inter-institutional comparison of surgical biopsy diagnosis turnaround time. *Arch Pathol Lab Med*. 1998;122:951–6.
8. Lewis F, Maughan NJ, Smith V, Hillan K, Quirke P. Unlocking the archive: gene expression in paraffin-embedded tissue. *J Pathol*. 2001;195:66–71.
9. Rene J. Buesa, Department of pathology Mount Sinai Medical College, Miami.