

Variations in the origin of profunda femoris and circumflex femoral arteries: A cadaveric study

Rakesh Kumar Verma^{1,*}, Arvind Kumar Pankaj², Anita Rani³, Navneet Kumar⁴, Archana Rani⁵

^{1,2}Assistant Professor, ^{3,4,5}Professor, Dept. of Anatomy, King George's Medical University, Lucknow, Uttar Pradesh

*Corresponding Author:

Rakesh Kumar Verma

Assistant Professor, Dept. of Anatomy, King George's Medical University, Lucknow, Uttar Pradesh

Email: rakesh_gsvm@yahoo.co.in

Abstract

Introduction: Profunda femoris artery (PFA) normally originates from posterolateral aspect of femoral artery and circumflex arteries arise from profunda femoris artery near its origin. As femoral artery (FA) & PFA are commonly assessed for various procedures for diagnosis and treatment for many diseases, knowledge of its course and branching pattern is very important for clinicians to prevent complications.

Methods: The present study was conducted on 38 thighs. The origin, diameter at the point of origin, branching pattern of profunda femoris and circumflex femoral arteries were observed and their distances from mid inguinal point (MIP) was measured and recorded.

Results: In 100% cases on both right and left side PFA was arising from FA. The site of origin of PFA was maximally (63.16%) found on posterior surface of FA. The mean distance of origin of PFA was 39.55 mm. In majority of cases, lateral & medial circumflex arteries were originating from PFA i.e. 84.21% and 73.68% respectively and the mean distance from MIP was 52.27 mm and 42.62 mm respectively. The lateral circumflex artery was arising from FA on right side in 22.23% while on left side in 10% cases. The medial circumflex artery was arising directly from FA on right side in 33.33% and on left side in 20% cases.

Conclusion: In present study, the most common site of origin of the PFA was from posterior side of FA. The origin of the PFA observed was slightly proximal than noted in other studies. However, the left profunda femoris originates more distally than the right. Lateral & medial circumflex arteries commonly originated from the PFA artery close to its origin. This knowledge is very valuable in preventing injury to these vessels during different procedures.

Keywords: Femoral artery, Profunda femoris Artery, Lateral circumflex artery, Medial circumflex artery

Introduction

Femoral artery is a continuation of external iliac artery below the mid inguinal point. At the base of femoral triangle, it lies between femoral vein and femoral nerve, runs downwards and medially and gives branches at different levels before entering in adductor hiatus. The profunda femoris normally originates from posterolateral aspect of femoral artery. Circumflex arteries arise from profunda femoris artery (PFA) near its origin.¹ Femoral artery is commonly used for various interventional procedures for diagnosis and treatment of number of diseases as coronary angiography & angioplasty. For femoral embolectomy, femoral artery is usually opened in the femoral triangle near the origin of the profunda femoris artery in lower limb arterial thromboembolism.² In place of femoral artery, profunda femoris artery is not uncommonly used for haemodialysis. The branches of profunda femoris are also used in anterolateral perforator thigh flap as long vascular pedicle during breast construction.³ So, proper knowledge of its course and branching pattern is very important for anatomists, surgeons and radiologists to prevent complications.

Material and Methods

The present study was conducted on 38 thighs (Rt=18, Lt=20) of adult and old age group, during

educational dissection of human cadaver in the Department of Anatomy, King George's Medical University, Lucknow (U.P.). The origin, diameter at the point of origin, course and branching pattern of profunda femoris and circumflex femoral arteries were observed and their distances from mid inguinal point was also measured with the help of digital Vernier caliper, scale and divider.

Observations and Results

In 100% cases on both right and left side, profunda femoris artery (PFA) was arising from femoral artery. The site of origin of PFA was maximally (63.16%) found on posterior aspect of femoral artery (Table 1, Fig. 1). The highest point of origin of PFA from mid inguinal point was 10 mm on right side & 20 mm on left side. The lowest point of origin of PFA from mid inguinal point was 58 mm on right side & 67 mm on left side. The mean distance of origin of PFA on right was 37.55mm & on left was 41.55mm (Mean distance of PFA in total thighs was 39.55 mm). The mean diameter at site of origin on right was 6.88mm & left was 6.5mm (Table 1).

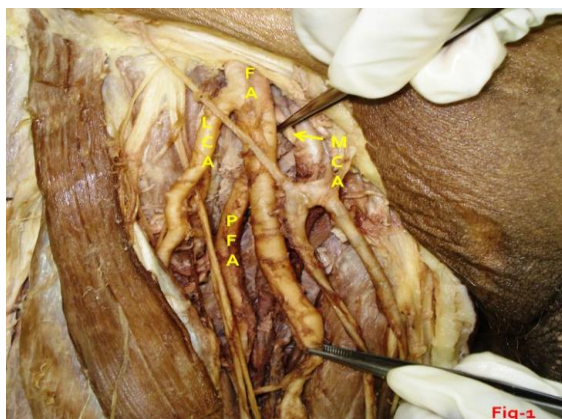

Fig. 1

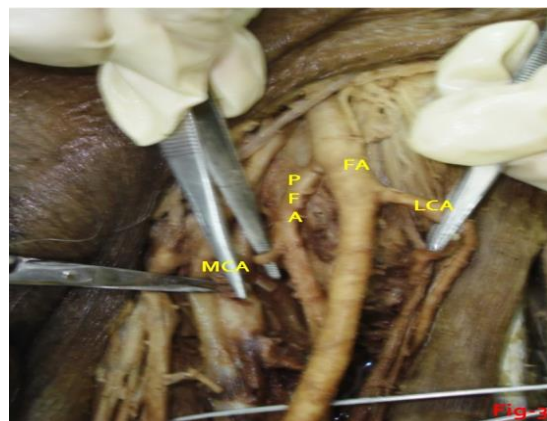


Fig. 3

In majority of cases, lateral (84.21%) & medial (73.68%) circumflex arteries were originating from PFA. The mean distance from mid inguinal point was 52.27 mm & 42.62 mm and average diameter was 5.4 mm & 4.42 mm respectively (Table 2 & 3).

The lateral circumflex artery (LCA) in right side of thighs were arising from femoral artery in 22.23% and from PFA in 77.77% while in left side of thighs it was originating 10% from femoral & 90% from profunda femoris artery. The medial circumflex artery (MCA) was originating directly from femoral artery in 33.33% cases on right side of thighs and 20% on left side while rest were originating from PFA (Table 2 & 3, Fig. 2). Direct origin of LCA or MCA or both coming from femoral artery, are seen in few cases proximal and in some distal to origin of PFA (Fig. 1, 2, 3, 4).

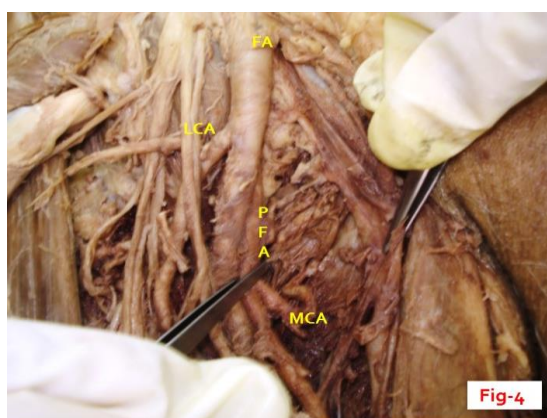


Fig. 4

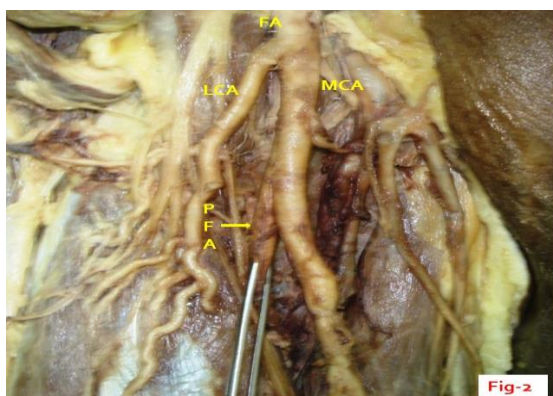


Fig. 2

Table 1: Site, diameter & distance of PFA at its origin

Side & No.	Right (n=18)			Left (n=20)			Total (38)			
	PL	P	L	P	L	PM	PL	P	L	PM
Site of origin	44.44% (8)	44.44% (8)	11.11% (2)	80% (16)	10% (2)	10% (2)	21.05% (8)	63.16% (24)	10.53% (4)	5.26% (2)
Mean diameter at site of origin (mm)	6.88			6.5			6.69			
Mean distance of origin from midpoint of	37.55			41.55			39.55			

inguinal ligament (mm)			
------------------------	--	--	--

(PFA-Profunda Femoris Artery, PL- Posterolateral, P- Posterior, L- Lateral, PM-Posteromedial, n-number)

Table 2: Source, diameter & distance of lateral circumflex femoral artery at its origin

Side & No.		Right (n=18)	Left (n=20)	Total (38)
Source of origin	Femoral artery	22.23% (4)	10% (2)	15.79% (6)
	Profunda femoris Artery	77.77% (14)	90% (18)	84.21% (32)
Mean diameter at site of origin (mm)		5	5.8	5.4
Mean distance of origin from midpoint of inguinal ligament (mm)		50.2	54.33	52.27

Table 3: Source, diameter & distance of medial circumflex femoral artery at its origin

Side & No.		Right (n=18)	Left (n=20)	Total (38)
Source of origin	Femoral artery	33.33% (6)	20% (4)	26.32% (10)
	Profunda femoris Artery	66.67% (12)	80% (16)	73.68% (28)
Mean diameter at site of origin (mm)		4.71	4.22	4.42
Mean distance of origin from midpoint of inguinal ligament (mm)		40.33	44.9	42.62

Discussion

In our study, the profunda femoris artery originated maximally (63.16%) from posterior surface of femoral artery which is similar to findings of Samarawickrama et al. (12/26, 46%) but 28.5% of cases (65 limbs) observed by Dixit et al.^{4,5} The PFA commonly arose from posterolateral surface of FA reported by Dixit et al. (42.1%), Prakash et al., Lippert and Pabst 48%.⁵⁻⁷ The common site of origin of profunda femoris artery is posterolateral aspect of femoral artery also described in standard text books.^{1,8-10} We also found in 21.05% (8/38) cases where it originated from the posterolateral side of the femoral artery. However, we found 4 out of 38 arteries (10.53%) originated from the lateral aspect of the femoral artery (Fig. 1 & 4). Only in 2 cases (5.26%) we encountered PFA was arising from posteromedial aspect of FA (Table 1).

The average distance of origin of profunda femoris from the midpoint of inguinal ligament on the right side was 37.55 mm and on the left side 41.55 mm. This indicates that the origin of the left profunda artery is usually proximal to the origin of the right profunda artery. The average distance of origin was 39.55mm when both sides taken together and this runs parallel with findings of Bannister et al. (35mm).¹¹ This distance was more than the average distance of origin reported in the literature by Dixit et al. (47.5mm), Samarawickrama et al. (50mm) and Siddharth et al. (44mm).^{4,5,12}

The lateral circumflex femoral artery mostly originated from the profunda femoris artery in 32 out of 38 cases (84.21%). This is the commonest pattern of origin of this artery cited in the literature. It was

observed by Samarawickrama et al. in 92%, Prakash et al. in 81.25%, Dixit et al. in 75% and 77.3% in Turkish population.^{4-6,13} The remaining 15.79% of cases originated from femoral artery. The mean diameter and mean distance from mid inguinal point was 5.4mm and 52.27 mm recorded. Dixit et al. reported average distance of origin from PFA was between 21-30mm.⁵

The medial circumflex artery arose from PFA in 66.67% in right and 80% in left side with average 73.68% (28/38) of total. It was observed 61.4% by Dixit et al., 67.2% by Prakash et al. and 62% in Sir Lankan population by Samarawickrama et al. which are slightly low in comparison to our finding.⁴⁻⁶ The origin from the common femoral artery was 26.32% in our study which was lower than Dixit et al. (38.6%) and 32.8% by Prakash et al. and 38% by Samarawickrama et al.⁴⁻⁶ The average diameter and mean distance from mid inguinal point was recorded as 4.42mm & 42.62 mm.

Anatomical variations reported at the level of division of the femoral artery can be explained as found in the lower animals, the profunda femoris artery is a branch of the internal iliac artery. During course of evolution, the origin shifted distally from the femoral artery. Ontogeny repeats phylogeny. Hence, developmental arrest at different stages may lead to anatomical variations related to the division of the femoral artery.⁶

The development of the vasculature in the lower limb precedes the morphological and molecular changes that occur in the limb mesenchyme; hence vascular variations are more of a rule than an exception.¹⁴ Anomalous patterns of vascular system

may be due to divergence in the mode and proximo-distal level of branching; presence of unusual compound arterial segments; aberrant vessels that connect with the principal vessels, arcades or plexuses; and vessels occupying exceptional tissue planes and having unsuspected neural, mycological or osteo-ligamentous relationships.^{10,15}

In conclusion, the origin of the profunda femoris artery in our study is placed slightly proximal than the other studies (Samarawickrama et al., Dixit et al., Prakash et al.).⁴⁻⁶ However, the left profunda femoris originates more distally than the right profunda femoris which in most of the cases is contrast with findings of Samarawickrama et al.⁴ The lateral circumflex femoral artery and medial circumflex femoral artery commonly originates from the profunda femoris artery close to the origin of the profunda femoris artery. This knowledge is very valuable in preventing injury to these vessels during surgical procedures of the femoral triangle. Further study is necessary to identify gender differences to these arteries.

The knowledge of the site of origin of the profunda helps in avoiding iatrogenic femoral arterio-venous fistula while performing femoral artery puncture and it enable to identify the correct site of making incision for surgical exposure of the common femoral and profunda femoris junction.

References

1. Romanes GJ.1987. Cunningham's Manual of Practical Anatomy. Vol 1.Upper and Lower limbs, 15ed. Oxford University Press; 141p.
2. Kirk RM.2000.GeneralSurgicalOperations.4th ed. In Churchill Livingston; 542p.
3. Kaplan JL, Allen RJ.2000. A cost based comparison between perforator flaps and TRAM flaps. *Plast Reconstr Surg* 105(3):943-948.
4. Samarawickrama MB, Nanayakkara BG, Wimalagunaratna KWR, Nishantha DG, Walawage UB.2009. Branching pattern of the femoral artery a the femoral triangle: a cadaver study *Galle Medical Journal* 14(1):31-34.
5. Dixit DP, Mehta LA, Kothari ML.2001.Variations in the Origin and Course of Profunda Femoris. *Journal of Anatomical Society of India* 50(1):6-7.
6. Prakash, Jyoti K, Bhardwaj AK, Jose BA, Yadav SK, Singh G.2010. Variations in the origins of the profunda femoris, medial and lateral femoral circumflex arteries: a cadaveric study in Indian population. *Rom J Morphol Embryol* 51(1):167-170.
7. Lippert H, Pabst R.1985. Arterial variation in man, classification and frequency. *J F Bergmann-Verlag N Munch*; 416-20.
8. Hollinshead HW. 1969. Buttock, Hip joint and thigh, Profunda femoris artery. In: *Anatomy for surgeons: Vol. 3. The back and limbs.* 2nd ed. Hoeber Medical Division, Happer & Row Publishers, New York, Evanston and London; p 725-730.
9. Sahana.1964. Circulatory system, Profunda femoris artery In: *Human Anatomy* 1st ed. The Central Book Agency, Calcutta, India; p 245-261.
10. Standring S.2008. Pelvic girdle, Gluteal region and hip joint, Profunda femoris artery. In: *Gray's Anatomy, The*

- anatomical basis of clinical practice. 40th ed. Elsevier Churchill Livingstone; p 1379-1380.
11. LH Bannister, MM Berry, P Collins. 1995. Cardiovascular system. In: *Gray's Anatomy.* 38 Ed; Churchill Livingstone, Medical Division of Longman Group, UK Ltd; p1566-8.
12. P Siddharth, NL Smith, RA Mason, F Giron. Variational anatomy of the deep femoral artery. PMID: 3842043 [PubMed-indexed for MEDLINE].
13. Uzel M, Tanveli E, Yildirim M. Anatomical study of the origins of lateral circumflex femoral artery in the Turkish population. PMID: 19085859 [PubMed - indexed for MEDLINE].
14. Keen JA.1961. A study of the arterial variations in the limbs, with special reference to symmetry of vascular patterns. *American Journal of Anatomy* 108(3):245-261.
15. Balachandra N, Prakash BS, Padmalatha K, Ramesh BR.2011. Variation in the origin of the lateral circumflex femoral artery – a case report. *Anatomica Karnataka* 5:76-80.