

Variations in nerve supply of lumbricals of hand in North Indian population

Neelamjit Kaur^{1,*}, Jagdev Singh Kullar², Rajan Kumar Singla³

¹Associate Professor, Maharishi Markandeshwar Medical College & Hospital, Solan, Himachal Pradesh, ²Professor, Govt. Medical College, Amritsar, Punjab, ³Professor & HOD, Dept. of Anatomy, Govt. Medical College, Patiala, Punjab

*Corresponding Author:

Neelamjit Kaur

Associate Professor, Dept. of Anatomy, Maharishi Markandeshwar Medical College & Hospital, Solan, Himachal Pradesh
Email: neelamjit@yahoo.co.in

Abstract

Introduction: During evolution from lower animals to higher animals the hand has undergone a great revolution. Lumbricals of the hand produce flexion at metacarpophalangeal joint and extension at the interphalangeal joint thus helping in performance of precise work.

Material & Methods: The present study was conducted on 60 upper limbs of 30 well embalmed adult human cadavers at the Government Medical College, Amritsar. The whole course of the median and ulnar nerve and its branches in hand was traced.

Aim: Aim was to study the nerve supply of different lumbricals of hand.

Results: In the present study, variations from the normal pattern were found in the innervation of lumbricals. Besides the first two lumbricals, median nerve was innervating the third lumbrical in 3(5%) hands. Second lumbrical was supplied by two branches from median nerve in 2(3.3%) hands. We also found berretini communications between median and ulnar nerves in 6(10%) hands but it has been described earlier by the same authors in a different article.

Clinical Significance: The variation in innervation of lumbricals in hand and their incidence will aid the surgeon in avoiding iatrogenic complications and improve the success rate of surgeries performed on hand.

Keywords: Hand, Lumbricals, Median nerve, Ulnar nerve, Innervation.

Introduction

The hand is a prehensile organ and has several intrinsic muscles which are responsible for highly specialized and intricate movements that are characteristic of human hand. It is attributed to a great neuromuscular coordination and larger functional area for hand in motor and sensory cortices of the cerebral hemispheres. Among all the muscles of hand, the lumbricals though small in size have a significantly greater role to play in the intricate movements of fingers. Thus the magnitude of evolution of lumbricals of hand is an indirect index of civilization of human race. It may be attributed to the fact that lumbricals contributed to the grasping ability of human, hence during phylogeny there has occurred a great revolution in evolution of human hand. The precise movements which are required during its evolution are contributed by the lumbricals. Evolution of grasping ability of human being contributed by lumbricals may be attributed to ecological context of such skills in the frogs⁽¹⁾.

There are four lumbricals in each hand and are numbered I to 4 from lateral to medial side. The lumbricals take their origin in the palm from the four tendons of the flexor digitorum profundus and pass distally along the radial side of the corresponding metacarpophalangeal joints, in front of the deep transverse metacarpal ligament. Thus the first and second lumbrical muscles are unipennate, whereas third and fourth are bipennate. Two medial and two lateral

lumbrical muscles are innervated by the ulnar and median nerves, respectively⁽²⁾.

Each muscle forms a narrow tendon and runs in a fascial canal and on reaching the dorsal surface of the proximal phalanx, joins the radial margin of the dorsal digital expansion as the distal wing tendon.

A large number of variations ranging from absence^(3,4), origin⁽⁵⁾, hypertrophy⁽⁶⁾ and nerve supply⁽⁷⁾ of lumbricals have been described in the literature. This information may be of immense value for a surgeon doing surgery in the palm which gave us an impetus to study more precisely the innervation of the lumbrical muscles.

Material & Methods

The present study was conducted on 60 upper limbs of 30(M:F::28:2) well embalmed adult human cadavers at the Government Medical College, Amritsar, Punjab, India. The dissection of the palm was done meticulously to expose the lumbricals and their nerve supply as per the dissection steps given in Cunningham's Manual of Practical Anatomy⁽⁸⁾.

Skin of the hand was reflected. The aponeurosis was turned distally by separating its edges from thinner deep fascia covering thenar and hypothenar muscles and palmaris longus tendon was separated from surface of flexor retinaculum. Superficial palmar arch immediately deep to the palmar aponeurosis was exposed and the branches of the median and ulnar nerve between it and long flexor tendons were exposed. The lumbrical muscles were carefully isolated preserving

their nerve supply and taking care to dissect all the branches & show their anatomical relationships. Each nerve innervating a particular lumbrical was traced proximally to its origin from the parent nerve.

Observations

In 60 hands which were dissected, the following observations were made with respect to innervation of lumbricals. Innervation pattern of 55(91.6%) hands was normal. In 2(3.3%) hands (10MR, 14FR), the 2nd lumbrical was innervated by 2 branches coming from the lateral common palmar digital branch of median nerve and in 6 (10%) cases (Limb No. 4MR, 4ML, 11MR, 12MR, 14 FR, 30ML) we found communication between lateral common palmar digital branch of ulnar nerve and medial common palmar digital branch of median nerve known as **berretini communications** (already given in another article by same author). In 3(5%) hands (12MR, 14FR, 30MR), the 3rd lumbrical was supplied by the medial common palmar digital branch of median nerve. Variation of dual innervation of second lumbrical, berretini communication and innervation of third lumbrical by median nerve all were collectively present in right hand of a female cadaver(as shown in Fig. 1). All the variations were unilateral. There were no variations in the origin and insertion of lumbricals.

Table 1: Showing variations in nerve supply of lumbricals

S. No.	Variant	No. of limbs (Limb No.)
1.	Dual innervation of Second lumbrical by lateral common palmar digital branch of median nerve	2(10MR, 14FR)
2.	Berretini communication	6(4MR, 4ML, 11MR, 12MR, 14 FR, 30ML)
3.	Third lumbrical supplied by medial common palmar digital branch of median nerve	3(12MR,14FR,30MR)

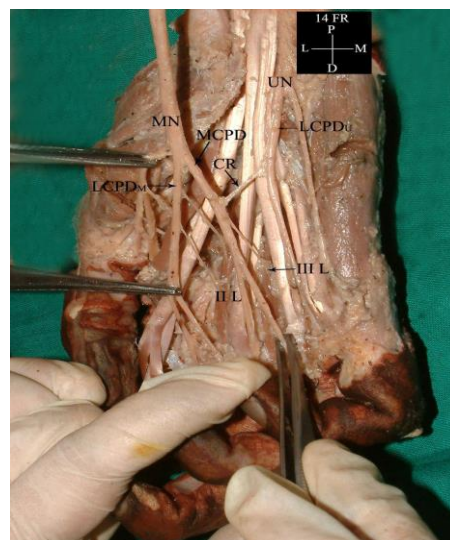


Fig. 1: Dual innervation of second lumbrical and Innervation of third lumbrical by median nerve (MN-Median nerve, UN-Ulnar nerve, MCPD-Medial common palmar digital nerve, LCPD-Lateral common palmar digital nerve, CR-Communicating ramus between digital branches of median nerve and ulnar nerve, II L-Second lumbrical, III L-Third lumbrical)

Discussion

Neurovascular structures in the hand are variable within a population & that anomalous cases occasionally be encountered. Gray⁽⁹⁾ agreed that in the hand the two outer lumbricals are supplied by the median, and the two inner by the deep branch of the ulnar nerve. Henle⁽¹⁰⁾ & Schwalbe⁽¹¹⁾ consider the above arrangement to be the rule in the hand, but mentions that the third (annular) lumbrical may be supplied by the median, and that the fourth lumbrical may receive its nerve from the superficial division of the ulnar. Brooks⁽¹²⁾ have found, however, the third lumbrical of the hand receiving a twig from the median in twelve out of twenty-one cases; in nine cases (out of the twelve) the third lumbrical also received a twig from the deep branch of the ulnar.

It has been mentioned that innervation to second lumbrical was inconstant, sometimes derived from deep ulnar & sometimes having a double supply⁽⁷⁾. In the study by Afroze et al⁽⁷⁾, normal pattern was found in 57 hands (95%). The median nerve supplied the 1st lumbrical in all cases. In Mehta & Gartner's series⁽¹³⁾ the median nerve supplied 1st & 2nd lumbricals in all cases. In 3 hands (5%), branch to 3rd lumbrical came from median nerve (via medial common palmar digital branch of median nerve).

Rabischong⁽¹⁴⁾ noted that the lumbrical muscles have the greatest density of mechanoreceptors than any other muscle, & proposed that they play a critical role in proprioception in addition to their function as IP joint extensors.

Clinical Significance: Past research studies have reported the fact that variant nerve shearing abnormal origin, course and distribution are more prone to accidental injuries and entrapment neuropathies. During surgical procedures of hand, a surgeon is exposed to topographical anatomy of the neural structures and awareness of variations may be of immense clinical help. Better understanding and correct interpretation of clinical neurophysiology can only be possible with prior academic knowledge⁽¹⁵⁾. The variations and their incidence will aid the surgeon in avoiding iatrogenic complications and improve the success rate of median nerve decompressions. Clinicians and hand surgeons should be aware of such variations in innervations of lumbricals while dealing with the hand during various surgical procedures.

Summary & Conclusion

In the present study, though we observed presence of lumbricals with their normal attachment and morphology in all the cases, variations in innervation of third lumbrical and dual innervations of second lumbrical were encountered. These variations have a lot of clinical implications. Therefore, clinicians and hand surgeons should be aware of variations in nerve supply of lumbricals while interpreting variant symptomatology and during various surgical procedures of hand respectively. Hence, a complete knowledge of possible variations of lumbricals is utmost essential.

References

- Manzano AS, Abdala V & Herrel A(2008). "Morphology and Function of the Forelimb in Arboreal Frogs: Specializations for Grasping Ability?" *J. Anat*, 213(3):296-307.
- Lauritzen RS, Szabo RM, Lauritzen DB. Innervation of the lumbrical muscles. *J Hand Surg Br*. 1996;21:57-58.
- Braithwaite F, Channel GD, Moore FT & Willis J (1948). 'The Applied Anatomy of the Lumbrical and Interosseous Muscles of the Hand,' *Guy's Hosp. Reports*, 97,185-95.
- Kurzumi M, Karwai K, Honma S & Kodama K (2002). "Anomalous Lumbrical Muscles Arising from the Deep Surface of Flexor Digitorum Superficialis Muscles in Man," *Ann Anat*, 184(4):387-92.
- Siegel DB, Kuzma G & EakinsD (1995)."Anatomic Investigation of the Role of Lumbricals Muscle in Carpal Tunnel Syndrome," *J. Hand Surg (Am)*,20(5):860-3.
- Singh JD, Raju PB & Singh Shamer. (1975). 'Anomalous Insertion of Hand Lumbricals,' *J Anat Soc India*,24(3):122-5.
- Afroze MKH, Aswinpraksh, Ramesh P., Vaithianathan G, Balaji TK, Judson JP. Variation in Innervation of lumbricals of hand. *Int J Innov Res & Dev*; May,2014. Vol-3(5);243-246.
- Romanes GJ. The pectoral region and the axilla, the arm and the forearm and the hand. In: *Cunninghams Manual of Practical Anatomy*.15th Edition. Edinburgh, London: The English Language Book Society and Oxford University Press;1986;1,28-89.
- Standring S. (2005). *Gray's Anatomy*, 39th Ed. Edinburgh: Elsevier Churchill Livingstone, 1021-3.
- Henle-Nervenlehre, 1879, p. 593.
- Schwalbe-- *Neurologie*, 1881, p. 977.
- Brooks HS J. Variations in the nerve supply of the lumbrical muscles in the Hand & Foot, with some observations on the innervation of the perforating flexors, *J Anat Physiol*887;21(4);575-585.
- Mehta HJ & Gardner WU (1961). "A Study of Lumbrical Muscles in the Human Hand," *Am. J. Anat*, 109, 227-238.
- Rabischong P. (1962). L' innervation proprioceptive des muscles tombricauxde la main chez l'homme. *Revue de Chirurgie Orthopddique*,48:234~45.
- Das S, Paul S. Anomalous branching pattern of lateral cord of brachial plexus. *Int J Morphol* 2005;23(4):282-292.