

## ANATOMY OF NUTRIENT FORAMEN OF TIBIA – A STUDY FROM GUJARAT REGION

Chirag R Vadhel<sup>1</sup>, Manoj M Kulkarni<sup>2</sup>, Achleshwar R Gandotra<sup>3</sup>

<sup>1</sup>Tutor, <sup>2</sup>Associate Professor, <sup>3</sup>Professor, Dept. of Anatomy,  
SBKS Medical Institute & Research Center, Piparia, Vadodara (Gujarat)

**\*Corresponding Author:**

E-mail: drmanojkulkarni999@gmail.com

---

### ABSTRACT

**Background:** Preservation of vascularity of tibia is of paramount significance during its surgical interventions. Lack of studies from Gujarat region on nutrient foramen of tibia prompted authors to undertake this study.

**Material & Methods:** 188 dry tibias from tertiary care hospital of Gujarat were examined for nutrient foramina location, number, direction & its relation to other bony landmark.

**Results:** Single nutrient foramen directed downwards was the rule. The location of nutrient foramen closely resembled with the data of previous similar studies done in other parts of the world.

**Conclusion:** The present study generated database for nutrient foramen of tibia from Gujarat region. This can be utilized by surgeons to preserve nutrient artery during operations for fracture repair, tumor and bone grafts involving tibia.

**Key words:** bone graft, fracture repair, nutrient artery, nutrient foramen, tibia, vascularity.

---

### INTRODUCTION

All long bones in the body are supplied by a single nutrient artery in majority of cases which enters the bone in the diaphysis. The nutrient artery is supplemented by epiphyseal, metaphysical and periosteal vessels in providing blood supply to the long bones. The nutrient artery to the tibia is a branch of posterior tibial artery or peroneal artery. It supplies the inner two-thirds of the cortex and is the chief blood supply of cortical bone.<sup>1</sup>

The nutrient artery enters the shaft of the tibia generally in its upper one third; this arrangement deprives the nutrition to the lower one third of shaft, thus making the lower one third of tibia more liable to undergo nonunion in the event of fracture<sup>2</sup>.

The knowledge of location of nutrient foramen in long bones is of paramount importance to the surgeons as minimal interference with the vascularity of the bone during surgical procedures or during fracture repairs will improve the surgical outcome substantially.<sup>3-6</sup>

Many studies have been done in the past to find out the number, location and direction of nutrient foramina of tibia. Majority of those studies have been done in either

western population or Indian population outside Gujarat.<sup>7-10</sup>

Present study was undertaken to generate the data on exact location of nutrient foramen in tibia from Gujarat region and to compare the findings with the similar studies done in other parts of the world.

### MATERIAL & METHODS

The present study was conducted on dry specimen of tibia from the department of Anatomy of tertiary care hospital & medical college from Gujarat region. Side determination of the dry tibia was done using existing universally accepted criteria. The Sliding Vernier caliper (resolution = 0.05mm) was used for all the distance measurements. All the observations were made by two separate observers in order to avoid observer bias.

Following observations were made on each tibia:

- 1) Number of nutrient foramina
- 2) Situation of nutrient foramina in tibia (in reference to upper, middle or lower one-third of the shaft)
- 3) Direction of the nutrient foramina (upward/downward)

- 4) Location of nutrient foramen in reference to Soleal line on posterior surface of tibial shaft (Medial/Lateral to Soleal line)
- 5) Horizontal distance of Nutrient foramen from the Soleal Line.

All the observations were tabulated and analyzed by using SPSS software.

## RESULTS

The present study was done on 188 dry tibias (94 Right & 94 Left) of both the sexes from the department of Anatomy of

tertiary care hospital in Gujarat. In all the samples single nutrient foramen was found on the posterior surface of the shaft. We noticed that in 174 (92.6%) tibia the nutrient foramen was located on the shaft in its upper one third (Table 1). Only in 1 tibia it was positioned in middle one third of the shaft. In all 188 tibias the direction of nutrient foramen was observed to be downward towards its lower end. The location of nutrient foramen when compared with Soleal line, we determined that in 180 (95.7%) tibia it was located lateral to the Soleal line (Table 2).

**Table 1: Location of nutrient foramen in the tibia**

	Sample size	Location of nutrient foramen on shaft		
		Upper 1/3	U 1/3 & M 1/3 Junction	Middle 1/3
Right Tibia	94	88	06	00
Left Tibia	94	86	07	01
Total	188	174	13	01
Percentage	100%	92.6%	6.9%	0.5%

**Table2: Direction & relation of Nutrient Foramen (NF) with Soleal line(SL) on tibia**

	Direction of NF		Relation of NF with Soleal line		
	Upward	Downward	Medial to SL	Lateral to SL	On SL
Right Tibia	00	94	00	94	00
Left Tibia	00	94	00	86	08
Total	00	188 (100%)	00	180 (95.7 %)	08 (4.3 %)

**Table 3: Distance of nutrient foramen from Junction of Upper 1/3 & Middle 1/3 of shaft**

	Sample size	Mean distance of NF from U/M Junction in mm(Range)	Mean distance of NF from Soleal line in mm(Range)
Right Tibia	88	18 ± 7.4 (5 to 35)	13 ± 3.2 (6 to 19)
Left Tibia	86	18.5 ± 9.2 (1 to 33)	9.1 ± 3.9 (0 to 18)

As the nutrient foramen was located in upper one third of shaft of tibia in >90% of the cases, we decided to exclude the rest of the tibias from the total sample size for the further calculations. In the remaining tibias, the exact distance of the nutrient foramen was measured from two landmarks: i) the junction of upper & middle one third of the shaft; ii) the Soleal line. We discovered that (Table 3) the nutrient foramen was located on posterior surface of shaft: i) In right tibias at an average distance of 18 mm (± 7.4) above the junction of upper & middle 1/3<sup>rd</sup> of the shaft and 13 mm (± 3.2) ii) In left tibias at an average distance of 18.5 mm (± 9.2) above the junction of upper & middle 1/3<sup>rd</sup>

of the shaft and 9.1 mm (± 3.9) lateral to Soleal line.

## DISCUSSION

The nutrient artery plays cardinal role in blood supply of a long bone. The nutrient artery to tibia is derived from posterior tibial artery near its origin. It is one of the largest of the nutrients arteries. Rhinelandert al (1972) have reported that the nutrient artery to the tibia supplies the inner two-thirds of the cortex and is the chief blood supply of cortical bone.<sup>1</sup>

A single nutrient foramen on the shaft of the tibia is a common observation

of the past studies. Few researchers have also reported the double diaphysial nutrient foramen on the tibia as a rare occurrence<sup>11</sup>. In the present study, a single nutrient foramen on shaft was a rule in all 188 tibias. All of these nutrient foramina were directed downwards towards the lower end of the tibia. The nutrient foramen was

located in upper one third of tibial shaft in 92.6% of the present study sample. Thus our study shows that the data from Gujarat region on location of nutrient foramen of tibia is in concurrence with many previous studies done in the different parts of the world (Table 4).<sup>7, 9, 11-14</sup>

**Table 4: comparison with previous studies for location of nutrient foramen of tibia**

Studies(Yr)	Region	Sample size	Location of Nutrient foramen on shaft		
			U 1/3	M1/3	U/M Junction
Mysorkar(1967)	India (Poona)	180	78.30%	21.60%	0.10%
Longia(1980)	India (Zansi)	210	91.90%	8.10%	0%
Kirschner (1998)	Germany	200	93.50%	6.50%	0%
Collipal(2007)	Chile	50	100%	0%	0%
Gandhi (2013)	India (North)	100	100%	0%	0%
Tejaswi H. L.(2014)	India (Karnataka)	150	94.90%	5.10%	0%
<b>Present Study</b>	India (Gujarat)	188	92.60%	6.90%	0.50%

The nutrient foramen was situated lateral to Soleal line >95% of the present study samples. None of the nutrient foramen was lying medial to Soleal line.

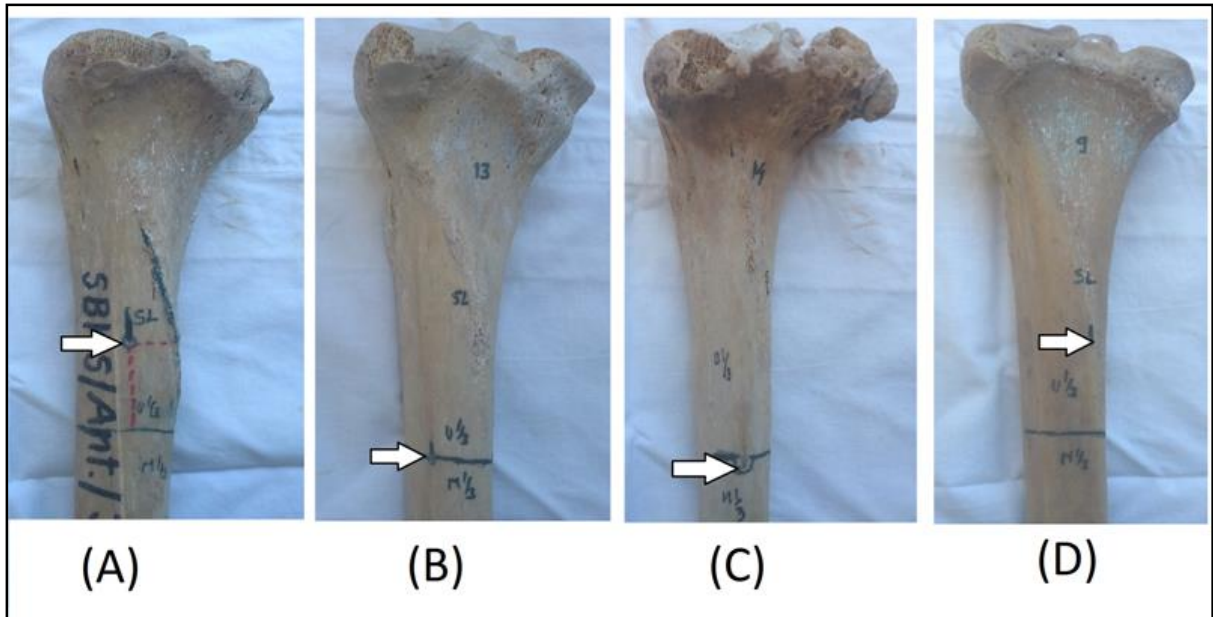
This finding about relation of nutrient foramen with Soleal line reaffirms the observations made by previous researchers (Table 5).<sup>9, 12, 15, 16</sup>

**Table 5: Comparison with previous studies for relation of nutrient foramen of tibia with Soleal line**

Studies(Yr)	Region	Sample size	Location of Nutrient foramen on shaft	
			Lateral to SL	On SL
Collipal(2007)	Chile	50	94.33	3.77
Murlimanju BV (2011)	India	69	66	02
Ankolekar (2013)	India (Karnataka)	50	35	7
Tejaswi H. L.(2014)	India (Karnataka)	150	91.21	1.37%
<b>Present Study</b>	India (Gujarat)	188	95.7%	4.3%

The knowledge of exact location of nutrient foramen of tibia is highly useful for the surgeons who perform fracture repair or are involved in surgical interventions of tibia. So we measured the distance of nutrient foramen from junction of upper & middle 1/3<sup>rd</sup> of the shaft and the Soleal line. For this the tibias with nutrient foramen in upper one third of shaft were only included. The findings are shown in Table 3.

This data will enable the surgeons to efficiently avoid the damage to the nutrient artery of tibia during surgical procedures involving this region which can have significant impact on overall recovery of patient. The data can also be of great significance for surgeons involved in free vascular bone graft surgeries.<sup>17, 18</sup>



**Image 1: Situation of nutrient foramen on tibia (A) In upper 1/3<sup>rd</sup> of shaft; (B) At junction of Upper and Middle 1/3<sup>rd</sup> of shaft (C) In middle 1/3<sup>rd</sup> of shaft (D) On Soleal line**

## CONCLUSION

The present study reconfirms that the nutrient artery to tibia enters into upper 1/3<sup>rd</sup> of its shaft on its posterior aspect lateral to Soleal line in > 90% of the cases. Clinical procedures involving this

area shall be done with extreme care to preserve the chief blood supply of tibia. The data from Gujarat region about number, direction & location of nutrient foramen of tibia closely resembles the data from other parts of the world.

## REFERENCES:

1. Rhinelander FW (1972): Circulation of bone. In: Bourne GH, ed. The Biochemistry and Physiology of Bone. 2nd ed. Vol. 2, Physiology and Pathology. New York. etc: Academic Pres; 1972 :2-77.
2. Dickson K1, Katzman S, Delgado E, Contreras D. Delayed unions and nonunions of open tibial fractures. Correlation with arteriography results. Clin Orthop Relat Res. 1994 May;(302):189-93.
3. Forriol F, Gomez L, Gianonatti M, Fernandez R A study of the nutrient foramina in human long bones. Surg Radiol Anat (1987) 9: 251-255
4. McKee NH, Haw P, Vettese T. Anatomic study of the nutrient foramen in the shaft of the fibula. Clin Orthop (1984); 184: 141-144
5. Osterman AL, Bora FW. Free vascularized bone grafting for large-gap non-union of long bones. Orthop Clin North Am (1964); 15: 157-163
6. Trueta J. Blood supply and the rate of healing of fractures of the tibia. Clin Orthop (1974); 105: 11-26
7. Mysorekar VR. Diaphysial nutrient foramina in human long bones. J Anat (1967); 101: 813-822.
8. Cizek B & Glinkowski W. Nutrient foramina in the diaphyses of long bones. Orthop Traumatol Rehabil (2000); 2: 97-9.
9. Tejaswi, H. L., Krishnanand Shetty, and K. R. Dakshayani. Anatomic Study of Nutrient Foramina in the Human Tibiae and Their Clinical Importance. (2014); 9(3); 334-336
10. Sendemir E, Cimen A. Nutrient foramina in the shafts of lower limb long bones: situation and number. Surg Radiol Anat (1991); 13: 105 - 108.
11. Kirschner MH, Menck J, Hennerbichler A, Gaber O & Hofmann GO. Importance of arterial blood supply to the femur and tibia transplantation of vascularised femoral diaphyseal and knee joints. World J Surg (1998); 22: 845-52.
12. Collipal E, Vargas R, Parra X, Silva H and Sol MD. Diaphyseal nutrient foramina in the femur, tibia and fibula bones. Int J Morphol (2007); 25(2):305-308.
13. Longia GS, Ajmani ML, Saxena SK and Thomas RJ. Study of diaphyseal nutrient foramina in human long bones. Acta Anat(1980); 107:399-406
14. Swati Gandhi, Rajan K Singla, Rajesh K Suri, Vandana Mehta. Diaphyseal nutrient foramina of adult human tibia – Its positional anatomy and clinical implications. Rev Arg de Anat Clin (2013); 5 (3): 222-228

15. Ankolekar, Vrinda Hari, Lydia S. Quadros, and Antony Sylvan D'souza. "Nutrient Foramen in Tibia–A Study in Coastal Region of Karnataka." *IOSR Journal of Dental and Medical Sciences* (2013); 10(3) 75-79.
16. Murlimanju, B. V., et al. "Morphological and topographical anatomy of nutrient foramina in human upper limb long bones and their surgical importance." *Rom J Morphol Embryol* (2011); 52(3):859-862.
17. Sendemir E, Cimen A.. Nutrient foramina in the shafts of lower limb long bones: situation and number. *Surg Radiol Anat* (1991); 13: 105 - 108.
18. Gumusburun E, Yucel F, Ozkan Y, Akgun Z. A study of the nutrient foramina of lower limb long bones. *Surg Radiol Anat* (1994); 16: 409-412.