

“Primary Grynfeltt’s - lumbar hernia” – a rare case

Chaudhary Ramkaran^{1,*}, Brijendra Singh²

¹Assistant Professor, Dept. of Surgery, ²Additional Professor, Dept. of Anatomy, AIIMS, Jodhpur, Rajasthan

***Corresponding Author:**

Chaudhary Ramkaran

Assistant Professor, Dept. of Surgery, AIIMS, Jodhpur, Rajasthan

Email: rkmoond@gmail.com

Abstract

Introduction: Primary lumbar hernias although are rare hernias but causes of lumbar hernia may be classified as congenital or acquired, primary or secondary. Lumbar hernias are very uncommon among abdominal wall hernias and very few cases have been reported in the literature.

Presentation of case: An old male patient aged about fifty years presented in surgical OPD with complaints of a swelling in left flank region which used to increase in size after standing or physical activities. He was examined thoroughly and it was found to be a reducible hernia on left lumbar region. Patient was advised needful investigations like Ultrasound and CT scan and a diagnosis of primary lumbar hernia was established. This hernia was approached through laparoscopic transabdominal extra peritoneal repair and patient had uneventful post-operative period.

Discussion: There are various techniques described in literature about the repair methodologies of lumbar hernia but the minimally invasive techniques are supposed to be far superior in many aspects as compared to open surgical repairs.

Conclusion: For primary spontaneous lumbar hernias minimally invasive techniques are preferred over open surgical techniques due to their obvious advantages.

Key words: Grynfeltt’s- Lesshaft hernia, primary lumbar hernia, Transabdominal extra peritoneal repair, Laparoscopy.

| Access this article online | |
|---|--------------------------------|
| Quick Response Code: | Website: |
|  | www.innovativepublication.com |
| | DOI: |
| | 10.5958/2394-2126.2016.00088.8 |

Introduction

Lumbar hernias are very uncommon among abdominal wall hernias, about 250 to 300 cases have been reported in literature. These rare hernias are classified on various grounds – like anatomical or according to occurrence in age congenital or acquired lumbar hernias. Anatomically they are classified as Grynfeltt’s- Lesshaft hernia presenting through superior lumbar triangle bounded by inferior edge of 12th rib superiorly, by erector spinae muscle medially and internal oblique muscle laterally or Petit’s hernia presents through inferior lumbar triangle which is bounded by iliac crest inferiorly, by latissimus dorsi medially and by external oblique muscle laterally.

Twenty percent of lumbar hernias are congenital and the remaining eighty percent are acquired. Acquired lumbar hernias may be further sub classified into either primary hernias -spontaneous or secondary hernias - either iatrogenic, traumatic or infectious. Though rare defects, but lumbar hernias have 25 percent risk of incarceration and a more than 8% chance of strangulation. As lumbar hernias are rare, differential diagnosis with a lipoma, a soft tissue tumour, a

panniculitis and a muscle hernia must be kept in the mind.

Case Report

A 50 year old male patient visited in our outpatient department with chief complain of swelling in left flank for last 3 years (Fig. 1). Patient gave history about increase in the size of swelling and associated discomfort due to strenuous activity and coughing. The patient was habitual and chronic smoker for last 20 years. There was no history of haematuria, loss of appetite, local trauma, previous local surgery or infection.

On physical examination there was diffuse swelling of about 5x5 cm in left flank region and cough impulse was found positive. The swelling was non tender, non-pulsatile and the overlying skin was normal. Rest of the systemic examination was within normal limits. Ultrasonography demonstrated a defect of about 1.1 cm in left lumbar region, on Valsalva echogenic enhancement, fat as a content was herniating through it. Contrast enhanced abdominopelvic CT scan showed extra peritoneal fat herniation through the left lumbar region defect (Size 2.5 x 2 cm). Hence clinical diagnosis of primary Grynfeltt’s hernia was confirmed and after proper anaesthetic work-up of the patient, operation was planned by laparoscopic method and mesh repair under general anaesthesia.

During laproscopic mesh repair patient was positioned in modified flank position (Patient in right lateral position with 60° inclination to the operating table). Pneumoperitoneum was created by closed method with the help of Veress needle. A 10 mm camera port

was placed just lateral to umbilicus and two 5 mm working ports were also placed, one below left costal margin and second in left iliac fossa, (Fig. 3). Peritoneal mobilization was started along the line of Toltd and retroperitoneal dissection was done. The hernia defect was identified (size about 2.5x2.0 cm) (Fig. 4). Extra peritoneal fat was seen to be herniating through this defect. The hernial contents were reduced and margins were well defined. A 10 x10 cm polypropylene mesh was fixed with the help of tackers (Fig. 5). Reperitonealisation was completed and port sites were closed. Patient was advised to be on liquid diet on the evening of surgery and was discharged on fourth postoperative day. At follow up of three months patient is healthy asymptomatic and fine without any complaints.

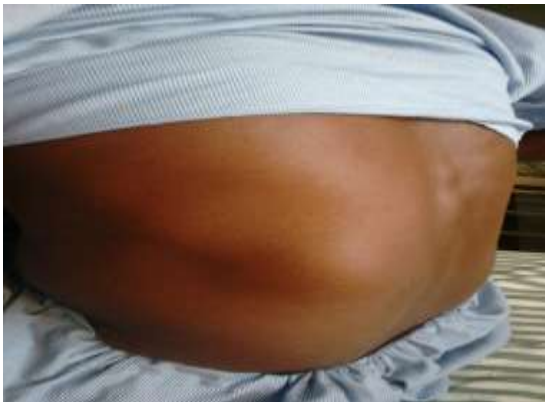

Fig. 1: Swelling in left flank region

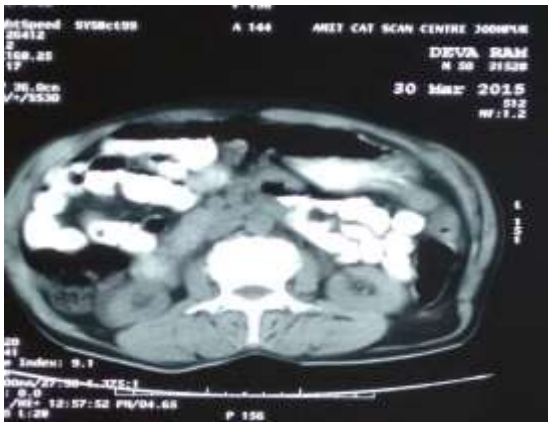

Fig. 2: CECT abdomen showing left lumbar hernia

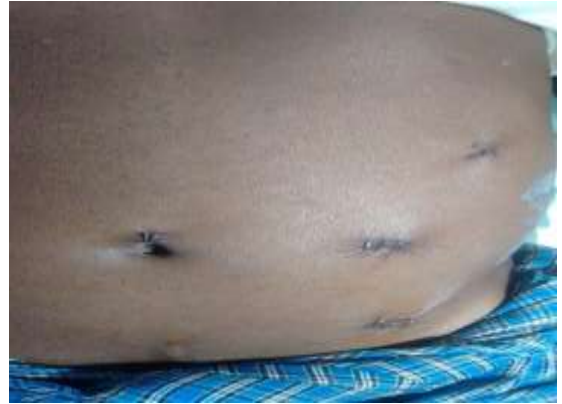

Fig. 3: Port placements

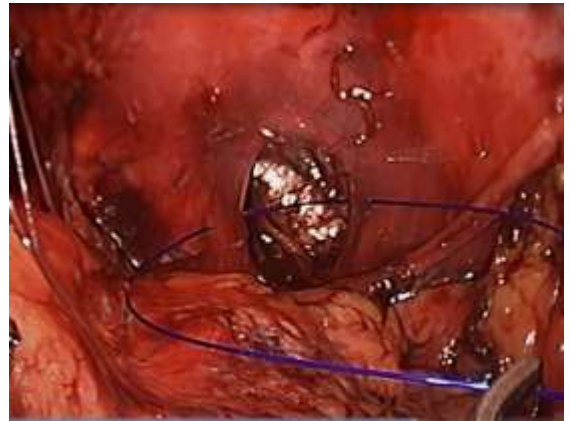


Fig. 4: Hernial defect (about 2.5X2.0 cm)



Fig. 5: Polypropylene mesh (10x10 cm) fixed with tackers

Discussion

Lumbar hernias occur in two weak areas of the posterolateral abdominal wall: the superior lumbar triangle of Grynfeltt, and the inferior lumbar triangle of Petit. The superior lumbar triangle is inverted triangle bounded by the 12th rib as base and lower edge of the serratus muscle; by the sacrospinal muscle on the posterior side; by the internal oblique muscle anteriorly; roof is formed by external oblique and latissimus dorsi; and the floor is formed by fascia transversalis. The

inferior lumbar triangle is formed by the crest of the iliac bone at the base, the external oblique muscle laterally, and the latissimus dorsi muscle medially; the floor is formed by the internal oblique muscle.⁽⁴⁾

Lumbar hernias may be acquired or congenital. The percentage of congenital (20%) and acquired hernias (80%) has not varied with time, although the etiological factors of acquired lumbar hernias have changed indeed, as infectious hernias have decreased considerably (from 17% to 2%), whereas incisional hernias have increased from 10% to 30%.⁽⁴⁾

Predisposing factors in spontaneous acquired lumbar hernia are age, obesity, extreme thinness, chronic debilitating disease, muscular atrophy, intense slimming, chronic bronchitis, wound infection, and postoperative sepsis. They are also usually associated with strenuous physical activity. A reducible mass in the flank region is usually most common mode of presentation. It may be associated with mild pain.

The diagnosis of lumbar hernia is based primarily on clinical presentation, examination and evaluation of the patient. Contrast enhanced CT should be done preoperatively if feasible because it defines the anatomical relationship of lumbar areas, differentiating muscular atrophy from a real hernia, identifying the contents, and ruling out the possibility of a tumor by facilitating a more rational therapeutic decision.⁽⁵⁾

There are various techniques for lumbar hernia repair described in literature. They include open as well as laparoscopic approach. The transabdominal laparoscopic approach was introduced by Burick and Paracandola in 1996⁽⁶⁾. We performed a transabdominal extra peritoneal mesh repair. A similar technique has been described by A. Sharma et al. in 2005⁽⁷⁾. The advantages of laparoscopic approach are shorter length of hospital stay, lower consumption of analgesics, earlier return to normal activity and less chances of wound infection.

Conclusion

Lumbar hernia is a rare clinical entity that requires high index of suspicion. A clinical workup should always include contrast enhanced CT abdomen if feasible to delineate the better anatomy and content. For primary spontaneous lumbar hernias minimally invasive techniques are preferred over open surgical techniques due to their obvious advantages.

References

1. Shiki S., Kuwata Y., Kashihara E., Ueda U. Fuchimoto S., Orita K. A case of Superior Lumbar hernias. *Jpn J Surg.* 1991;21:696-9.
2. Suarez S, Herrrandez JD: Laparoscopic repair of a lumbar hernia: report of a case and extensive review of the literature. *Surg Endosc* 2013,27(9):3421-3429.
3. Heniford BT, Lanniti DA, Gagner M Laparoscopic inferior and superior lumbar hernia repair. *Arch Surg* 1997;132:1141.

4. Moreno-Egea A, Baena EG, Calle MC, Martinez JA, Albasini JI. Controversies in the current management of lumbar hernias. *Arch Surg* 2007;142:82-8.
5. Faro SH, Racette CD Lally JF, et al. Traumatic lumbar hernia: CT diagnosis. *AJR Am J Roentogenol.* 1990;154:757-759.
6. Burick Aj, Parasascandola S. Laparoscopic repair of a traumatic lumbar hernia: a case report. *J Laparoendosc Surg.* 1996;6:259-262.
7. A. Sharma. et.al. Laparoscopic transabdominal extraperitoneal repair of lumbar hernia. *J of Minimal Access Surgery.* June 2005;1:70-73.