

A digital image analysis method for measuring femoral neck shaft angle and anteversion angle: A pilot study

Lakshmi Verma^{1,*}, Sumit Gupta², Tuhin Ghulyani³, Pratima Jaiswal⁴

¹PG Resident, ²Assistant Professor, ³Senior Demonstrator, ⁴Professor & HOD, Govt. Medical College, Kota, Rajasthan

***Corresponding Author:**

Lakshmi Verma

PG Resident, Govt. Medical College, Kota, Rajasthan

Email: dr.lakshmi.verma@gmail.com

Abstract

Femur is widely studied in the fields of orthopedics, anthropology, forensic and human kinematics. This study aims to measure neck-shaft angle (NSA) and anteversion angle (FNA) in adult dry femora using digital image analysis software 'ImageJ'. A total of 100 (50 right and 50 left) intact human adult femora were studied. The data was analyzed using SPSS software. The mean NSA and FNA in femora (n=100) was $124.95 \pm 6.09^{\circ}$ & $13.45 \pm 8.58^{\circ}$ respectively. The mean NSA in left and right femora was $125.12 \pm 5.22^{\circ}$ & $124.78 \pm 6.9^{\circ}$ respectively. The mean FNA in left and right femora was $12.9 \pm 8.22^{\circ}$ & $14 \pm 8.98^{\circ}$ respectively. There was no significant side difference in both NSA and FNA. The mean NSA was lower than most of the western studies but it was comparable with most other Indian studies and also Japanese studies. Though the mean FNA was within the range of previous Indian studies but is higher than most other observations. We attribute these numerical differences to different morphometric techniques and measuring points.

Keyword: Femur, Neck Shaft Angle, Anteversion Angle

Access this article online	
Quick Response Code:	Website: www.innovativepublication.com
	DOI: 10.5958/2394-2126.2016.00083.9

Introduction

Femur is widely researched in fields of orthopedics, anthropology, forensic and human kinematics. Orthopedics research involves morphometric analysis of femur for joint studies in order to design intramedullary fixators and define the axes for orthopedic surgery⁸. Among various parameters studied are femoral neck-shaft angle (NSA) and femoral anteversion angle (FNA).

NSA allows greater mobility of the femur at the hip joint because it places the head and neck more perpendicular to the acetabulum in the neutral position. The larger the NSA and/or longer the femoral neck, the greater is the bending moment acting on the femoral neck and thus greater is the risk for femoral fracture³³. It is found that a lower NSA may result in elevated risk of greater trochanteric pain syndrome (GTPS) in females^{12,52} and said to predispose to stress fractures³². The large discrepancy in NSA is one of the main diagnostic criterion that clinicians use to detect femoral neck fracture.⁵² Hence NSA is a possible pathogenic indicator of some hip disorders. Therefore identifying normal ranges of the parameters and their influencing factors may help surgeons to perform hip surgeries

better and predict the risk of hip disorders or injury such as pre-operative planning of osteotomy, arthroplasty or fracture fixation¹⁵.

The femoral anteversion angle (FNA) is widely recognized as an important factor for hip stability and normal walking. Excessive FNA is associated with restricted external rotation and tendency for in-toeing⁵⁶. Abnormal FNA sometimes can be associated with many clinical problems such as osteoarthritis, developmental dysplasia of the hip and impingement instability and wear in total hip arthroplasty.

Various methods have been devised to measure NSA and FNA in living subjects such as Computed tomography, ultrasonography, MRI, radiography and physical examination. For their measurement in dry bone some have used goniometer and few others have used radiographs. Here we propose a novel method to measure these angles based on computerized 'ImageJ software'³⁷ analysis of digital image of femur bone. Thus this study contributes to Indian data on these parameters.

Materials and Methods

A total of 100 (50 right and 50 left) intact human adult femora from department of Anatomy, Government Medical College, Kota, Rajasthan were studied. Any femora having gross deformities or damage were excluded from this study.

To measure the FNA digital image of end on view of proximal end of femur was taken. Each femur was placed flat on the horizontal surface of the osteometric board lying on posterior surface of its condyles and greater trochanter. To measure the NSA frontal view of

femur was taken. In order to increase the accuracy of the NSA measurement, the femoral anteversion was negated by manually rotating the proximal end of femur. The pictures thus taken were transferred to the computer and analyzed using ImageJ software.

Image Analysis in ImageJ Software: (Fig.)

1. Center of the femoral head: It was defined as the center of the circle best fit for the femoral head.
2. Center of neck: It was defined as the midpoint of the narrowest part of the neck.
3. The head-neck axis: A line was drawn from the center of femoral head and passing through the midpoint of femoral neck.
4. Retrocondylar axis: It is represented by the horizontal plane of the osteometric board and hence a horizontal line in ImageJ software.
5. Femoral Shaft axis: it is represented by joining following two centre points on the anterior surface of the shaft.
 - a. First at the proximal end of femur where the intertrochanteric line ends.
 - b. Second one at the midway between both the ends of the femur.
6. FNA: The angle between the head-neck axis and retrocondylar axis.(Fig. 1)
7. NSA: The angle between the head-neck axis and the femoral shaft axis.(Fig. 2)




Fig. 1: Analysis of the digital image by 'ImageJ software' for FNA

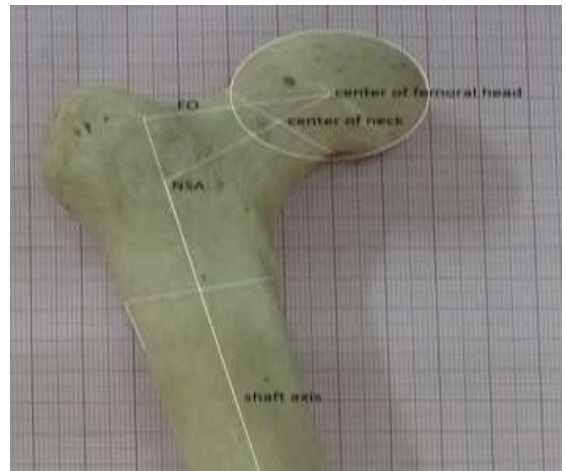


Fig. 2: Analysis of the digital image by 'ImageJ software' for NSA

Statistical analysis was done by using SPSS (version 20.0) and Microsoft Excel (version 2007) software. Data was analyzed for normal distribution using the Kolmogorov-Smirnov test. Results are presented as Mean±SD, 95% confidence interval and range values. Unpaired t-test was used to compare two groups (Right vs Left).

Results

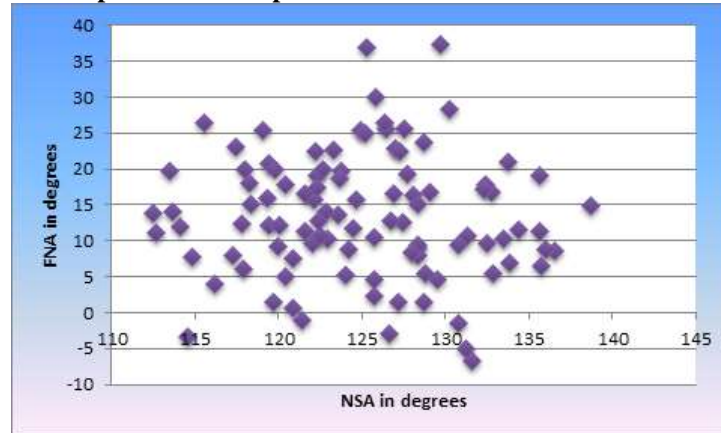
Table 1: Showing the results of parameters (n=100 femurs)

S.no	Parameter n=100	Mean ± SD	Minimum	Maximum	UL and LL (95% CI)
1	NSA in degrees	124.95±6.09	112.47	138.75	123.76 to 126.14
2	FNA in degrees	13.45±8.58	-6.67	37.41	11.77 to 15.13

Table 2: Comparison of results in right and left side

Parameter (n=50)	Side	Mean \pm SD	Minimum	Maximum	UL and LL (95% CI)
NSA in degrees	Lt	125.12 \pm 5.22	113.46	135.97	123.67 to 126.57
	Rt	124.78 \pm 6.9	112.47	138.75	122.87 to 126.69
FNA in degrees	Lt	12.9 \pm 8.22	-6.67	37.41	10.62 to 15.18
	Rt	14 \pm 8.98	-5.09	36.87	11.51 to 16.49

Results of unpaired t-test showed no significant difference in left and right side in both NSA and FNA. ($p > 0.05$)

Graph 1: A scatter plot of NSA and FNA for each femur

Discussion

The average NSA in the present study is 124.95°. Amongst the foreign workers, our results were comparable with the results of authors who worked on Japanese population i.e. Kiyono K (124.6°)¹⁸, Sugano et al (126°)⁵¹, Maruyama et al (125°)²⁸; Korean author i.e. Khang et al (125.6°)¹⁶; and also. Wright et al (124.2°)⁵⁷ who worked on Netherland population i.e. but only one western worker obtained comparable results i.e. Noble et al (124.7°)³¹. The mean NSA obtained in the present study was lower than most of the western studies. Whereas Umebese (121.0°)⁵⁵, macho (121.9°)²⁴ and Rubin et al⁴³ (122.9°) obtained lower values.

This study was done in western Indian region and mean NSA is comparable with most other Indian studies. Whereas KC Saikia⁴⁴ (139.5°) using CT method; Shakil M khan⁴⁷ (137.1°) & Subhash gurjar⁵⁰ (136.3°) working on dry bone reported higher values. Kaur P¹⁴ while working in Punjab region reported lower value of 121°.

Table 3: Comparison of NSA with other foreign studies (T-Total, M-male, F-female, R-right, L-left)

S. No	Authors	Year	Sample size	Population	Method	NSA
1	Parsons ³⁴	1924	134	British	Dry bone-Mechanical	126.3° \pm 5.1°
2	Kiyono K ¹⁸	1928	46	Japanese	Dry bone-Mechanical	124.6° \pm 3.9°
3	Hoaglund FT ⁷	1980	55 53	England Chinese	Dry bone-Mechanical	136.0° 135°
4	Reikeras O ⁴⁰	1982	96	Norwegian	Dry bone-X- ray	127.7° \pm 7.6°
5	Yoshioka ⁵⁹	1987	32	Canadian	Dry bone-Mechanical	131.0°
6	Noble et al ³¹	1988	200	American	Cadaver-	124.7 \pm 7.4°
8	Macho ²⁴	1991	361	South African	Dry bone-Mechanical	121.9° \pm 4.6°
9	Rubin et al ⁴³	1992	32	French	X- ray	122.9° \pm 7.6°
10	Yamaguchi ⁵⁸	1993	60	Japanese	X- ray	128.4° \pm 0.9°
13	Husmann et al ⁹	1997	310	French	Radiograph	129.2 \pm 7.8°
14	Sugano et al ⁵¹	1998	30 cases	Japanese	Radiograph	126°
15	Maruyama et	2001	200	Japanese	Cadaver	125.0 \pm 4.8°

	al ²⁸					
16	Mahaisavariya et al ²⁵	2001	108	Thai	CT	128.04±6.14 ⁰
17	Da Silva et al ⁴	2003	66 (R-33 L-33)	Brazilian	Dry bone goniometer	Right-122.55± 4.9 left-125.61± 6.6
18	Bulandra AM et al ³	2003	106	Poland	Digital image -FEM- GEO 03 software	140.48±6.95°
19	Khang et al ¹⁶	2003	238	Korean	CT:200 Cadaver: 38	Cadaver: 128.2±5.5 ⁰ CT:125.6±6.0 ⁰
21	Umebese PF et al ⁵⁵	2005	116	Nigerian	X- ray	121.0°±6.0°
22	Toogood PA ⁵³	2008	375	American	Dry bone- Digital Photo	129.2°±6.2°
26	Tuck S.P. et al ⁵⁴	2011	198	UK	X- ray DXA analysis software	129.8 °±3.5°
27	Otsianyi ³³	2011	432	Nairobi	X- ray - goniometer	127.56±3.75 ⁰
29	Gilligan et al ⁶	2013	8271	Global study	Mixed Database	126.4±5.57 ⁰ L-127.02±5.36 ⁰ R-125.71±5.69 ⁰
30	Wright et al ⁵⁷	2014	60 cases	Netherland	CT	124.2±5 ⁰
32	Ming Han et al ²⁹	2015	100pairs (50 male & 50 female)	Chinese	Angulometer	Male: T-132.9±4.11 ⁰ R-131.80±4.36 ⁰ L-134±4.78 ⁰ Female: R-132.1±5.94 ⁰ L-132.8±4.93 ⁰ T-132.4±4.8 ⁰
33	Jiang N et al ¹²	2015	T: 296 M: 239 F:57 L: 145 R: 151	Chinese	Radiograph	T : 133.97±4.28 ⁰ M: 134.02±4.40 ⁰ F: 133.76±3.75 ⁰ L: 134.22±4.22 ⁰ R: 133.73±4.33 ⁰

Table 4: Comparison of NSA with Indian studies (T-Total, M-male, F-female, R-right, L-left)

S. No	Authors	Year	Sample size	Population	Method	NSA
1	Isaac B ⁴³	1997	171	Vellore	Dry bone- mechanical	126.7°
2	Siwach RC ⁴⁹	2003	150	Rohtak	Dry bone- X- ray	123°±4.3°
3	Saikia KC ⁴⁴	2008	92	Guwahati	CT	139.5°±7.5°
4	Deshmukh TR ⁵	2010	77	Vidarbha	X- ray	131.5°
5	Ravichandran D ³⁸	2011	578	Chennai	Dry bone- goniometer	126.55 ⁰ (112to146)
6	Rawal et al ³⁹	2012	98	Indian	CT	124.42±5.49 ⁰
7	Kaur P ¹⁴	2013	R-280 L-280	Ludhiana	Radiograph- PACS system	L-121 ⁰ ±2.44 ⁰ R-121.39 ⁰ ±2.46 ⁰
8	Subhash gujar ⁵⁰	2013	T-250, L- 131 R119	Gujarat	Dry bone- goniometer	T-136.3±6 ⁰ L-136.6±5.45 ⁰ R-136±6.68 ⁰
9	Santanu bhattacharya ⁴⁵	2014	T-50, R- 25 L-25	Kolkata	Radiograph- protractor	R-125.12±2.22 ⁰ L-124.96±1.93 ⁰
10	Shakil M. khan ⁴⁷	2014	T-250, R- 121	Karnataka	Dry bone	T-137.1 ⁰ ,R-137.3 ⁰ L-136.9 ⁰

			L-129			
11	Roy et al ⁴²	2014	204	Eastern Indian	Radiograph	T:130.57±3.0° M:131.0°(N=42)(L:130.9±3.77;R:130.89±3.61) F:130.37°(N=60)(L:130.2±2.56;R:129.93±3.82)

The average FNA in this study is 13.45°. Amongst the western workers Bargar et al¹ (13.8°) and Pick³⁶ (14°) reported similar results. Whereas, Reikera et al⁴⁰ (7°) and Yoshioka et al (8°)⁵⁹ obtained lower values. These lower average values of anteversion can be accounted for by the different techniques employed. They used a transepicondylar axis rather than the retrocondylar axis as the distal axis. The angle showed wide variation in different populations. Difference in methods adopted to measure the angle is one of the reasons for this great disparity between different studies. Our results are comparable with other Indian studies by RC Siwach⁴⁹ (13.7°), A V Maheshwari²⁶ (13°). Saikia KC⁴⁴ (20.4°) reported higher FNA using CT.

Table 5: Comparison of FNA with other foreign studies(T-Total, M-male, F-female, R-right, L-left)

S. No	Author/s	Year	Sample size	Population	Method	FNA
3	Parsons ³⁴	1912	266	British	Dry bone-Mechanical	15.3°
4	Ingalls ¹⁰	1924	100	-	Dry bone-Mechanical	R- 12.6° L- 10.3°
5	Pick et al ³⁶	1941	152	American	Dry bone-Mechanical	14.0°
6	Kingsley et al ¹⁷	1948	630	American	Cadaver	T-8.021(-20to38) M: 7.94 °; F: 8.11° L: 7.47°; R: 8.54°
7	Hoaglund FT ⁷	1980	143	British	Cadaver	M:7° (-2 to 35) F:10° (-2 to 25)
8	Reikeras et al ⁴⁰	1982	96; M: 24 F:24	Norwegian	Cadaver	10.4±6.7° M: 10.2±6.9° F: 10.7±6.5°
9	Yoshioka Y et al ⁵⁹	1987	32	Canadian	Dry bone-Mechanical	M- 7.0° F- 8.0°
10	Braten et al ²	1992	200	Norwegian	Ultrasound	M: 14±7.8° (-2to29) F:18±7.4° (3to33)
11	Schneider B ⁴⁶	1997	98	German	MRI	10.4°±6.3°
12	Husmann et al ⁹	1997	310	French	CT	24.7±8.7° (0.29 to 44.5)
13	Sugano et al ⁵¹	1998	T:30 M:15 F: 15	Japanese	CT	T:19.8±9.3° (3.0 to 50.1) M: 16.9±7.1 F: 22.6±10.6°
14	Maruyama et al ²⁸	2001	200; M:50 F:50	Japanese	Cadaver	Total:9.8±8.5° (-15 to 34) M: 9.8±9.0° (-15 to 30) F: 9.8±8.0 (-12 to 34)
15	Mahaisavariya et al ²⁵	2002	108	Thai	CT	11.37±7.65° (0.13 to 34.92)
16	Kweon DC ²¹	2002	-	Korean	CT	20.1°
17	Kweon DC ²¹	2002	-	Korean	MRI	20.4°
18	Khang et al ¹⁶	2003	238	Korean	CT:200 Cadaver:38	CT:17.9±10.7° Cadaver:17.9±7.4° T: 17.9±10.2° (2to30)
19	Umbese et al ¹¹⁸	2005	116	Nigerian	Radiograph	28±5°
20	Lee et al ²³	2006	24 cases	Korean	CT	18.5±7.2°
21	Toogood et al ⁵³	2008	375	American	Cadaver	9.73° (-14.63 to 35.90)
22	Kulig K ²⁰	2010	28	American	USG	20.7° ±11.0°
23	Kulig K ²⁰	2010	28	American	MRI	19.0° ±11.3°
24	Bargar et al ¹	2010	46 cases	American	CT	13.8±7.9° (-6.1 to 32.7)
25	Botser et al ¹⁰	2012	129	American	CT/MRI	CT: 15.9° (-6 to 38.5)

						MRI: 7° (-19.5 to 36)
26	Koerner et al ¹⁹	2013	328	American	CT	T:8.84±9.66° M: 8.70±9.44° F: 9.51±10.72°
27	Yun et al ⁶⁰	2013	T-112 L-56 R-56	Korean	CT	T: 9.0±8.1° (6.9 to 11.1) L: 9.0±7.4° (7.1 to 10.9) R: 9.0±8.8° (6.7 to 11.3)
28	Wright et al ⁵⁷	2014	60 cases M:30 F:30	Netherlander	CT	12.6±8.2° M: 9.8±7.4° F: 15.5±8.1°
29	Ming Han et al ²⁹	2015	100pairs M:50 F:50	Chinese	Angulometer	Male: T-6.55±9.56° (-12 to 29) R- 6.02±10.85° (-12 to 28) L-7.08±9.30° (-7 to 29) Female: R-10.02±11.69° (-16 to 35) L-6.02±10.85° (-8to 31) T-8.02±11.40° (-16to35)
30	Jiang N et al ¹²	2015	T: 328 M: 269 F:59 L: 164 R: 164	Chinese	CT	T :10.54±9.31° Males: 9.28±8.61° Females: 16.27± 10.26° L: 10.16±9.22° R: 10.92±9.42°

Table 6: Comparison of FNA with other Indian studies. (T-Total, M-male, F-female, R-right, L-left)

S. No	Author/s	Year	Sample size	Population	Method	FNA
1	Kate ¹³	1963	108	-	Dry bone-Mechanical	8.8°
2	Siwach RC ⁴⁹	2003	150	Rohtak	Dry bone-X-ray	13.7°±7.9°
3	Maheshwari AV ²⁶	2004	62 hips	Delhi	Biplane X-ray	11.7°±4.6°
4	Maheshwari AV ²⁶	2004	62 hips	Delhi	Clinical	13.0°±2.7°
5	Jain AK ¹¹	2005	• 72 hips • 138 hips • 138 hips • 300	Delhi	• CT • X-ray • Clinical • Dry bone-Mechanical	• 7.4°±4.6° • 11.5°±5.4° • 13.1°±4.6° • 8.1°±6.6°
6	Nagar M ³⁰	2006	182	Delhi	Dry bone-Mechanical	M-16.3° F-10.9°
7	Saikia KC ⁴⁴	2008	92	Guwahati	CT	20.4°±8.6°
8	Rokade S ⁴¹	2008	69 right 75 left 11-retroverted.	Maharashtra	Dry bone-Mechanical	Total: 8.68°±6.37 R-7.98° L-9.7°
9	Shrikant AR ⁴⁸	2009	288	Pune	Dry bone-Mechanical	8.7°±6.6°
10	A Zalawadia ⁶¹	2010	92	Gujarat	Dry bone-Mechanical	12.4°±18.4°
11	Maheshwari ²⁷	2010	172 hips	Delhi	CT	8.0°±4.7°
12	Shrimathi T ¹⁰⁷	2012	164	Tamil Nadu	Dry bone-Mechanical	9.8°
13	Rawal et al ³⁹	2012	98 M:31; F:29	Indian	CT	10.9±4.22° M: 8.49±4.68° (5.5 to 20.5) F: 12.6±2.92° (6.2 to

In results FNA varied from -6.67° to $+37.41^{\circ}$. According to various workers, it ranges from -25° to 54° . The extreme anteversion may be attributed to persistent version. Postnatal sitting and sleeping postures have been implicated as mechanisms that either cause torsional abnormalities or contribute to persistent femoral anteversion.⁵⁶ The prevalence of retroversion in the present study was 6%. Others reported Kate and Robert (7.7%)¹³, A.K. Jain¹¹ (9.3%) and A.R. Shrikant⁴⁸ (9.4%) and Kingsley¹⁷ (14.8%).

No significant side difference was noted in NSA and FNA. Although Gilligan et al⁶ working on global scale obtained different NSA values between left (127.02°) and right (125.71°). Also Da Silva⁴ reported a significant difference in right (122.5°) and left (125.6°). Some authors noted significant greater FNA on left side^{11,22,27,35,48,49} while others on right side.^{10,12}

Summary and Conclusion

Although various methods exist for anthropometric study of femur bone but here we propose alternative cheap method in comparison to CT and X-ray studies on dry bone. Hence this could be useful to some centers which may not have access to costly machinery. In results mean NSA (124.95°) and FNA (13.45°) were noted. The mean NSA was lower than most of the western studies but it was comparable with most other Indian studies and also Japanese studies. Though the mean FNA was within the range of previous Indian studies but is higher than most other observations. We attribute these numerical differences to different morphometric techniques and measuring points.

References

- Bargar WL, Jamali AA, Nejad AH. Femoral anteversion in THA and its lack of correlation with native acetabular anteversion. *Clin Orthop Relat Res.* 2010;468:527–532.
- Braten Terjesen T, Rossvoll I. Femoral anteversion in normal adults. Ultrasound measurements in 50 men and 50 women. *Acta Orthop Scand.* 1992;63:29–32.
- Bulandra AM, Gielecki JS, Leciejewska I, Karaszewski P, Sieroń D. Digital-image analysis of the femoral shaft/neck angle in human foetuses. *Folia Morphol (Warsz).* 2003 Nov;62(4):415–7.
- Da Silva VJ, Oda JY, Sant'ana DMG. Anatomical aspects of the proximal femur of adults Brazilians. *Int. J. Morphol.*, 21(4):303308, 2003.
- Deshmukh TR, Kuthe AM, Ingole DS, Takre SB. Prediction of femur bone geometry using anthropometric data of Indian population: A numerical approach. *J. Med Sci* 2010;10(1):12–18.
- Gilligan I, Chandraphak S, Mahakkanukrauh P. Femoral neck-shaft angle in humans: variation relating to climate, clothing, lifestyle, sex, age and side. *J Anat.* 2013 Aug;223(2):133–151.
- Hoaglund FT, Low WD. Anatomy of the femoral neck and head, with comparative data from Caucasians and Hong Kong Chinese. *Clin Orthop Relat Res.* 1980 Oct;(152):10–6.
- Ho-Jung Cho, Dai-Soon Kwak, and In-Beom Kim. Morphometric Evaluation of Korean Femurs by Geometric Computation: Comparisons of the Sex and the Population. *BioMed Research International Volume* 2015, Article ID 730538, 9 pages.
- Husmann O, Rubin PJ, Leyvraz PF, et al. Three-dimensional morphology of the proximal femur. *J Arthroplasty.* 1997;12:444–450.
- Ingalls NW. Studies on femur. *Am J Phys Antrop* 1924;7:207–255.
- Jain AK, Maheshwari AV, Singh M.P, Nath S and Bhargav S.K., Femoral neck anteversion: A comprehensive Indian study. *Indian J. Orthop.*2005;39: 137–144.
- Jiang N, Peng L, Al-Qwbani M, Xie GP, Yang QM, Chai Y, Zhang Q, Yu B. Femoral version, neck-shaft angle, and acetabular anteversion in Chinese Han population: a retrospective analysis of 466 healthy adults. *Medicine (Baltimore).* 2015 May;94(21):e891.
- Kate BR and Robert SL. The angle of femoral torsion. *Journal of Anatomical Society of India* 1963;12:8–11.
- Kaur P, Mathew S and George U. A Study Of Neck Shaft Angle In The North-West Indian Population On Radiographs. *International Journal of Basic and Applied Medical Sciences* ISSN: 2277-2103.
- Kay RM, Jaki KA, Skaggs DL. The effect of femoral rotation on the projected femoral neck shaft angle. *J Pediatr Orthop* 2000;20:736–9.
- Khang G, Choi K, Kim C, et al. A study of Korean femoral geometry. *Clin Orthop Relat Res.* 2003;406:116–122.
- Kingsley PC, Olmsted KL. A study to determine the angle of anteversion of the neck of the femur. *J Bone Joint Surg Am.* 1948;30A:745–751.
- Kiyono K and Hirai T Anthropologische Untersuchungen u ber das Skelett der Steinzeit Japaner. IV. Die untere Extremität. *Journal of the Anthropological Society of Nippon Supplement* 1928;43:303–494.
- Koerner JD, Patel NM, Yoon RS, Sirkin MS, Reilly MC, Liporace FA. Femoral version of the general population: does "normal" vary by gender or ethnicity? *J Orthop Trauma.* 2013 Jun;27(6):308–11.
- Kulig K, Hanigan KH, Souza RB and Powers CM. Measurement of Femoral Torsion by Ultrasound and Magnetic Resonance Imaging: Concurrent Validity. *PHYS THER* 2010; 90:1641–8.
- Kweon DC, Yang SH, Park P. Comparative Study in the Femoral Anteversion Measured by CT and MR Imaging as a PACS Image Viewer. *Journal of Korean Society of Medical Informatics* 2002 Dec; 8(04):21–27.
- Le Damany. Les torsions osseuses leur rôle dans la transformation des membres. *Journal of Anatomical Physiology* 1903;39: 246–450.
- Lee YS, Oh SH, Seon JK, et al. 3D femoral neck anteversion measurements based on the posterior femoral plane in ORTHODOC system. *Med Biol Eng Comput.* 2006;44:895–906.
- Macho GA. Anthropological evaluation of left-right differences in the femur of southern African populations. *Anthropologischer Anzeiger* 1991;49:207–16.
- Mahaisavariya B, Sithisieripatip K, Tongdee T, et al. Morphological study of the proximal femur: a new method of geometrical assessment using 3-dimensional reverse engineering. *Med Eng Phys.* 2002;24:617–622.
- Maheshwari AV, Jain AK, Singh MP, Bhargava SK. Estimation of femoral neck anteversion in adults: A

- comparison between preoperative, clinical and X-ray methods. *Indian J Orthop.* 2004;38:151–7.
27. Maheshwari AV, Zlowodzki MP, Siram G, Jain AK. Femoral neck anteversion, acetabular anteversion and combined anteversion in the normal Indian adult population: A computed tomographic study. *Indian J Orthop.* 2010 Jul;44(3):277-82.
 28. Maruyama M, Feinberg JR, Capello WN, et al. The Frank Stinchfield Award: Morphologic features of the acetabulum and femur: anteversion angle and implant positioning. *Clin Orthop Relat Res.* 2001;52–65(393).
 29. Ming Han; Yongkui Zhang & Tao Shan. Femoral Offset and its Relationship to Femoral Neck-shaft Angle and Torsion Angle. *Int. J. Morphol.*,32(4):1194-1198, 2014.
 30. Nagar M, Bhardawaj R, Prakash R. Anteversion in adult Indian femora. *J Anat Soc India* 2000;49:9-12.
 31. Noble PC, Alexander JW, Lindahl LJ, et al. The anatomic basis of femoral component design. *Clin Orthop Relat Res.* 1988:148– 165(235).
 32. Orlin Filipov. Femoral Neck Fractures – Biological Aspects And Risk Factors. *Journal of IMAB - Annual Proceeding (Scientific Papers)* 2014, vol. 20, issue 4.
 33. Otsianyi WK., Naipanoi AP, Koech A. The femoral collodiaphyseal angle amongst selected Kenyan ethnic groups. *J. Morphol. Sci.*, 2011, vol. 28, no. 2, p. 129-131.
 34. Parsons FG. The characteristics of the English thigh-bone. *J Anat Physiol* 1914;48(3):238–267.
 35. Pearson K and Bell J. A Study of the Long Bones of the English Skeleton. London: Cambridge University Press; 1919. Part I. The Femur, Ch. i-v, pp. 23-30. Part I, Section II. The Femur of Man with Special Reference to Other Primate Femora. Ch.vii-x, pp. 239-244.
 36. Pick JW, Stack JK, Anson BJ. Measurements on the human femur. I. Lengths, diameters and angles. *Q Bull Northwest Univ Med Sch.* 1941;15:281–90.
 37. Rasband WS, ImageJ, U.S. National Institutes of Health, Bethesda, Maryland, USA, <http://imagej.nih.gov/ij/>, 1997-2015.
 38. Ravichandran D, Muthukumaravel N, Jaikumar R, Hirak Das, Melani Rajendran. Proximal Femoral Geometry in Indians and its Clinical Applications. *Journal of Anatomical Society of India* Volume 60, Issue 1, June 2011, Pages 6–12.
 39. Rawal B, Ribeiro R, Malhotra R, et al. Anthropometric measurements to design best-fit femoral stem for the Indian population. *Indian J Orthop.* 2012;46:46–53.
 40. Reikeras O, Hoiseth A, Reigstad A, et al. Femoral neck angles: a specimen study with special regard to bilateral differences. *Acta Orthop Scand.* 1982;53:775–779.
 41. Rokade S, A Mane. Femoral Anteversion: Comparison by Two Methods. *The Internet Journal of Biological Anthropology.* 2008 Volume 3 Number 1.
 42. Roy S, Kundu R, Medda S, et al. Evaluation of proximal femoral geometry in plain anterior-posterior radiograph in eastern-Indian population. *J Clin Diagn Res.* 2014;8:C1–C3.
 43. Rubin PJ, Leyvraz PF, Aubaniac JM, et al. The morphology of the proximal femur. A three-dimensional radiographic analysis. *J Bone Joint Surg Br.* 1992;74:28–32.
 44. Saikia KC, Bhuyan S, Rongphar R. Anthropometric study of the hip joint in Northeastern region population with computed topography scan. *Indian J Orthop* 2008;42:260-6.
 45. Santanu Bhattacharya, Pitbaran Chakraborty, Dr. Anindya Mukherjee. Correlation between neck shaft angle of femur with age and anthropometry: A radiographic study *Indian Journal of Basic and Applied Medical Research*; June 2014: Vol.-3, Issue- 3, P. 100-107.
 46. Schneider B, Laubenberger J, Jemlich S, Groene K, Weber HM and Langer M. Measurement of femoral anteversion and tibial torsion by magnetic resonance imaging. *The British Journal of Radiology* 1997;70:575-9.
 47. Shakil Mohamad Khan, Shaik Hussain Saheb. Study on Neck Shaft Angle and Femoral Length of South Indian Femurs. *Int J Anat Res* 2014, Vol 2(4):633-35.
 48. Shrikant AR, Arati KM, Sant SM. The angle of femoral anteversion in Indians. *J. Anat. Soc. India* 2009;58(2):161-65.
 49. Siwach RC, Dahiya S. Anthropometric study of proximal femur geometry and its clinical application. *Indian J Orthop* 2003;37:247-51.
 50. Subhash Moolchand Gujar, Sanjay Vikani, Jigna Parmar, K V Bondre A study of neck shaft angle in the North-west Indian population on radiographs *International Journal of Basic and Applied Medical Sciences* ISSN: 2277-2103 (Online).
 51. Sugano N, Noble PC, Kamalic E. A comparison of alternative methods of measuring femoral anteversion. *J Comput Assist Tomogr.* 1998 Jul-Aug;22(4):610-4.
 52. Tian TP, Chen Y, Leow WK, Hsu W, Howe TS and Png MA. Computing Neck- Shaft Angle of Femur for X-Ray Fracture Detection. *NMRC* 2000.
 53. Toogood PA, Skalak A, Cooperman DR. Proximal femoral anatomy in the normal human population. *Clin Orthop Relat Res.* 2009;467:876–885.
 54. Tuck SP, Rawlings DJ, Scane AC, Pande I, Summers GD, Woolf AD, Francis RM. Femoral neck shaft angle in men with fragility fractures. *J Osteoporos.* 2011;2011:903726.
 55. Umebese PF, Adeyekun A, Moin M. Radiological assessment of femoral neck-shaft and anteversion angles in adult Nigerian HIPS. *Niger Postgrad Med J.* 2005;12:106–109.
 56. Weinstein SL, Buckwaster JA. Turek's orthopaedics in the paediatric foot. 6th edi. Philadelphia: Lippincott Williams and Wilkins;2005.
 57. Wright SJ, Boymans TA, Grimm B, Miles AW, Kessler O. Strong correlation between the morphology of the proximal femur and the geometry of the distal femoral trochlea. *Knee Surg Sports Traumatol Arthrosc.* 2014 Dec;22(12):2900-10.
 58. Yamaguchi O. A radiologic study of the hip joint in cerebral palsy. *Journal of the Japanese Orthopaedic Association* 1993;67:1-11.
 59. Yoshioka Y, Siu D and Cooke TD. The anatomy of functional axis of the femur. *Journal of Bone and Joint Surgery* 1987;69:873-880.
 60. Yun HH, Yoon JR, Yang JH, et al. A validation study for estimation of femoral anteversion using the posterior lesser trochanter line: an analysis of computed tomography measurement. *J Arthroplasty.* 2013;28:1776–1780.
 61. Zalawadia DA, Ruparelia DS, Shah DS, Parekh DD, Patel DS, Rathod SP, Patel DSV. Study of Femoral Neck Anteversion of Adult Dry Femora in Gujarat Region. *NJIRM.* 2010;1(3):7-11.