

## Sexing of hyoid bone based on shapes

Sayeda Sadia Sameera<sup>1</sup>, Syeda Nasreen Fatima<sup>2</sup>, Gulam Mustafa Faisal<sup>3,\*</sup>

<sup>1,2</sup>Tutor, Dept. of Anatomy, <sup>3</sup>Assistant Professor, Dept. of Neurosurgery, Deccan Medical College, Hyderabad, Telangana

**\*Corresponding Author:**

**Gulam Mustafa Faisal**

Assistant Professor, Dept. of Neurosurgery, Deccan Medical College, Hyderabad, Telangana

Email: drgmfaisal@hotmail.com

### Abstract

**Introduction:** The present study is to identify the sex of hyoid bone by studying various shapes of hyoid bone, and weight before and after defatting, were taken.

**Material:** The material used in the present study includes 100 hyoid bones of adult male and female of 15-75 years of age group, procured from the cadavers brought to mortuaries for post mortem to Govt. General Hospitals of Hyderabad, and photographs of dried bone, to compare the shapes.

**Method:** The bone was weighed with the help of chemical balance. The various shapes of the hyoid bone were noted and photographed individually and in groups. The readings were tabulated.

**Result:** It was noticed that all the measurement were greater in males than in females. Males have mostly v shaped hyoid bone and females have mostly u shaped hyoid bone. Our findings co-related well with earlier workers, from diverse population groups.

**Conclusion:** Data acquired by this study will contribute to the knowledge available about anthropometric parameters of South Indian population and may hopefully help in racial and medico-legal applications.

**Keywords:** Hyoid Bone, Greater Cornu, Lesser Cornu, Defatting, Anthropometry

| Access this article online  |   |
|---|---|
| Quick Response Code:  | Website:<br>www.innovativepublication.com |
|  | DOI:<br>10.5958/2394-2126.2016.00081.5    |

### Introduction

Determination of the sex of the skeletal remains of an individual from an examination of a single bone, except the hip bone, is considered to be a most impossible task. On the whole, the bones of a male skeleton are heavier and larger, and markings for the muscular attachments are more pronounced than in the female: this helps in determining the sex and age of the individual from examination of bones procured from the site.

After going through the literature regarding the shapes of human hyoid bone, it is noticed that the work is limited to western population till 1988.

Koebke J and Saturnus K.S.<sup>1</sup> in 1979 studied the shape of hyoid bone in both sexes and classified them into four types

1. Hyperbolic type
2. Parabolic type
3. Horse shoe type
4. Asymmetric type

Lykaki and Papadopoulus<sup>2</sup> studied the shape of hyoid bone in both sexes and classified them into five types

1. U type

2. V type
3. Boat type
4. Horse shoe type
5. Deviated type

Ranjith and Pillai (1988)<sup>3</sup> have worked on sexual dimorphism of hyoid bone in Indians by studying the weight of the hyoid bone in various individuals.

Komenda S and Cerny M<sup>4</sup> studied the hyoid bone taking six parameters for identifying the sex using multivariate discriminant analysis.

Harjeet and Jit I<sup>5</sup> have studied hyoid bone extensively, obtained from fetuses, neonates, children and adults of North West India, regarding its shape, weight and various measurements, and used multivariate discriminant analysis for identifying the sex.

After going through the literature the present author developed an interest in studying the hyoid bone using the shape postulated by Harjeet and Jit I (1996) of hyoid bone in the population of Hyderabad in particular. Hence the present work started with reference to the findings of Harjeet and Jit I (1996), to help in identifying the sex of the deceased individual with the help of hyoid bone obtained.

### Material

The material for the present study was obtained from the cadavers after the autopsy from Osmania General Hospital Hyderabad, during 2011-2012. The specimens were selected out of 500 Medico-legal cases in the age group of 15-75 yrs. Some of the hyoid bones obtained were damaged particularly those of hanging

cases and cases of strangulation, so they were excluded from the present study.

In the same way, some of the hyoid bones which were grossly deformed were included in the present study and classified under deviated type.

Altogether 100 hyoid bones were obtained for the present study of which 66 were from male and 34 from female cadavers.

Measuring Instruments: In the present study a flat glass surface and a good focusing camera is used.

**Methods**

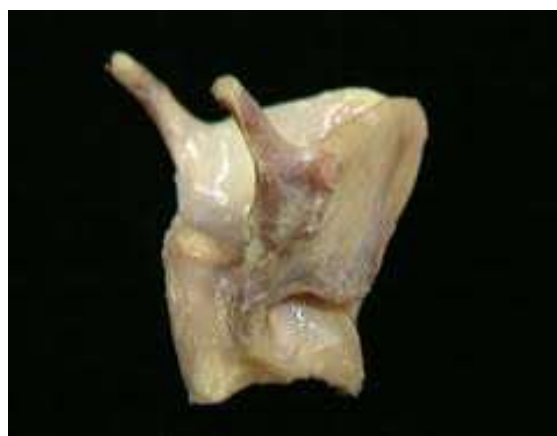The traditional method of giving incision was followed at the autopsy. In the antero-lateral region of the neck the skin along with fascia was reflected and the hyoid bone was located. After cleaning the surrounding structures, hyoid bone was displayed with head in the anatomical position. Hyoid bone lies opposite the upper border of C<sub>4</sub> vertebra, about 1cm below the level of angle of mandible, the tips of the greater cornus may be felt below angle of the mandible close to the anterior border of the sternocleidomastoid muscle, immediately in front of vertebral column. After demarcating the hyoid bone all the supra hyoid and infrahyoid muscles and ligament were cut close to the bone taking necessary precautions to preserve lesser cornu and the hyoid bone was separated from the tongue and larynx.

The hyoid bone thus separated was washed and immediately transferred into a plastic box containing 5% formaldehyde solution in which it was left for 48 to 72 hours. All the specimens preserved in separate plastic boxes were given serial numbers.

In each case before removing the hyoid bone from the cadaver, its age, sex, weight and height in supine position were recorded.

After 72 hours in formalin, the specimen was washed in running water and left outside on glass surface and allowed to dry for about one to two hours. Later all the soft tissues were removed with the help of scalpel and forceps, taking care of lesser cornu.

DE-FATTING STEP- defatting of all hyoid bones was done separately. Individual hyoid bones were kept in acetone for a period of 24 to 72 hours so that no further loss of weight occurs.



**Fig. 1: Defatting of hyoid bone**

**Observations**

The bones were photographed and were classified on the basis of its shape into five types as was done by Harjeet and Jit I (1996).

| U Type   | V Type   | Boat Type  | Horse shoe type   | Deviated type   |
|--|--|--|---|---|
| It is half circle anteriorly and the greater cornua are almost straight. | It is triangular in shape and resembles 'V' the body is bent upon itself with convexity. | It resembles a boat the two greater cornua deviate from each other as if opened out. | It is half circle anteriorly the greater cornua faces each other. | One greater cornua deviates more than the other making the cornua asymmetrical. |

On the basis of above classification in incidence of various shapes of the hyoid bone in adults in present study were given in Table 1A, Table 1B, Table 2.

On applying Chi- square test to the observed values a significant sexual difference was observed in U and V types of bone (p < 0.025, p < 0.005).

In the males V types and in the female's U type hyoid bone were the leading types which covered about 1/3<sup>rd</sup> of the specimens.

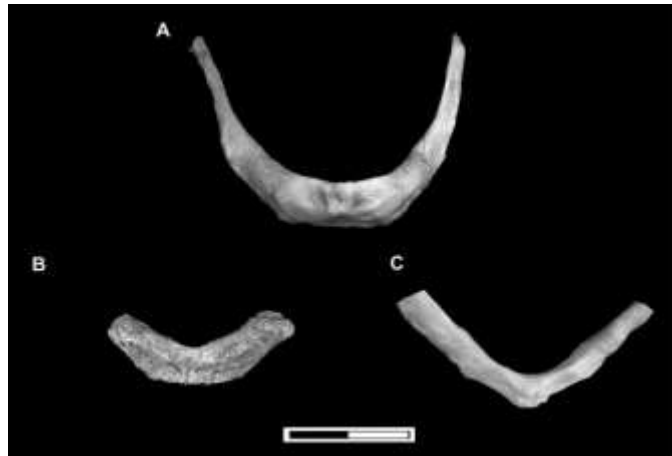Various shapes of hyoid bone in adult males (18 – 75 years) and females (15- 75 yrs) are given in Table 1A and 1B respectively.

Various shapes of hyoid bone in adult male and female with their percentages (15-75 yrs) are given in Table 2.

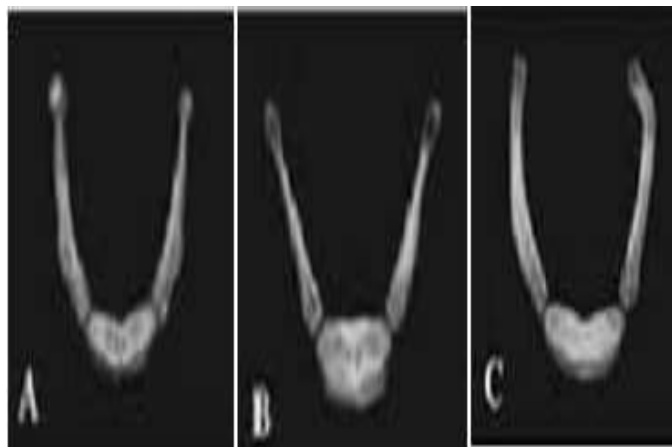
**Table 1A: Various shapes of hyoid bone in adult males (18 – 75 yrs) with their percentage**

| Shape of bone    | No. of bone out of 66 | Percentage |
|------------------|-----------------------|------------|
| U type           | 09                    | 13.6       |
| V type           | 24                    | 36.16      |
| Boat type        | 07                    | 10.6       |
| Horse shape type | 09                    | 13.63      |
| Deviated type    | 17                    | 25.75      |

Photographs of hyoid bone, individual and in group, showing normal shapes and variations were taken (Fig. 2, 3) and it was classified based upon their shapes into five types.



tab 2



**Fig. 3: Shapes of the hyoid bone**

Bar diagram showing the percentage of shapes of hyoid bone in adult males

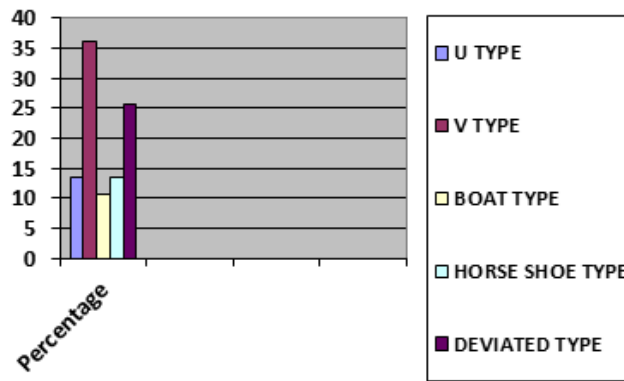


Table 1B: Various shape of hyoid bone in adult females (15 – 75 yrs) with their percentage

| Shape of bone    | No. of bone out of 34 | Percentage |
|------------------|-----------------------|------------|
| U type           | 12                    | 35.29      |
| V type           | 7                     | 20.58      |
| Boat type        | 3                     | 8.8        |
| Horse shape type | 5                     | 14.70      |
| Deviated type    | 7                     | 20.58      |

Bar diagram showing the percentage of shapes of hyoid bone in adult females

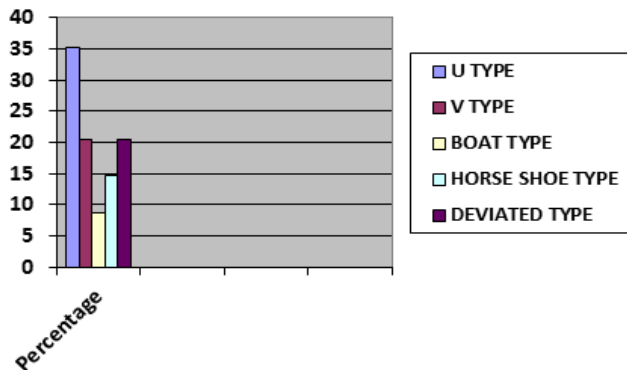


Table 2: Various shape of (100) hyoid bone in adult males and females (15 – 75 yrs)

| Shape            | Adults     |            |       |
|------------------|------------|------------|-------|
|                  | Males      | Females    | Total |
| U type           | 9(13.6%)   | 12(35.29%) | 21%   |
| V type           | 24(36.36%) | 7(20.58%)  | 31%   |
| Boat type        | 7(10.6%)   | 3(8.8%)    | 10%   |
| Horse shape type | 9(13.63%)  | 5(14.70%)  | 14%   |
| Deviated type    | 17(25.75%) | 7(20.58%)  | 24%   |
| Total            | 66         | 34         | 100   |

Table 3

| Specimen No. | Age | Sex    | Height | Shape of hyoid bone | Special features   |
|--------------|-----|--------|--------|---------------------|--|
| 1            | 45  | Female | 150 cm | Deviated type       | Right greater coruna in shaped, compressed superior – inferiorly and pushed anteriorly with the left greater coruna – normal.  |
| 4            | 35  | Male   | 150 cm | -do-                | Rt. Greater cornua short and deviated to right side, lesser cornua – absent on both sides.   |
| 5            | 30  | Male   | 155 cm | -do-                | ‘L’ shaped right greater cornua, left greater cornua normal fused with lesser cornua.  |
| 6            | 60  | Male   | 155 cm | -do-                | Right greater cornua is normal – left is displaced anteriorly.   |
| 8            | 50  | Female | 150 cm | -do-                | Dorsal half of right greater cornua – deviated medially. Left greater cornua normal.   |
| 10           | 60  | Female | 160 cm | -do-                | Two tubercles resembling lesser cornua present on the anterior surface of the body situated above and below the transverse ridge – lesser cornua absent on both sides.       |
| 85           | 35  | Male   | 168 cm | ‘U’ shaped          | Lesser cornua absent on both sides. A small tubercle resembling lesser cornua – present in the mid line along the superior border.   |
| 89           | 45  | Female | 150 cm | Horse shaped        | Left lesser cornua – absent, a tubercle like structure present in the middle on the anterior surface of the body close to the superior border. Right lesser cornua – normal. |

## Discussion

Modern text books of Anatomy do not provide adequate information about the various measurements of hyoid bone, which are important in identifying the sex of the hyoid.

Measurement of the bones obtained for male and female are drawn in the same diagram, so that number of cases belonging to one sex, falling within the range of other sex can be easily noticed.

This method was also used successfully by Jit and Sing (1966)<sup>6</sup> and Jit et al (1980) and Harjeet and Jit (1966). According to Harjeet and Jit I (1996) they could identify 36% males and 33% females hyoid bones of their series.

The present study on the shape of hyoid bone was compared with the observation of Koebke and Saturnus (1979), Papadopoulos et al (1989) and Harjeet and Jit I (1996).

It is observed in the present study that incidence of V-type of hyoid bone is higher when compared with Harjeet and Jit I (1996). On the other hand, the incidence of Boat shaped hyoid bone is lower than recorded by Papadopoulos et al<sup>7</sup> (1989) and Harjeet and Jit I (1996).

The incidence of Horse shoe hyoid bone is lower when compared with the readings given by Papadopoulos et al (1989), but higher than the readings of Harjeet and Jit I (1996), and is similar to that of Koebke and Saturnus (1979). The incidence of “U” type (Hyperbolic), was lower than shown by Koebke and Saturnus (1979), but higher than incidence given by Papadopoulos et al (1989) & Harjeet and Jit I (1996).

It is observed that when Chi-square test was applied to the present observations, a significant sexual difference was observed in U and V types of bones ( $P < 0.005$ ,  $P < 0.005$ ).

In the males V-type and in females U-type of hyoid bone were the leading types, which cover about half of the specimens. This increase incidence of V-shaped bones seems to be related to a decrease in the superior thyroid angle, which occurs with increasing age (Harjeet and Jit I (1996)) regarding the other shapes it is not possible to identify any specific factor which could have influenced their formation.

Both U and V types of bones could be found in any sex and this was matching with earlier reports<sup>[12,14]</sup>. The shape and size of the hyoid bone varies with the sex and hence they could be regarded as sex indicators<sup>[8-12]</sup>.

Females showed higher incidence of fracture compared to the male victims<sup>[13,15]</sup>. Miller et al<sup>[12]</sup> found that the hyoid bones of females had relatively long thin distal segments. Strength of the hyoid bone is less in females<sup>[16]</sup>. The present study found females to have higher incidence of thin greater horns compared to males and it is matching with earlier reports.

### Conclusion

Data acquired by this study will contribute to the knowledge available about anthropometric parameters of South Indian population and may hopefully help in racial and medico-legal applications.

### Bibliography

1. Koebke J, Saternus KS. Zur Morphologie des adulten menschlichen Zungenbeins, *Zeitschrift für Medizin*, 1979;84:7–18.
2. Lykaki G, Papadopoulos N. The ossified hyoid apparatus, morphology, interpretation, clinical and functional significance. *Anatomischer Anzeiger*, 1988;166:187–193.
3. Komenda S, Cerny M. Sex determination from hyoid bone by means of discriminant analysis, *Acta Universitatis Palackianae, olomucensis Facultatis Medicae*, 1990;125:37–51.
4. Rangith C, Pillai S. A Post mortem study of one hundred hyoid bone using weight as parameter. *Journal of Indian Academy of forensic medicine*, 1988;10:31–33.
5. Harjeet and Jit I. Dimensions in thyroid cartilage in neonates, children and adults in northwest, Indian subjects. *Journal of Anatomical Society of India*. 1992; Vol. 45(1):4–22.
6. Harjeet, Jit I. Shape, size and sexual dimorphism of hyoid bone in North West Indians. *Journal of Anatomical Society of India*, 1996;33:77–84.
7. Papadopoulos et al. The shape and size of the human hyoid bone and a proposal for an alternative classification. *Journal of Anatomy*, 1989;166:249–260.
8. Leksan I, Marcikić M, Nikolić V, Radić R, Selthofer R. Morphological classification and sexual dimorphism of hyoid bone: new approach. *Coll Antropol*. 2005 Jun;29(1):237–42.
9. Mukhopadhyay PP. Morphometric features and sexual dimorphism of adult hyoid bone: A population specific study with forensic implications. *J Forensic Leg Med*. 2010;17:321–4.
10. Kim DI, Lee UY, Park DK, Kim YS, Han KH, Kim KH, Han SH. Morphometrics of the hyoid bone for human sex determination from digital photographs. *J Forensic Sci*. 2006;51(5):979–84.
11. Shimzu Y, Kanetaka H, Kim YH, Okayama K, Kano M. Age related morphological changes in human hyoid bone. *Cells Tissues Organs* 2005;180(3):185–92.
12. Miller KWP, Walker PL, O' Halloran RL. "Age and Sex related variation in hyoid bone morphology". *Journal of Forensic Sciences* 1998;43(6):1138–1143.
13. Feigin G. Frequency of neck organ fractures in hanging. *Am J Forensic Med Pathology*. 1999;20(2):128–30.
14. Nikolic S, Micic J, Atanasijevic T, Djokic V, Djonic D. Analysis of Neck Injuries in Hanging. *Am J Forensic Med Pathol*. 2003;24(2):179–82.
15. Paparo GP, Siegel H. Neck markings and fractures in suicidal hangings. *Forensic Sci Int*. 1984;24(1):27–35.
16. Leksan I, Nikoli V, Radi R, Ela TM, Dumen B, Popovi B, et al. Biomechanical and Forensic Characteristics of Hyoid Bone. *Journal of Biomechanics*. 2008;41(S1):s384.