

Analysis of the Morphological Variations between Musculocutaneous Nerve and Median Nerve -A cadaveric study

Neeraj T. Master^{1,*}, Deepa S. Gupta²

¹Resident & Tutor, ²Professor & Head, Dept. of Anatomy, SMIMER, Surat

***Corresponding Author:**

Neeraj T. Master

Resident & Tutor, Dept. of Anatomy, SMIMER, Surat

Email: dr.neerajmaster@yahoo.com

Abstract

Background: Musculocutaneous nerve, a branch from the lateral cord of brachial plexus supply the muscles of the front of the arm. Musculocutaneous nerve has frequent variations in arm.

Aim: To analyze the morphological variations between musculocutaneous nerve and median nerve in the arm.

Materials and Method: 56 upper limbs belonging to 28 embalmed cadavers (M: F: 20:8) donated over last 3 years in the Anatomy Department, SMIMER Medical Collage, Surat were utilised for this study. The dissections of the upper limbs were performed as per Cunningham's manual. The variations and/ communications between musculocutaneous nerve and median nerve if any were identified and documented.

Results: Variations were encountered in 12 (21.43%) out of 56 upper limbs of the present study. In 6 upper limbs below the coracobrachialis, musculocutaneous nerve and median nerve showed communicating rami. In 1 upper limb musculocutaneous nerve was giving larger communication to median nerve as third root. In 2 upper limbs medial cord formed the median nerve and fibres from musculocutaneous nerve join the median nerve as lateral root below coracobrachialis. In 1 upper limb musculocutaneous nerve completely fused with median nerve after supplying coracobrachialis. In 2 upper limbs musculocutaneous nerve was absent and median nerves was supplying the flexor muscles of the arm and were associated with the 3rd head of biceps brachii muscle.

Conclusion: The data obtained from the study were in the mid-range of previous studies. Awareness regarding such variations as well as communications is important for surgeons, orthopaedics and anaesthetist that are treating the lesions of shoulder and arm region.

Keywords: Musculocutaneous Nerve, Median Nerve, Communication Branch (Ramus), Coracobrachialis Muscle.

Access this article online	
Quick Response Code:	Website: www.innovativepublication.com
	DOI: 10.5958/2394-2126.2016.00074.8

Introduction

Musculocutaneous nerve (MCN) is one of the terminal branches derived from the lateral cord (C5, C6, C7) of brachial plexus and supplies the muscles of anterior compartment of arm. It supplies the shoulder joint, passes through coracobrachialis and lies between biceps brachii and brachialis muscles and then continues as lateral cutaneous nerve of forearm. It supplies coracobrachialis, biceps brachii and brachialis muscles.

The Musculocutaneous nerve has frequent variations. It may run behind Coracobrachialis (CBM) or adhere for some distance to the Median nerve (MN). Some fibres of the Median nerve (MN) may run in the Musculocutaneous nerve, leaving it to join their proper trunk and less frequently the reverse occurs.¹

The presences of such morphological variations and communicating branch (CB) between Musculocutaneous nerve and Median nerve have been reported by various authors with the incidence of 1.4-33.3%.^{2,3,4,5}

Awareness of such variations is important for surgeons and anesthetist who are dealing with the lesions of upper limb and shoulder region.

So, the aim of this work was:

1. To analyze the morphological variations between Musculocutaneous nerve and Median nerve in the arm with respect to their branching patterns, communications and distribution.
2. To compare the data obtained with that with the previous studies.

Materials and Methods

56 upper limbs belonging to 28 embalmed cadavers (M: F: 20:8) donated over last three years in the Anatomy Department, Surat Municipal Institute of Medical Education And Research (SMIMER), Gujarat, India, were utilised for this study. These upper limbs were properly labeled for numbers, right or left sides and male or female sex (e.g.7MR = seven number, male body & right limb).

Dissection of the all upper limbs were done as per dissection guidelines given by Cunningham's manual of Practical Anatomy to expose the musculocutaneous and median nerves in its whole course in arm⁶. The morphological variations between musculocutaneous nerve and median nerve were noted. Communicating rami if found, were identified and documented by photographs.

Results

Out of the 56 upper limbs dissected, different types of communications as well as variations in formation, course and branching patterns between Musculocutaneous nerve and Median nerve were observed in 12(21.43%) limbs.

1. In 6 upper limbs (4ML, 7MR, 10ML, 10MR, 19FL, 22FR) (10.7%) communication rami were present below the coracobrachialis muscle between the musculocutaneous nerve and the median nerve. (Fig. 1). Musculocutaneous nerve was supplying the all the flexors of the arm and continue as lateral cutaneous nerve of forearm.

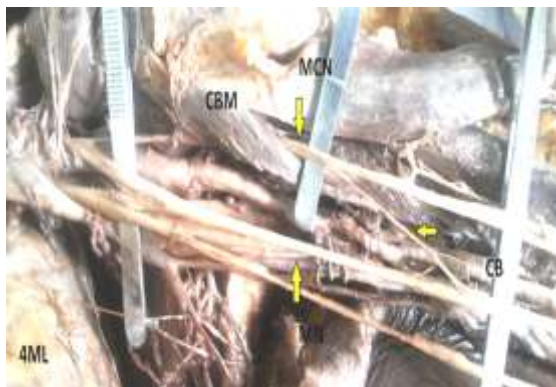

Fig. 1: (4ML) Shows communicating branch(CB) between musculocutaneous nerve(MCN) and median nerve below coracobrachialis muscle(CBM)

2. In 1 upper limb (28FL) (1.78%) musculocutaneous nerve was not piercing the coracobrachialis muscle and was giving larger communication ramus to Median nerve as third root at the level of coracobrachialis. Musculocutaneous nerve was supplying all the arm flexor muscles.(Fig. 2)



Fig. 2: (28FL) Shows communicating branch as third root of median nerve between median nerve (MN) and musculocutaneous nerve (MCN). Later does not pierce coracobrachialis muscle (CBM)

3. In 2 upper limbs (11ML, 15MR) (3.57%) medial cord continue as the median nerve and later the fibres from the musculocutaneous nerve joined the median nerve as lateral root below the coracobrachialis muscle. (Fig. 3) Rest of the course was normal.

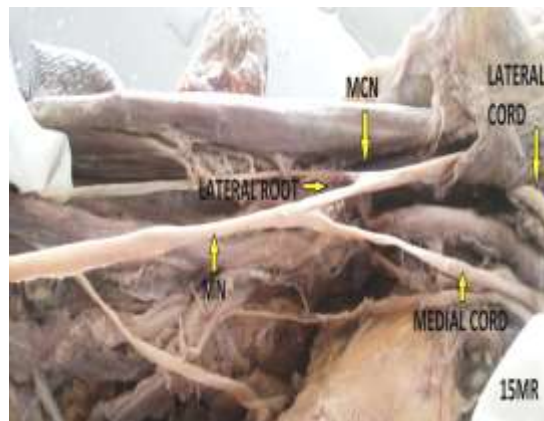

Fig. 3: (15MR) Shows median nerve (MN) as a medial cord and later joined by fibres of lateral cord from musculocutaneous nerve(MCN)

4. In 1 upper limb (28FR) (1.78%) musculocutaneous nerve completely fused with Median nerve after supplying coracobrachialis. (Fig. 4) Later, it arise as a common branch from median nerve, supply the biceps brachii and brachialis and then continue as lateral cutaneous nerve of forearm.

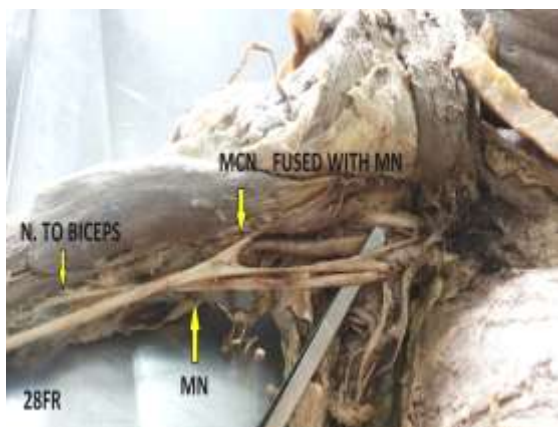


Fig. 4: (28FR) Shows fusion of musculocutaneous nerve (MCN) after supplying coracobrachialis muscle (CBM) and arise as common branch from median nerve to supply the biceps and brachialis

- In 2 upper limbs (16MR, 22FL) (3.57%) musculocutaneous nerve was absent and median nerves was giving separate branches to supply the flexor muscles of the arm and lateral cutaneous nerve of forearm. However, coracobrachialis was supplied by direct branch from lateral cord. Median nerve was having extra root of origin from lateral cord. Both of them were associated with the extra head of Biceps brachii muscle from the lower humerus. (Fig. 5)

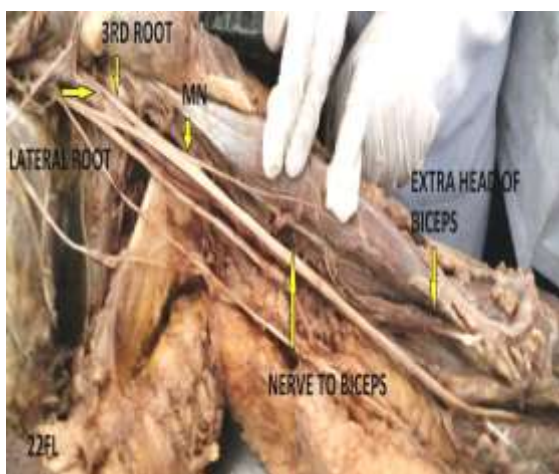


Fig. 5: (22FL) Shows absent musculocutaneous nerve (MCN) and all flexors of arm supplied by branches from median nerve(MN) having three roots of origin. Extra head of biceps brachii is seen

- In remaining 44 upper limbs (78.57%) no variations or communications were seen and were having normal courses.

The variations were bilateral in two cadavers (No. 10 & 28).

Discussion

The presence of morphological variations and communicating branches (CB) between Musculocutaneous nerve and Median nerve have been reported by various authors with the incidence of 1.4-33.3% in different studies. Our results were in the midrange of the previous studies. (Table 1)

Various types of classifications have been described for the communications between the musculocutaneous nerve and the median nerve by Le Minor¹¹, Venieratos and Anagnostopoulou³ and Choi et al⁴.

According to Le Minor classification¹¹ variations have been classified into five types.

- In type I, there is no communication between the median nerve and the musculocutaneous nerve.
- In type II, the fibres of the lateral root of the median nerve pass through the musculocutaneous nerve and join the median nerve in the middle of the arm,
- In type III, the lateral root fibres of the median nerve pass along the musculocutaneous nerve and after some distance, leave it to form the lateral root of the median nerve.
- In type IV, the musculocutaneous nerve fibres join the lateral root of the median nerve and after some distance the musculocutaneous nerve arises from the median nerve.
- In type V, the musculocutaneous nerve is absent and the entire fibres of the musculocutaneous nerve pass through the lateral root and fibres to the muscles supplied by the musculocutaneous nerve branch out directly from the median nerve.

Morphological variations found in our study were tabulated as per Le Minor classification in Table 2 and compared with the results of other authors.

Morphological variations between musculocutaneous nerve and median nerve in our study were seen in 12 (21.4%) upper limbs (Table 2) and were unilateral in 8 cases and bilateral in 2 cases. Out of these, 7 cases were of Le Minor type II, 2 cases were of type III, 1 case of type IV and 2 cases of type V. Most common variations (12.5%) in our study were communicating branch in middle third of arm between musculocutaneous nerve and median nerve below coracobrachialis muscle i.e. Le Minor type II. However it was type IV (12%) in study done by Savant et al. Budhiraja et al⁸ had reported splitting of median nerve in arm into musculocutaneous nerve and median nerve proper in 6 cases and absence of musculocutaneous nerve in 13 cases, which were similar to type IV and type V of Le Minor classification respectively.

Venieratos et al³ classified the communications into three types in relation to coracobrachialis muscle. In type I, communication was proximal to the entrance of musculocutaneous nerve into coracobrachialis, in type II, distal to the muscle and in type III, neither

nerve nor its branch pierce the muscle. In present study, 9 cases were of type II, 2 were of type III and 1 case was of type I.

Choi et al⁴ had also classified the variations. According to which, Pattern I- fusion of both nerves, pattern 2- present of one supplementary branch between two nerves and pattern 3- two branches between the both nerves. Pattern 2 was further divided into 2a and 2b base on single root connection or two root connections. In 2 cases of our study fusion of both the nerves were seen. Single communication was seen in most of the cases of our study.

Further, in limb 28FL (Fig. 2) of our study, communication was at the level of coracobrachialis giving the trifurcate appearance and was not piercing the coracobrachialis muscle (included in type II). Similarly, in limb 28FR (Fig. 4) (included in type IV) musculocutaneous nerve was completely fused with median nerve after supplying the coracobrachialis and then again separate as common branch from median nerve and was supplying the arm muscles. Such varied patterns were not described in Le Minor's classification. Because of such variability in communicating patterns, Kaur and Singla¹⁰ had suggested the modification in the le minor classification.

Kaur and Singla¹⁰ had proposed the newer classification with few modifications in the original Le Minor classification. In which, type II had been further grouped in to Group A (where communicating ramus from musculocutaneous nerve giving trifurcate appearance of lateral cord into a musculocutaneous nerve and two lateral roots), Group B (communicating ramus leaves musculocutaneous nerve before it pierces coracobrachialis) and Group C (The communicating ramus leaves musculocutaneous nerve after it has pierced coracobrachialis.). In type IV, Group A- Musculocutaneous nerve arises from median nerve proximal to muscular branches for flexors of arm which are thus supplied by musculocutaneous nerve. Group B- Musculocutaneous nerve arises from median nerve after

the former had supplied muscles of forearm. In type V, Group A- Musculocutaneous nerve is altogether absent with all its fibres passing through lateral root of median nerve. All branches of musculocutaneous nerve come from median nerve. Group B- Musculocutaneous nerve supplies coracobrachialis and then completely fuses with median nerve. Rest of its branches come from median nerve and Group C- Musculocutaneous nerve supplies all flexors of arm and then fuses with median nerve. The lateral cutaneous nerve of forearm comes from median nerve. They had added Type VI- The communicating ramus arises in lower one-third of arm after musculocutaneous nerve has supplied all flexors of arm. It was further grouped in to A and B in relation to pronator teres muscle pierced by communicating branch.

So, according to Kaur and Singla classification, in present study, out of 7 type II cases, 6 limbs were type II group C and 1 limb was of type II group A. Out of 2 type V cases, 1 limb was of type V group A and 1 limb was of type V group B and 1 limb (28FR) was of type IV group A which had mixed pattern of type V group B also.

Musculocutaneous nerve may not pierce the coracobrachialis muscle as was seen in case 28FL (Fig. 2) of our study. Median nerve may have more than two roots of origin, as was seen in limb 28FL and 22FL (Fig. 5) of our study giving the trifurcate appearance. The extra root can be from lateral cord, musculocutaneous nerve or even from medial cord.¹²

Absent musculocutaneous nerve has been reported by various authors in different studies with varied incidence rate ranging from 3.33% to 11.2%. (Table 3) In our study we found two (3.57%) such cases (16 MR, 22FL) and both were showing 3rd head of origin of biceps brachii from the lower humerus (Fig. 5). Absent of musculocutaneous nerve and its association with extra head of origin of biceps brachii from lower humerus was unique in our study. Only few such incidences are reported in literature.^{13,14}

Table 1: Incidence of communication between musculocutaneous nerve and median nerve in different studies

No.	Author	Year	Incidence (%)
1	Watanabe et al ²	1985	1.4
2	Kosugi, Mortia and Yamashita ⁷	1986	21.8
3	Venieratos and Anagnostopoulou ³	1998	13.9
4	Rao and Chaudhary ⁵	2000	33.3
5	Choi et al ⁴	2002	26.4
6	Budhiraja et al ⁸	2011	20.7
7	Sawant et al ⁹	2012	30
8	Kaur et al ¹⁰	2013	11.7
9	Present study (Master et al)	2015	21.43

Table 2: Comparison of results of present study with other authors as per Le Minor classification

	Authors	Type I	Type II	Type III	Type IV	Type V	Total incidence of variations	Total limbs examined
1	Present study	44	7	2	1	2	12	56
2	Savant et al ⁹	70	4	6	12	8	30	100
3	Kaur et al ¹⁰	53	4	-	-	2	7*	60

*1 case was not fitting in any type of le minor classification (type VI of Kaur and Singla¹⁰ classification).

Table 3: Incidence of absent musculocutaneous nerve(MCN) in different studies

No.	Authors	Total No. of limbs	Incidence of MCN and MN communications	Absent MCN cases	Percentage of absent MCN (%)	Accessory head of biceps brachii cases
1	Rao and Chaudhary ⁵	24	8	2	8.33	-
2	Savant et al ⁹	100	30	8	8	-
3	Budhiraja et al ⁸	116	24	13	11.2	-
4	Kaur et al ¹⁰	60	7	2	3.33	-
5	Present study	56	12	2	3.57	2

Ontogeny

Willium Larsen (1997)¹⁵ had said that peripheral nerve axons are guided to their target organ by apical growth cone which by the means of filopodia senses the molecular marker and designate the correct rout-called path-finding. Various tropical substances are involved in this to choose the right path in a coordinated site specific manner.

The variations in nerve patterns seen in our study may be the result of, (i) altered signalling between the mesenchymal cells and the neuronal growth cones¹⁶ or (ii) due to circulatory factors at the time of fusion of brachial plexus cords⁷ or (iii) there can be failure of differentiation leading to aberrant course of fibres¹⁷ or (iv) can also be due to lack of coordination between muscle growth and innervations as axons travel to local mesenchyme.¹⁸

Phylogeny

Chauhan and Roy¹⁹ said that these communications are the results of developmental anomaly and are phylogenic remnants.

In lower vertebrates only median nerve is seen and musculocutaneous nerve is absent.²⁰ Similar was the situation in both limbs of cadaver no. 16MR and 22FL of our study, which thus represents these vertebrates. Similarly in dogs, musculocutaneous nerve sends communicating branch to median nerve which shows the primitive nerve supply²⁰. Such variations were seen in most of the limbs of present study.

Conclusion

The data obtained from the present study were in the mid-range of previous studies. Median nerve may have branches in arm and supply the arm muscles. Such morphological variations should be considered with due importance and not just consider as mere exception as it has clinical importance while treating trauma cases or

performing release operations for nerve compression in the upper limb.

Awareness regarding such type of variations as well as communications is important for surgeons, orthopedics and anesthetics who are involved in the management of upper limb peripheral nerve lesions especially in shoulder, axilla and arm region.

References

1. Susan Standring. Gray's anatomy. In: Neil RB, Jeremiah CH, Patricia C, David J, Alan RC, Vishy M, Michael AG, Richard LMN, Caroline BW, The anatomical basis of clinical practice. 40th Ed., Churchill Livingstone Elsevier, 2008,828-829.
2. M Watanabe, M., Takatsuji, K., Sakamoto, N., Morit, Y., Ito, H. Two cases of fusion of the musculocutaneous and median nerves. Kalbo gaki Zasshi, 1985, vol. 60,1-7.
3. Venieratos, D., Anagnostopoulou, S. Classification of communications between the musculocutaneous and median nerves. Clinical Anatomy, 1998, vol. 11,327-331.
4. Choi, D., Rodriguez-Niedenfuhr, M., Vazquez, T., Parkin, I., Sanudo, JR. Patterns of connections between the musculocutaneous and median nerves in the axilla and arm. Clinical Anatomy, 2002, vol. 15, n. 1,11-17.
5. Prasada Rao PV, Chaudhary SC. Communication of the musculocutaneous nerve with the median nerve. East Afr Med J 2000;77(9):498-503.
6. Romanes GJ. The pectoral region & axilla, front of the arm, Vol. 1. 15th edition, The English Language Book Society and Oxford University Press: Edinburgh, London 1990, p.28-34, 67.
7. Kosugi, K. Mortia, T., Yamashita, H. Branching pattern of the musculocutaneous nerve. Cases possessing normal biceps brachii. Jikeikai Medical Journal, 1986, vol. 33,63-71.
8. Virendra Budhiraja et al Concurrent variations of median and musculocutaneous nerves and their clinical correlation– a cadaveric study ,Italian Journal of Anatomy and Embryology IJAE , 2011,Vol. 116, n. 2:67-72.
9. Sawant S P, Morphological Study of Connection between the Median and the Musculocutaneous Nerves. Anatomica Karnataka, 2013,Vol-7, (1), Page 72-80.

10. Kaur Neelamjeet and Singla, Different Types Of Communications Between Musculocutaneous Nerve And Median Nerve -A Cadaveric Study In North Indian Population, CIBTech Journal of Surgery ISSN: 2319-3875 2013 Vol. 2 (1) January-April, pp.21-28.
11. Le Minor JM (1990) A rare variation of the median and musculocutaneous nerves in man. Arch Anat Histol Embryol, vol.73:33-42.
12. Vaishali Paranjape et al, Variant Median and Absent Musculocutaneous Nerve, J Life Sci, 2012,4(2):141-144.
13. Arora L, Dhingra R, Absence of musculocutaneous nerve and accessory head of biceps brachii: a case report. Indian J Plast Surg, 2005,38:144-146.
14. Renata P, et al, Absence of the musculocutaneous nerve associated with a supernumerary head of biceps brachii: a case report, Surg Radiol Anat, DOI 10.1007/s00276-010-0771-9 © Springer-Verlag 2011.
15. Larsen William J, Human Embryology, 2nd Edition. New York, Edinburgh: Churchill Livingstone, chapter 5, development of peripheral nervous system, 1997,109-110.
16. Sannes HD, Reh TA, Harris WA. Axon growth and guidance. In: Development of Nervous System. Academic Press: New York 2000:p.189-97.
17. Iwata H. Studies on the development of the brachial plexus in Japanese embryo. Rep Dept Anat Mie Prefect Univ Sch Med 1960;13:129-144.
18. Chiarapattanakom P, Leechavengvongs S, Witoonchart K, Uerpaiojkit C, Thuvasethakul P. Anatomy and internal topography of the musculocutaneous nerve: the nerves to the biceps and brachialis muscle. J Hand Surg Am 1998;23(2):250-5.
19. Chauhan R, Roy TS. Communication between the median and musculocutaneous nerve: a case report. J Anat Soc India 2002;51(1):72-5.
20. Septimus Sisson, The anatomy of the domestic animals, Nervous system of dog, 2nd Edition, W.B. Saunders Company, Philadelphia & London, 1930,853.