

Sub lingual thyroid - a case report

Nasreen Fatima Syeda^{1,*}, Sadia Sameera Syeda²

^{1,2}Tutor, Dept. of Anatomy, Deccan College of Medical Sciences, Hyderabad

***Corresponding Author:**

Nasreen Fatima Syeda

Tutor, Dept. of Anatomy, Deccan College of Medical Sciences, Hyderabad

Email: nasreenanatomy@gmail.com

Abstract

Introduction: A sub lingual thyroid anterior to the hyoid bone which is the only thyroid tissue present in the body is a rare entity. It was found due to failure of descent of the thyroid gland to its normal position

Methods: 13 yr. old female presented with symptoms of severe sinusitis. CT scan was used to perform this study.

Result: A Sublingual thyroid gland present in front of the hyoid bone is observed and there was complete absence of thyroid gland at normal position.

Discussion: Incidence of lingual thyroid gland is reported as 1:100,000. It is manifested more in females. 1:7 Ectopic thyroid tissue can occur anywhere from foramen caecum to its normal position i.e.; in front & sides of trachea at the level of 5th, 6th, 7th cervical & 1st thoracic vertebrae in the human body. 70% of patients with lingual thyroid are associated with hypothyroidism and 10% suffer from cretinism.

Conclusion: A sublingual thyroid due to failure of descent of the thyroid gland with congenital hypothyroidism. No known pathogenesis is present in this case. Thorough examination with follow up is important. A thyroid profile, hemogram, an x-ray of the neck & thyroid scan has to be done regularly with interval of at least once in 6 months. Unless there is need for emergency surgery, it should not be performed. Patient should be treated symptomatically. There should be hormonal assay done for every child born and treated as early as possible to avoid the consequences. Starting of treatment in patients with congenital problems of hormones can help the patient to lead a normal life.

Keywords: Lingual thyroid gland; Foramen caecum; Ectopic; Hypothyroidism; Cretinism.

| Access this article online | |
|-------------------------------------------------------------------------------------|-------------------------------------------|
| Quick Response Code: | Website: www.innovativepublication.com |
|  | DOI: 10.5958/2394-2126.2016.00080.3 |

Introduction

A sub lingual thyroid anterior to hyoid bone which is the only thyroid tissue present in the body is a rare entity. The Thyroid gland is the first endocrine to develop and it starts functioning at end of third month of intrauterine life. It develops from ultimobranchial body formed by the fusion of 4th and 5th pharyngeal pouches. The para follicular cells present in the gland develops from neural crest cells migrating to ultimobranchial body present at the floor of developing tongue. It then migrates from the floor of the tongue to the normal position that is in front of 5th -7th cervical vertebra. An ectopic gland was found due to failure of descent of the thyroid gland to its normal position. Ectopic thyroid tissue can occur anywhere from foramen caecum to diaphragm. Incomplete descent of thyroid gland will lead to abnormal positioning of the gland such as at foramen caecum, just below the tongue, at the level of hyoid bone or it can be below the hyoid bone etc.

The presence of thyroglossal cyst can also have a normal functioning thyroid gland along its tract or the thyroid secretion usually will be insufficient for the requirement of the individual. The accessory normally functioning thyroid gland if removed completely without any serious cause will lead to insufficiency of the required hormone.

Imaging techniques can help in establishing the diagnosis of sublingual thyroid. The treatment of choice depends on the clinical presentation & findings of the imaging techniques used. Surgery if needed can be done, but conservative treatment is more useful in most of the cases where surgery is not the ultimate one.

We present a case report of ectopic thyroid with coexistence of hypothyroidism which is a rare entity.

Materials & Methods

A 14 yr. old female with incident finding on CT scan done for PNS presented with sublingual thyroid gland with congenital hypothyroidism on Eltroxin 100microgram since the age of 18 months. CT scan revealed this to be the only functioning thyroid gland present and absence of thyroid gland at its normal position. A thyroid profile showed a decreased levels of thyroxine levels in the blood with associated increase in the TSH levels.

Result

A Sublingual thyroid gland present in front of the hyoid bone is observed and that there was complete absence of thyroid gland at the normal position. On clinical examination of the patient a mass was observed just below the tongue, which was not producing any obstructive symptoms. Neck examination showed no palpable mass indicating absence of thyroid in its normal position. There was no signs of cretinism or any other associated symptoms of hypothyroidism.

Our CT findings are:

A hypodense softtissue mass is observed in front of hyoid bone.

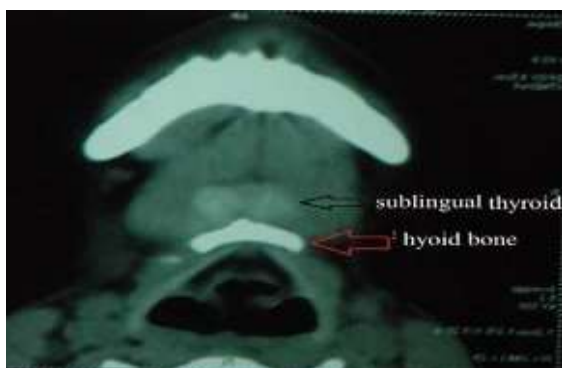


Fig. 1: Showing thyroid gland in front of the hyoid bone

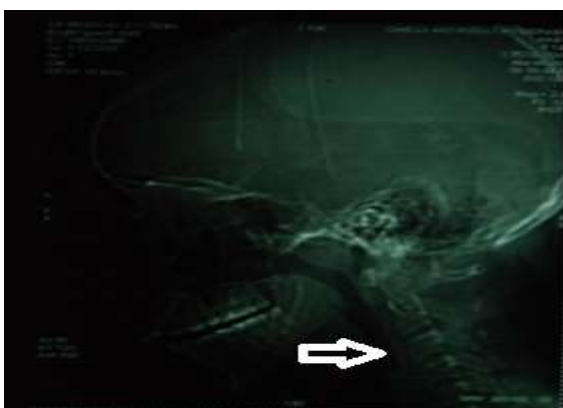

Fig. 2: Showing no thyroid gland at normal position

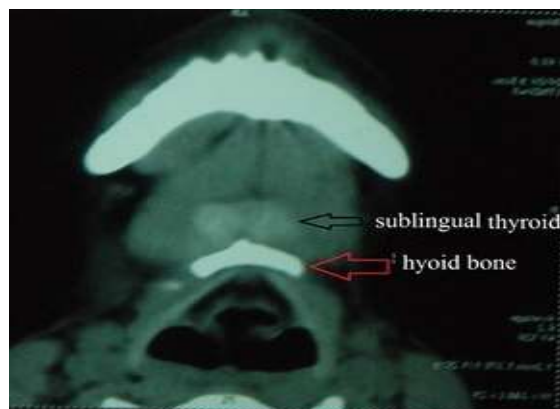


Fig. 3: Thyroid gland in front of the hyoid bone

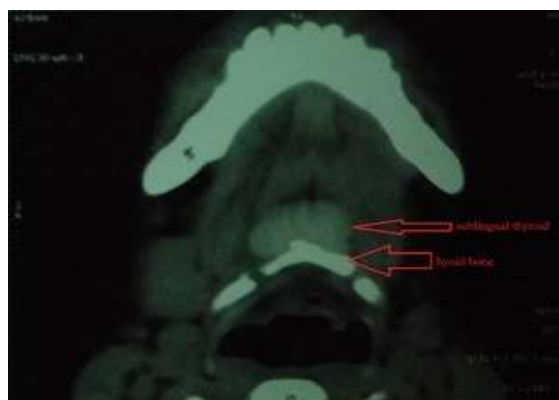


Fig. 4: The two lobes of thyroid gland in front of the hyoid bone

Discussion

Hickman was the first person to diagnose the lingual thyroid gland in 1869. Histopathological examination should reveal the presence of thyroid follicles in the sample taken from the lesion for it to be labeled as lingual thyroid which was started by Montgomery⁽¹⁾. The incidence of Lingual thyroid is reported as 1:100,000. It is 7 times more in females than in males⁽²⁾. The presence of Lingual thyroid will lead to obstruction at the oropharyngeal junction and produces signs & symptoms of dysphagia (mild or severe), dysphonia and dyspnea. Also it can cause sleep apnoea syndrome, fullness in throat, the most common symptoms produced in neonates will be stridor due to obstruction.⁽³⁾ Insufficient working of thyroid gland due to its abnormal position will show hypothyroidism in about 33% of cases. The clinical presentation of Lingual thyroid could be classified into two groups according to the appearance of the symptoms. Lingual thyroid gland detected in routine screening of infants and young children results in failure to thrive, mental retardation or severe respiratory distress syndrome leading to medical emergency.^(3,4) Second group of cases will present with slow onset of dysphagia which is progressive and obstructive symptoms at oropharyngeal junction before or at the time of puberty which could be due to increased demand of the thyroid

gland in the hypermetabolic states. It also includes the cases of pregnancy, infections, trauma, menopause, etc which also requires increased thyroxine in the metabolic stress period.⁽⁵⁾ Lingual thyroid usually presents itself as a midline, nodular mass at the base of the tongue^(6,2,7). The pathogenesis of lingual thyroid is not known, according to postulations of some authors maternal antithyroid immunoglobulins can impair the descent of gland in early fetal life⁽³⁾.

Sporadic cases of Ectopic Thyroid is more common but the first degree relatives are more susceptible to it. This has led most investigators to propose dominant inheritance of a mutation with variable penetrance⁽⁸⁾. On the other hand, compilation of all pairs of monozygotic (MZ) twins reported since screening began revealed that all were discordant for thyroid ectopy⁽⁹⁾ with a single exception⁽¹⁰⁾. Systematic discordance has since been confirmed by others^(11,12). The higher prevalence of thyroid ectopy among Caucasians than among black Africans⁽¹³⁾ who are more genetically diverse is a predisposing factor. Though generally isolated, thyroid ectopy has been shown to be associated with congenital heart disease, specifically septation defects, in several studies^(8,14,&15). Prevalence rates of sublingual thyroid vary from 1 in 100,000 to 1 in 300,000, with females to male ratio ranging from 4:1 to 7:1⁽¹⁶⁾. Other sites of ectopic thyroid tissue can be between the geniohyoid and mylohyoid muscles (sublingual thyroid), above the hyoid bone (prelaryngeal thyroid) and rarely it can be present in the mediastinum, pericardial sac, heart, breast, pharynx, oesophagus, trachea, lung, duodenum, and also the mesentery of small intestine, adrenal gland⁽¹⁷⁾ According to Nucharin Supakul et.al; 40% of the hypothyroid cases have sublingual thyroid i.e. out of 121 cases of hypothyroidism 49 cases had sublingual thyroid examined by ultrasonography⁽¹⁸⁾. No treatment is required if the patient is euthyroid. The planning for the treatment of choice depends on the general conditions of patient, the size of the lesion, and presence of local symptoms or complications, such as haemorrhage, cystic degeneration, or malignancies⁽¹⁹⁾. In this case as the patient's treatment has been started early before attaining the age of 2 years the symptoms are minimal. The height and IQ of the patient is also near normal. There was no signs of cretinism and speech problems. Transplantation of the thyroid gland at normal position is not recommended in this case and substitutive hormonal therapy is to be done.

Conflict of interest

The authors declare that they have no conflict of interests.

Funding: None

Ethical approval

This is an original case report. We accept the norms and conditions of the journal.

Acknowledgement

The study was undertaken under the able guidance of Dr. Anantha Kumari Professor & HOD, Department of Anatomy my, Deccan College of Medical Sciences. I express my gratitude to my son Syed Hamza Quadri, and also I thank my college photographer Mr. Sagar for helping me.

References

1. Burkart C.M., Brinkmann J.A., Willging J.P., Elluru R.G. Lining of Lingual Cyst by squamous epithelium. *Int J Pediatr Otorhinolaryngology*. 2005;69(December (12)):1649–1653. [PubMed]
2. Douglas P.S., Baker A.W. Lingual thyroid. *MAXILLOFACIAL SURGERY* 1994;32:123–124. [PubMed]
3. Williams J.D., Sclafani A.P., Slupchynskij O., Douge C. Lingual thyroid gland -Evaluation & Management *Ann Otol Rhinol Laryngol*.1996;105:312–316. [PubMed]
4. Rocha-Ruiz A., Beltrán C., Harris P.R., Orellana P., Garcia C., Martinez-Aguayo A. Lingual thyroid causing Dysphagia-A case report. *Rev Med Chil*. 2008;136(January (1)):83–87. [PubMed]
5. Stoppa-Vaucher S., Lapointe A., Turpin S., Rydlewski C., Vassart G., Deladoëy J. Dysphonia due to Ectopic Thyroid Gland. *J Clin Endocrinol Metab*.2010;95(October (10)):4509–4510. [PubMed]
6. Batsakis J.G., El-Naggar A.K., Luna M.A. Thyroid gland ectopias. *Ann Otol Rhinol Laryngol*. 1996;105:996–1000. [PubMed]
7. Benhammou A., Bencheikh R., Benbouzid M.A., Boulaich M., Essakali L., Kzadri M. Ectopic lingual thyroid. *B-ENT*. 2006;2(3):121–122. [PubMed]
8. Castanet M, Polak M, Bonaiti-Pellie C, Lyonnet S, Czernichow P and Leger J: Involvement of genetics in thyroid dysgenesis. *J Clin Endocrinol Metab*. 2001;86:2009–14. PubMed | CrossRef
9. Perry R, Heinrichs C, Bourdoux P, Khoury K, Szöts F, Dussault JH, Vassart G, Van Vliet G. Thyroid Dysgenesis in monozygotic twins. *J Clin Endocrinol Metab*. 2002;87:4072–7. PubMed | CrossRef.
10. McLean R, Howard N, Murray IP: Scintigraphic study of Thyroid Dysgenesis in monozygotic twins. *Eur j Nucl Med*. 1985;10:346–8. PubMed | CrossRef
11. Arriazu M, Pretz D, Gonzalez Sanguinetti A, Adler L, Natta D: Twins at Risk: A False Negative Screening Result for Congenital Hypothyroidism. *Horm Res*. 2008;70(suppl 2):8.
12. Kuehnen P, Grueters A, Krude H. 2009. Two amazing cases of thyroid dysgenesis. *Horm Res*. 71:93–7. PubMed | CrossRef
13. Stoppa-Vaucher S, Van Vliet G, Deladoëy J: Variation by ethnicity in the prevalence of congenital hypothyroidism due to thyroid dysgenesis. *Thyroid*. 2011;21:13–8. PubMed | CrossRef
14. Devos H, Rodd C, Gagne N, Laframboise R, Van Vliet G: A search for the possible molecular mechanisms of thyroid dysgenesis: sex ratios and associated malformations. *J Clin Endocrinol Meta*. 1999;84:2502–6. PubMed | CrossRef
15. Devos H, Rodd C, Gagne N, Laframboise R, Van Vliet G: A search for the possible molecular mechanisms of

- thyroid dysgenesis: sex ratios and associated malformations. *J Clin Endocrinol Meta.* 1999;84:2502–6. PubMed | CrossRef
16. Marina D.j., Sajić S. Lingual thyroid.. 2007;135(March–April (3–4)):201–203. [in Serbian] [PubMed].
 17. Di Benedetto V. Ectopic thyroid gland in the submandibular region simulating a thyroglossal duct cyst: A case report. *J Pediatr Surg* 1997;32:1745-6.
 18. Nucharin Supakul¹, Lisa R.Delaney¹, Aslam R.Siddiqui¹, S.Gregory Jennings¹, Erica A. Eugster² and Boaz Karmazyn¹ Ultrasound for Primary Imaging of Congenital Hypothyroidism *AJR VOLUME-199 ISSUE: 3* 2012
<http://www.ajronline.org/doi/full/10.2214/AJR.11.7905>.
 19. Toso A, Colombani F, Averono G, Aluffi P, Pia F. Lingual thyroid causing dysphagia and dyspnoea. Case reports and review of the literature. *Acta Otorhinolaryngologica ital.* 2009;29:213-7.