

Content available at: <https://www.ipinnovative.com/open-access-journals>

Indian Journal of Clinical Anatomy and Physiology

Journal homepage: <https://www.ijcap.org/>

## Original Research Article

## Morphological analysis of Humeroulnar arcade and its practical implications: A cadaveric observational study

S Raghavalakshmi<sup>1</sup>, Magi Murugan<sup>2\*</sup>, Rajprasath Ramakrishnan<sup>3</sup>,  
V Dinesh Kumar<sup>4</sup>, Rema Devi<sup>2</sup><sup>1</sup>Pondicherry Institute of Medical Sciences, Kalapet, Puducherry, India<sup>2</sup>Dept. of Anatomy, Pondicherry Institute of Medical Sciences, Puducherry, India<sup>3</sup>All India Institute of Medical Sciences, Madurai, Tamil Nadu, India<sup>4</sup>Jawaharlal Institute of Postgraduate Medical Education and Research, Puducherry, India

## ARTICLE INFO

## Article history:

Received 30-07-2024

Accepted 21-08-2024

Available online 17-10-2024

## Keywords:

Cubital tunnel syndrome

Osborne's ligament

Ulnar nerve

Nerve compression

Cubital tunnel retinaculum

## ABSTRACT

**Background:** Cubital tunnel's roof is made of a fibrous band of tissue called Osborne's ligament which extends between the two heads of the flexor carpi ulnaris muscle. This band is a potential cause of ulnar nerve compression in the cubital tunnel.

**Materials and Methods:** A total of 30 embalmed cadaver was used and were classified using the O' Driscoll classification. At different angles of the elbow flexion [20-140 degrees], the tautness of the ligament was noted and the variation of the length of the ligament concerning these angles was found by using the digital Vernier callipers.

**Results:** 20 cadavers had type 1b, 7 cadavers had type 0, 3 had type 1a and no cadaver had type 2 Osborne's ligament. The percentage of ulnar nerve compression is more between 80 to 110 degrees of flexion maximum being 90 degrees.

**Conclusion:** The knowledge of this anatomy may help in treating ulnar nerve compression safely using anterior nerve transposition techniques and analysing the post-surgical MRI images of the cubital tunnel area.

This is an Open Access (OA) journal, and articles are distributed under the terms of the [Creative Commons Attribution-NonCommercial-ShareAlike 4.0 License](https://creativecommons.org/licenses/by-nc-sa/4.0/), which allows others to remix, tweak, and build upon the work non-commercially, as long as appropriate credit is given and the new creations are licensed under the identical terms.

For reprints contact: [reprint@ipinnovative.com](mailto:reprint@ipinnovative.com)

## 1. Introduction

Ulnar nerve (C8, T1) originates from the medial cord of the brachial plexus in the axilla where it is related to axillary artery medially. It then travels along the medial aspect of the brachial artery in the arm, then behind the elbow, and down along the medial aspect of the forearm, and into the palm. It has both motor and sensory innervation to the upper limb.<sup>1</sup> Along the entire course ulnar nerve compression can occur at any site from the nerve roots to the brachial plexus, in the elbow, forearm or wrist. Ulnar nerve entrapment in the elbow within the cubital tunnel is known as cubital tunnel

syndrome. This name was coined by Findel and Stratford in 1958.<sup>2</sup> After carpal tunnel syndrome, which is caused by the median nerve compression, the next common cause of nerve compression in the upper limb is cubital tunnel syndrome.<sup>3</sup> The proximal and first area of compression of the ulnar nerve is in the middle of the arm where the arcade of Struthers is present in 70% of population.<sup>4</sup> It is a musculofascial band of 1.5 to 2 cm width and presents 8 cm above the medial epicondyle. It is made of the deep fascia of the arm, fibres from the medial head of the triceps and interbrachial ligament that arises from the coracobrachialis tendon

The second site of compression may be at or proximal to the medial epicondyle as a result of malunited

\* Corresponding author.

E-mail address: [dr.ramkirajmbbs@gmail.com](mailto:dr.ramkirajmbbs@gmail.com) (M. Murugan).

supracondylar fracture.<sup>5</sup> The third site of compression is at the level of the cubital tunnel. The cubital tunnel is an elliptical tunnel which is bounded medially by the two heads of flexor carpi ulnaris, floor is formed by the elbow joint, medial collateral ligament, olecranon process and anteriorly is bounded by the medial epicondyle.<sup>6</sup> The roof of the cubital tunnel is made up of the fibrous band, 4mm in length and extends between the olecranon process and medial epicondyle between the two heads of flexor carpi ulnaris muscle and is termed as cubital tunnel retinaculum.<sup>7</sup> On ultrasound, the retinaculum is made of a trilaminar structure of fascial, tendinous and muscular layers with a mean thickness of  $0.9+0.3\text{mm}$ .<sup>3</sup> It has also been referred to as Osborne's fascia, Osborne's band and arcuate ligament or tendinous arch.<sup>8</sup>

According to O'Driscoll et al.,<sup>6</sup> the various types of cubital tunnel retinaculum are:

Type 0: Absence of retinaculum and the dislocated ulnar nerve.

Type 1a: Thin normal retinaculum becoming taut in full flexion, but the nerve is not compressed.

Type 1b: Abnormally thick and between 90 to 120 degrees of flexion it becomes taut. It is associated with chronic nerve compression.

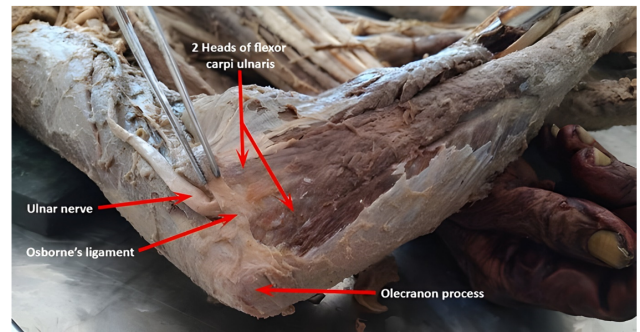
Type 2: The retinaculum is replaced by the anconeus epitrochlearis muscle.

Recent studies have shown that chronic repetitive strain in the medial aspect of the elbow can cause hypertrophy of Osborne's ligament in the cubital tunnel which in turn causes compression of the ulnar nerve. The diagnosis of cubital tunnel syndrome remains a challenge as patients do not recognise it until the symptoms are severe and the nerve is damaged.<sup>9</sup> Patients often present with both motor and sensory deficits with a less favourable prognosis.

The studies which had correlated the sub-types and dimensions of Osborne's ligament are scarce particularly in the Indian population. Hence this study is undertaken to study the morphology of the Osbornes ligament, its types and the correlation between the tautness produced by the ligament on the ulnar nerve during different degrees of flexion.

## 2. Materials and Methods

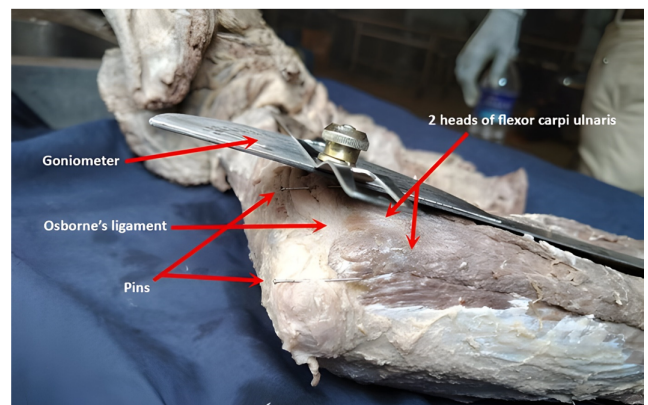
A total of 30 embalmed upper limbs were used for the study after obtaining Institute research and [Ethics committee clearance RC/19/16]. All of them were from the dissected cadavers used for medical undergraduate training after their upper limb dissection was done. Sample size was calculated by convenient sampling method based on the availability of cadavers for undergraduate teaching. Dissection was done according to Yamada et al.<sup>10</sup> The medial aspect of the elbow was opened. To directly measure the angle of flexion, soft tissues were excised to expose the shaft of humerus and Osborne's ligament. (Figure 1)



**Figure 1:** Showing the extension of Osborne's ligament

The angle of flexion and the ligament length were measured using the following bony landmarks: humerus proximally, ulna distally and the tip of the medial epicondyle of the humerus. The type of Osborne's ligament was identified based on O'Driscoll's classification. The incidence of the different types of the ligament was tabulated. The site of attachment of humeral and ulnar heads of flexor carpi ulnaris was identified.

In the presence of Osborne's ligament, the closest distance of two ends of the ligament from the elbow joint were analysed by 2 investigators by holding a pin at each point. In the absence of ligament, the closest distance between the elbow joint and the proximal attachment of the 2 heads of flexor carpi ulnaris was marked. (Figure 2) The elbow flexion angle was measured using goniometer with the medial epicondyle of the humerus being the fixed point and the 2 scales being parallel to the arm and the forearm.



**Figure 2:** Showing the measurements of Osborne's ligament with goniometer

The tautness of the ligament was noted at different angles of the elbow flexion [20-140 degrees] and the variation of the length of the ligament concerning these angles was found by using the digital Vernier callipers. The average and median length of this ligament were taken and tabulated. The compression of the ulnar nerve was also analysed

simultaneously with these varying angles and tabulated.

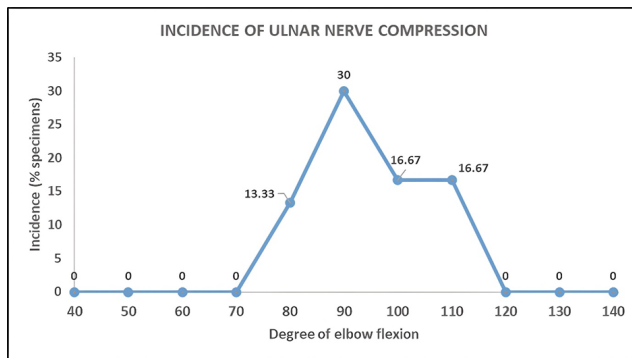
### 3. Results

Among the 30 cadavers dissected Osborne's ligament was classified according to O Driscoll classification. 20 cadavers had Type 1b type of Osborne's ligament, 7 cadavers had type 0 and 3 cadavers had type 1a type of Osborne's ligament and no cadaver had type 2 Osborne's ligament (Table 1).

**Table 1:** The different subtypes of Osborne's ligament observed in the study

Types	Number of Cadavers [in percentage]
Type 0	23
Type 1a	10
Type 1 b	67
Type 2	0

The Table 1 shows that for every 10 degrees rise in the elbow flexion the length of Osborne's ligament increases up to 100 degrees and a further increase in elbow flexion decreases the length of Osborne's ligament. Among 30 cadavers, ulnar nerve compression is observed between 80 to 110 degrees of elbow flexion (Figure 3) with the maximum being at 90 degrees. (Table 2)



**Figure 3:** Incidence of ulnar nerve compression in varying degrees of elbow flexion

### 4. Discussion

Cubital tunnel syndrome is one of the frequent causes of ulnar nerve entrapment and presents as chronic pain in the forearm and hand regions. Osborne's ligament is an eponymous structure which extends between the medial epicondyle and olecranon process and could potentially induce extra neural pressure on the ulnar nerve. Various theories had been put forward regarding the entrapment and the description given by them remains polymorphic including it being a structural tautness of ligament, ligament stretching, compression of the nerves and cubital tunnel narrowing. Hence, this study was undertaken to observe various morphological patterns of Osborne's ligament and

**Table 2:** Showing the length of Osborne's ligament with varying degrees of elbow flexion

Angle of Elbow Joint [degree]	Mean Length [cm]
40	2.58
50	2.34
60	2.34
70	2.33
80	2.35
90	2.38
100	2.22
110	2.12
120	2.15
130	2.11
140	2.11

explore the relationship between them and ulnar nerves at the cubital tunnel during varying degrees of elbow flexion. Various authors studied the different types of Osborne's ligament in which different subtypes were predominant.<sup>7,10,11</sup> In the present study Type 1b was predominant and was seen in 20 specimens and the next type was type 0 and then type 1a and there were no cadavers with type 2 Osborne's ligament.

In the present study, the length of the ligament and the tautness of the ulnar nerve were found to increase with increasing degrees of flexion. The length of Osborne's ligament was more at 120-degree flexion than at 20 degrees or 40 degrees. The stretching of Osborne's ligament begins at 60 degrees of flexion and increases with increasing flexion angle and the mean length being 2.38 mm at 90 degrees. Our finding was similar to the study by Schuind et.al of 5 elbows where with the elbow flexion the ulnar nerve was progressively stretched. The proximal site of the ulnar nerve was elongated by 18% and the length of the cubital tunnel retinaculum by 45% during elbow flexion.<sup>12</sup>

Vanderpool et al. dissected 18 cadavers and observed that there was an increase of 5mm distance between the ulnar and humeral attachment of aponeurosis for 45 degrees of flexion, elongation being 40% from full extension to 135 degrees of flexion.<sup>13</sup> In another study by Yamada et.al, the mean increase in length of the ligament from extension to flexion was 6.2 mm in the left elbow and 7.3 mm in the right elbow. They compared between male and female gender which was 7.5 mm in males and 6.12 mm increase in the female group. But in our study, the length increased from 2.34 mm to 2.38mm with an increase in elbow flexion from 40 degrees to 90 degrees.<sup>10</sup>

Also in the present study, the cubital tunnel area decreased with the increasing flexion angle of the elbow i.e., the area at 120 degrees was less when compared at 40 degrees or 60 degrees. This feature was similar to the study by Range et.al where the cubital tunnel volume decreased with the flexion of elbow and may cause nerve compression against the cubital tunnel retinaculum. The cubital tunnel

can be visualised with the help of MRI and Osborne's band with the extended and supine elbow or extended overhead and prone elbow.<sup>14</sup> Findel and Stratford stated that with elbow flexion there is a bulging of the collateral ligament from the floor, as a result, the pressure in the cubital tunnel is increased and there is stretching of Osborne's band which could compress the ulnar nerve and cause entrapment neuropathy.<sup>2</sup>

Bradshaw YD et al., stated that many variations of the Humero-ulnar arcade can contribute to ulnar nerve compression.<sup>15</sup> The Humeroulnar arcade retinaculum can be hypertrophied causing ulnar nerve compression or maybe an absence causing subluxation of the nerve which occurs in 5 to 30% of individuals. Subluxation may occur either unilaterally or bilaterally.

## 5. Conclusion

Ulnar nerve compression can be safely treated if the dynamic anatomical relationships of the ulnar nerve and cubital tunnel is best understood. Maximum incidences of ulnar nerve compression were observed between 80-110 degrees of elbow flexion. This range of elbow flexion is commonly involved in our day-to-day activities like drinking from a cup, using a laptop or a cell phone etc. Thus, we hypothesize that individuals with type 1b Osborne's ligament are vulnerable to ulnar nerve compression and this risk becomes higher if they harbour activities which induce repetitive chronic micro-trauma.

## 6. Source of Funding

None.

## 7. Conflicts of Interest

The authors declare that they have no competing interests.


## References


- Guru A, Kumar N, Shanthakumar SR, Patil J, Badagabettu SN, Padur AA, et al. Anatomical Study of the Ulnar Nerve Variations at High Humeral Level and Their Possible Clinical and Diagnostic Implications. *Anat Res Int*. 2015;2015:378063.
- Feindel W, Stratford J. The role of the cubital tunnel in tardy ulnar palsy. *Can J Surg J Can Chir*. 1958;1(4):287–300.
- Wojewnik B, Bindra R. Cubital tunnel syndrome — Review of current literature on causes, diagnosis and treatment. *J Hand Microsurg*. 2001;1(2):76–81.
- Elmaraghi S, Taylor R, Tung I, Patterson MM, Mackinnon SE. Compression of the Ulnar Nerve by the Arcade of Struthers: Look and You Shall Find. *Hand (N Y)*. 2024;23:15589447241232013.
- Posner MA. Compressive ulnar neuropathies at the elbow: I. Etiology and diagnosis. *J Am Acad Orthop Surg*. 1998;6(5):282–8.
- Macchi V, Tiengo C, Porzionato A, Stecco C, Sarasin G, Tubbs S, et al. The cubital tunnel: a radiologic and histotopographic study. *J Anat*. 2014;225(2):262–9.
- O'driscoll SW, Horii E, Carmichael SW, Morrey BF. The cubital tunnel and ulnar neuropathy. *J Bone Joint Surg Br*. 1991;73(4):613–7.
- Husarik DB, Saupe N, Pfirrmann CWA, Jost B, Hodler J, Zanetti M. Elbow nerves: MR findings in 60 asymptomatic subjects—normal anatomy, variants, and pitfalls. *Radiology*. 2009;252(1):148–56.
- Molter MW, Mehnert MJ, Ilyas AM. Cubital Tunnel Syndrome: Evaluation and Diagnosis. In: *Cubital Tunnel Syndrome*. Springer; 2019. p. 29–52.
- Yamada K, Nagaoka M, Nagao S, Nagai T, Yamaguchi T, Ryu J, et al. Anatomical Study of Osborne's Ligament Elongation in Relation to Elbow Flexion. *J Nihon Univ Med Assoc*. 2013;72:154–8.
- Silva R, Pinto LF, Ferreira F, Pereira P, Madeira D, Pinho A. Osborne's ligament: a cadaveric study and literature review. *MOJ Orthop Rheumatol*. 2020;12(5):114–7.
- Schuind FA, Goldschmidt D, Bastin C, Burny F. A biomechanical study of the ulnar nerve at the elbow. *J Hand Surg Edinb Scotl*. 1995;20(5):623–7.
- Vanderpool DW, Chalmers J, Lamb DW, Whiston TB. Peripheral compression lesions of the ulnar nerve. *J Bone Joint Surg Br*. 1968;50(4):792–803.
- Range TL, Samra NS. Anatomy, Shoulder and Upper Limb, Osborne Band. Treasure Island [FL]: StatPearls Publishing; 2023. [cited 2023 Nov 22]. Available from: <http://www.ncbi.nlm.nih.gov/books/NBK536999/>.
- Bradshaw DY, Shefner JM. Ulnar neuropathy at the elbow. *Neurol Clin*. 1999;17(3):447–61.


## Author biography

**S Raghavalakshmi**, Resident

**Magi Murugan**, Professor  <https://orcid.org/0000-0002-8458-479X>

**Rajprasath Ramakrishnan**, Assistant Professor  <https://orcid.org/0000-0003-0902-364X>

**V Dinesh Kumar**, Associate Professor  <https://orcid.org/0000-0001-8234-2829>

**Rema Devi**, Professor  <https://orcid.org/0000-0003-4840-0313>

**Cite this article:** Raghavalakshmi S, Murugan M, Ramakrishnan R, Kumar VD, Devi R. Morphological analysis of Humeroulnar arcade and its practical implications: A cadaveric observational study. *Indian J Clin Anat Physiol* 2024;11(3):174-177.