

Content available at: <https://www.ipinnovative.com/open-access-journals>

Indian Journal of Clinical Anatomy and Physiology

Journal homepage: <https://www.ijcap.org/>

Original Research Article

Morphological variations of the superficial brachial artery in cadaveric study: An embryological and clinical correlation

T Prabhakar^{1*}, Vinodkumar Gurram², Rakesh Kumar¹, Gunwant Choudhari¹¹Dept. of Anatomy, Zydus Medical College, Dahod, Gujarat, India²Dept. of Anatomy, SSPM Medical College & Lifetime Hospital, Padve, Maharashtra, India

ARTICLE INFO

Article history:

Received 01-08-2024

Accepted 17-09-2024

Available online 17-10-2024

Keywords:

Superficial brachial artery

Anatomical variation

Deep brachial artery

Axillary artery

ABSTRACT

Background: The axillary artery (AA) branches into six vessels within the axilla. The brachial artery then continues at the teres major muscle's lower border. The brachial artery (BA) splits into the ulnar and radial terminal branches at the level of the radius neck or the cubital fossa. The underlying BA is an uncommon variant of the axillary artery that can have an impact on neural structures. This study aims to analyze the morphological relationship between the superficial brachial artery (SBA) originating from the AA and the segmental variation of the AA.

Materials and Methods: The research done in the Anatomy Department of Zydus Medical College and Hospital in Dahod involved the examination of the 16 upper limb of 8 cadavers. These cadavers were obtained over the course of one year and were used for undergraduate study in the First MBBS program. The dissection was done in the axilla and the arm. During the routine anatomy, dissection was observed a variant of the SBA and its termination.

Observation and Results: For this investigation, six Arm specimens were dissected. We have noticed a superficial brachial artery with an axillary origin in 2 cadavers. In the left arm, there was only one case (1.0%) of the SBA, which assets the arm muscles. There was only one case (1.0%) of SBA in the right arm merging with the deep brachial artery (DBA) in the Cubital fossa and extending as the radial artery (RA) of the forearm.

Conclusion: Variations of SBA have significance essential during surgical procedures. Morphological variations, as well as topographical variations, are significant factors in surgery of "upper limb as well as regular clinical practice. The use of surgical techniques is crucial in order to prevent injury to arteries, particularly in the upper limb as well as axilla regions.

This is an Open Access (OA) journal, and articles are distributed under the terms of the [Creative Commons Attribution-NonCommercial-ShareAlike 4.0 License](https://creativecommons.org/licenses/by-nc-sa/4.0/), which allows others to remix, tweak, and build upon the work non-commercially, as long as appropriate credit is given and the new creations are licensed under the identical terms.

For reprints contact: reprint@ipinnovative.com

1. Introduction

The artery known as the brachial artery is an extended version of the AA, located either below the latissimus dorsi" muscle tendon or at the teres major muscle lower periphery. BA consistently remains "in close proximity to the median nerve (MN) throughout its course.¹ It usually ends in the Cubital fossa, at the level of the radius neck, close to the

front of the elbow. There, it splits into the radial as well as ulnar arteries, which are the two terminal branches. An example of this variation is the SBA, which arises from the AA and passes above the median nerve and in front of the arm muscles. It can be slightly more to the side than"the brachial artery and follow a winding path.^{2,3} Superficial variations of the BA are frequently noted along can have an effect on neural structures.

Throughout routine dissections, it is common to come across "variations in the arterial pattern of the upper limb.

* Corresponding author.

E-mail address: prabhakar55@gmail.com (T. Prabhakar).

One of the significant variations is the superficial brachial artery (SBA).⁴ As per the literature, its frequency as well as pattern of branching” differ between the ethnic groups.

The SBA existence can pose a significant risk due to its high susceptibility towards injury.⁵ An accidental injection into an artery through the subclavian artery (SBA) can result in the formation of blood clots or tissue death, which may necessitate the removal of the affected arm/fingers.⁶ Alternatively, the SBA serves as the source of blood supply to a free flap originating from the skin of the inner arm.⁷ Recognizing these potential complications and advantages, examining the arterial pattern in patients’ arms prior to hostile approaches might assist in preventing iatrogenic harm or utilizing a subclavian artery for certain procedures. When managing patients with an SBA condition, healthcare professionals can benefit from the use of Doppler ultrasound imaging/angiography.⁸ Regardless of the availability of those devices, a comprehensive understanding of the anatomical structure of SBA is crucial.

2. Materials and Methods

The research had been performed on 16 limbs from 8 adult embalmed cadavers, consisting of 6 males and 2 females. During the result of the undergraduate study (First phase MBBS) for medical students at the Anatomy Department, Zydus Medical College & Hospital, Dahod, a routine dissection was performed to examine variations in the upper arm. The process of dissection was performed in accordance with the protocols outlined in Cunningham’s Manual of Practical Anatomy Vol I. The upper arms, which were believed to have differences, were further examined through dissection. The course of study and ramifications of the SBA originating from the axilla were documented.

3. Results

Out of the 16 extremities examined in this study, a SBA was found in two upper limbs. Initially, the slender superficial brachial artery was observed to provide blood to the “arm’s muscles and terminated in the arm. It was discovered in a solitary instance, accounting for only 1.0% of the cases. The subscapular artery, AHCA (Anterior Humeral Circumflex Artery), and PHCA (Posterior Humeral Circumflex Artery) originate from the AA instead of the subscapular artery itself.

3.1. Specimen no 1

Through dissecting the upper extremities of the 78yr. old male cadaver, a variation had been” discovered in a specimen of the right upper arm. The SBA is a branch of the AA that appears between medial root and lateral root of the MN in the axilla. It runs in front of the arm muscles, superficial to the MN, and may be slightly more laterally positioned than the brachial artery. The SBA follows a

convoluted path (Figure 1). Arm muscles received blood from the thin SBA. It was found to terminate in the arm in only one case, accounting for 1.0% of the cases.

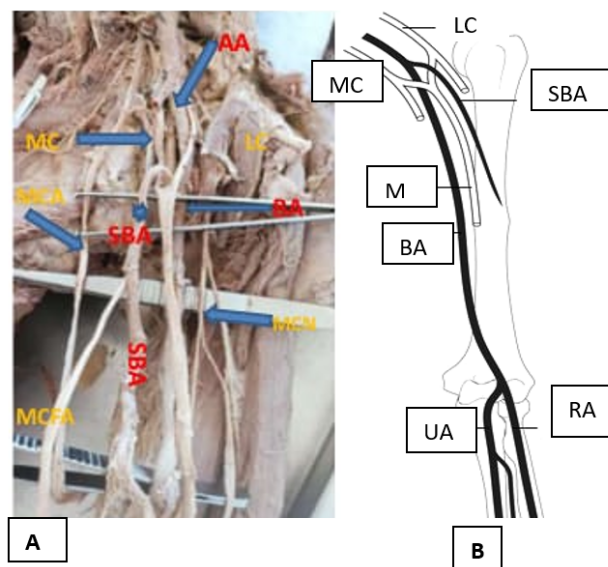


Figure 1: Photograph (A) and illustration diagram (B) of type I SBA; the slender SBA supplied the arm muscles and ended in the “superficial fascia of the upper arm. AA, axillary artery; BA, brachial artery; LA, lateral cord; MC, medial cord; MCN, musculocutaneous nerve of Arm; MN, median nerve; SBA, superficial brachial artery

3.2. Specimen no 2

The second specimen exhibited variation in the right arm. The AA above the humeral circumflex arteries stems and below the subscapular artery is where the SBA originated. The SBA is located in the area between the median nerve’s medial and lateral roots. It is located in front of the elbow and extends as an RA, which joins with the DBA in the Cubital fossa (Figure 2). As it traverses along the arm, the AA gives rise to the DBA, which is situated posterior-medially to the MN. The ulnar artery in the Cubital fossa is subsequently formed by the DBA.

4. Discussion

A novel theory that emphasizes the genesis of all major arterial trunks in the upper limbs from a primitive network of small blood vessels was presented by Rodríguez-Niedenführ et al. in 2001.^{9–11} This theory provides a simple explanation for all documented variations in the upper limb arteries. Arey¹² “and Jurjus et al¹³ proposed six justifications for the documented variations: i. The selection of rare routes in the basic network of blood vessels, ii. the continuation of vessels that are typically closed off, iii. The vanishing of vessels which are typically

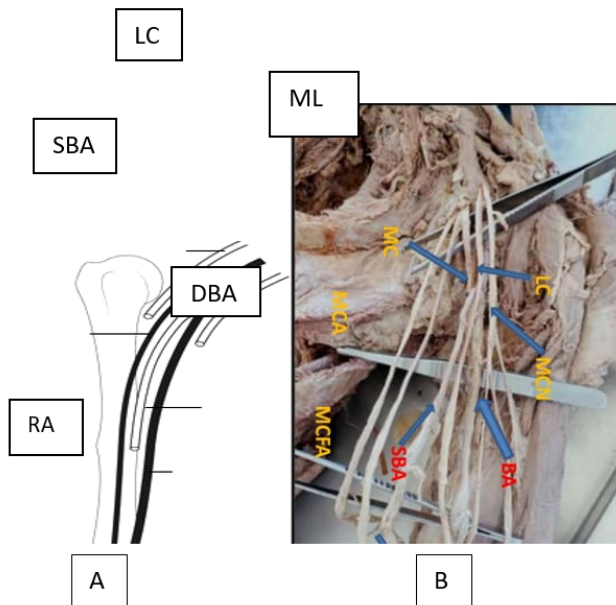


Figure 2: Illustration diagram (A) and Photograph (B) showing “superficial brachial artery continued as radial artery; AA, axillary artery; DBA, brachial artery; LA, lateral cord; MC, medial cord; MCN, musculocutaneous nerve of Arm; MN, median nerve; SBA, superficial brachial” artery

preserved, iv. the incomplete” growth, iv. The process of combining and incorporating distinct components that are usually separate.; and 6. An abnormal arrangement is caused by a combination of factors. The SBA plays a crucial role during fetal development by serving as a means to substitute or assist the definitive BA.¹⁰ According to Rodriguez-Baeza et al.,⁹ the SBA’s survival is assessed by the hemodynamic predominance of particular arterial segments throughout development. The SBA is a necessary blood vessel that does not indicate failure in the process of normal morphogenesis. The SBA arises from the AA during the fourth stage of vascular development in the upper limb.¹¹ Multiple deep branches connect it to the AA at the axilla, upper arm, and elbow levels.⁵

This instance involves an SBA, the coexistence of fused arteries, AA or BA branching, and the migration of the arteries. According to Singer’s elaborated research,^{14,15} “the upper limb arterial variants are remnants of earlier embryonic arterial trunks, like”AA, which typically regresses after the eighth developmental week.

The research (Figure 1) shows that the course of the BA is encapsulated between the MN roots; it is then separated into the primary BA, which is located “posterior to the MN, and the SBA, which is located anterior to the MN. Tubbs et al.¹⁶ reported that the slender SBA ended in the arm and supplied the arm” musculature in eight percent of cases. The majority of BA occurrences are documented posterior to the

MN in 75% of cases.¹⁶

Regarding the present case (Figure 2), 2 different terminations of the brachial have been recognized. The left-sided SBA produced the RA, as well as the primary BA produced the typical interosseous artery and continued as the ulnar artery. This pattern had been detected in 5% of the cases¹⁷. At a rate of 70%, the SBA’s most common conclusion in the RA and UA was noted¹⁶. Keen¹⁸ noted the division and course of three SBA morphological types: 1. “an SBA that divides into the Cubital Fossa; 2. an SBA that persists as RA, sometimes referred to as the ‘RA high origin’; Rodriguez-Niendenfuhr et al.⁹ It has been suggested that the term ‘superficial brachioradial artery’ is another relevant description.

The DBA originates directly from the AA in the present case. In the Przybycien et al. meta-analysis,⁴ The frequency of DBA originating directly from either AA or BA was determined to be 92.87percent, while the indirect origin through a common trunk was found to be 7.13%, which closely aligns with the classification proposed by Charles et al.¹⁹ The origin of DBA is derived from a shared trunk with the proximal circumflex humeral artery, as observed in 4% of cases in the investigation done by Charles et al.¹⁹ Charles”et al. categorized DBA into seven distinct morphological types.¹⁹

Regarding our specific situations, Type I SBAs frequency is comparable to the most frequently occurring phenomenon in the existing body of literature. Out of 200 arms, Fuss et al. found 17 cases (8.5%, referred to as “Type 3” “in their report).⁴ The frequency that Skopakoff et al. found to be comparable.¹⁷

The SBA superior arose among the brachial plexus’s medial as well as lateral cord or arose medially to these cords. SBA media originated on the MN more distally than regular ones, between the brachial plexus’ lateral and medial cords. At the MN, the SBA inferior rises medially. Medial as well as lateral SBA are the two subtypes of SBA according to Adachi (1). The position of an SBA in relation to the medial cord of the brachial plexus of the ulnar nerve is the” standard method used to determine whether the SBA is medial or lateral. Comparing the two previously mentioned classifications, ours is unique since it allows the brachial plexus to produce typing on its own. According to Keen, Type II SBA extends into the forearm as the RA. Fuss et al. call it “Type 5,” and Skopakoff et al. (3, 4, 26) cite 6%, 7%, and 9% prevalence. Western populations are most likely to have Type II SBA, which causes RA. They include Chakravarthi.²⁰ 7.14 percent of Indians had SBA in 2014. However, compared to cadavers from other regions of the world, the frequency of this kind of SBA in Indian cadavers is lower (2.3percent). Stated differently, Type I is the most common SBA found in Indian cadavers. It is challenging to look into the Type III SBA in our research in other literature. There are no distinctly defined artery branches as it narrows

in the upper arm. Because it is located on the upper arm's deep fascia, this artery is undoubtedly categorized as an SBA.

To summarize, the examination “of the arms of Indian cadavers demonstrated that the SBA, which persists as the radial artery, is the most common type of SBA as reported in past literature studies. There is a kind of SBA that terminates in the upper arm” documented in our study. No instances of superficial ulnar arteries have been documented in our records.

5. Conclusions

The BA more specifically, the SBA plays a crucial role primarily “in upper limb surgery morphological as well as topographical variants, in everyday clinical practice. The use of surgical techniques is essential to preventing arterial damage; in complex cases, preoperative imaging should be regarded. It should be mentioned that neurological variations may also exist in these instances, which could complicate surgical method.

6. Source of Funding

None.

7. Conflict of Interest

None.

Acknowledgments

The authors extend their deepest appreciation to all individuals who generously donated their bodies for the purpose of advancing anatomical research. The results of this kind of research could improve patient care by furthering human understanding. For this reason, we are extremely grateful to those donors and their families.

References

- Mccormack LJ, Cauldwell EW, Anson BJ. Brachial and antebrachial arterial patterns; a study of 750 extremities. *Surg Gynecol Obstet.* 1953;96(1):43–54.
- Fuss FK, Matula CW, Tschabitscher M. Die Arteria brachialis superficialis. *Anat Anz.* 1985;160:285–94.
- Yoshinaga K, Tanii I, Kodama K. Superficial brachial artery crossing over the ulnar and median nerves from posterior to anterior: embryological significance. *Anat Sci Int.* 2003;78:177–80.
- Kawashima T, Yoshitomi S, Sasaki H. Anatomical relationship between the superficial brachial arteries and the brachial plexus in humans, and their morphological significance. *Folia Morphol (Warsz).* 2004;63:465–71.
- Yalcin B, Kocabiyik N, Yazar F, Kirici Y, Ozan H. Arterial variations of the upper extremities. *Anat Sci Int.* 2006;81(1):62–4.
- D'Costa S, Shenoy BM, Narayana K. The incidence of a superficial arterial pattern in the human upper extremities. *Folia Morphol (Warsz).* 2004;63:459–63.
- Coskun N, Sarikcioglu L, Donmez BO, Sindel M. Arterial, neural and muscular variations in the upper limb. *Folia Morphol (Warsz).* 2005;64(4):347–52.
- Tountas CP, Bergman RA. *Anatomic Variations of the Upper Extremity.* New York: Churchill Livingstone; 1993.
- Singer E. Embryological pattern persisting in the arteries of the arm. *Anat Rec.* 1933;55:403–9.
- Rodríguez-Niedenführ M, Burton GJ, Deu J, Sañudo JR. Development of the arterial pattern in the upper limb of staged human embryos: normal development and anatomic variations. *J Anat.* 2001;199(4):407–17.
- DeGaris CF, Swartley WB. The axillary artery in white and Negro stocks. *Am J Anat.* 1928;41:353–97.
- Arey LB. *Developmental Anatomy.* Philadelphia, Pennsylvania: Saunders Company; 1940.
- Jurjus AR, Correa-De-Aruaujo R, Bohn RC. Bilateral double axillary artery: embryological basis and clinical implications. *Clin Anat.* 1999;12:135–40.
- Zlotolow DA, Catalano LW, Barron OA, Glickel SZ. Surgical exposures of the humerus. *J Am Acad Orthop Surg.* 2006;14:754–65.
- Romanes GJ. *Cunningham's Textbook of Anatomy.* Oxford, United Kingdom: Oxford University Press; 1989. p. 403–9.
- Fuss FK, Matula CW, Tschabitscher M. The superficial brachial artery. *Anat Anz.* 1985;160:285–94.
- Skopakoff C. Variability of branches and distribution of the superficial brachial artery. *Anat Anz.* 1959;106:356–68.
- Yang HJ, Gil YC, Jung WS, Lee HY. Variations of the superficial brachial artery in Korean cadavers. *J Korean Med Sci.* 2008;23:884–7.
- Adachi B. *Das Arteriensystem der Japaner [In German].* Adachi B, editor. Kyoto, Japan: Kyoto University Press; 1928.
- Bolden AM, Schmitt EA, Alsharaf F, Zdilla MJ, Lambert HW. Identifying variants and prevalence of the superficial brachial artery - a case series. *FASEB J.* 2020;34:1.

Author biography

T Prabhakar, Associate Professor  <https://orcid.org/0009-0004-4141-4012>

Vinodkumar Gurram, Assistant Professor

Rakesh Kumar, Assistant Professor

Gunwant Choudhari, Professor and Head

Cite this article: Prabhakar T, Gurram V, Kumar R, Choudhari G. Morphological variations of the superficial brachial artery in cadaveric study: An embryological and clinical correlation. *Indian J Clin Anat Physiol* 2024;11(3):160-163.