

Content available at: <https://www.ipinnovative.com/open-access-journals>

Indian Journal of Clinical Anatomy and Physiology

Journal homepage: <https://www.ijcap.org/>

Case Report

Grade I Meningioma in a cadaver – A case report

Shashikala Londhe^{1*}, Anjali Gosavi¹, Minakshi Kasegaonkar¹, Nilesh Bhosle¹

¹Dept. of Anatomy, Ashwini Rural Medical College and Research Centre, Solapur, Maharashtra, India



ARTICLE INFO

Article history:

Received 31-10-2023

Accepted 07-12-2023

Available online 20-01-2024

Keywords:

Cadaver

Brain

Meninges

Tumor

Grades of tumor

ABSTRACT

Background: In a routine dissection of anatomy department in Ashwini Rural Medical College and Research Centre Kumbhari, Solapur, Maharashtra. While removing the brain from the cadaveric skull.

Case Presentation: Noticed a small tumor of measuring 1.3cm in length, 1.3cm in breadth and 1.2cm in height, situated at the orbital surface of the brain in the gyrus rectus of a male cadaver. In the histological study it was diagnosed as a Meningioma grade I.

Conclusion: It was small size encapsulated tumor on inferior aspect of brain. On histological study, it showed meningo epithelial cells in whorl pattern, blood vessels, fibrous tissue Psammoma bodies, which indicate grade I meningioma.

This is an Open Access (OA) journal, and articles are distributed under the terms of the [Creative Commons Attribution-NonCommercial-ShareAlike 4.0 License](https://creativecommons.org/licenses/by-nc-sa/4.0/), which allows others to remix, tweak, and build upon the work non-commercially, as long as appropriate credit is given and the new creations are licensed under the identical terms.

For reprints contact: reprint@ipinnovative.com

1. Introduction

Meningioma is a benign tumor, arising from the meninges of the brain and the spinal cord. WHO has classified Meningioma into three grades, grade I is common, grade II is atypical and grade III is malignant Meningiomas.^{1,2} Approximately 50% of all benign brain tumors are meningiomas.^{1,3,4} Meningioma originates from the meninges of the brain and the spinal cord.² Meningiomas are commonly benign and are grade I type. Meningiomas are associated with certain conditions and risk factors such as, obesity, alcoholism, exposure to radiation, radiotherapy, hormone replacement therapy, use of oral contraceptive pills, breast cancer. Higher incidence are in females due to hormonal factors.^{2,4,5} Meningioma is common in old age.^{1,6,7} Its higher incidence in African-American with female to male ratio being 2.27:1.^{1,2}

2. Case Presentation

We found this tumor during the routine dissection of brain, from the aged male cadaver. We observed a small round mass situated on the jugum sphenoidale, apart of sphenoid bone in the anterior cranial fossa.

First it was observed on bone, then we noticed a small depressed area on inferior surface of frontal lobe. We correlated size of tumor mass and size of depressed area on brain. Depression of the same size on the orbital surface of the frontal lobe near the medial margin in the gyrus rectus was observed. The depression was encapsulated and the mass was present in that depression.

A tumor measuring 1.3 cm in length, 1.3 cm in breadth and 1.2cm in height was found. Tumor mass was excised and processed with routine histology technique and slides were prepared and stained with haematoxylin and eosin stain.

* Corresponding author.

E-mail address: dr.shashilondhe@gmail.com (S. Londhe).

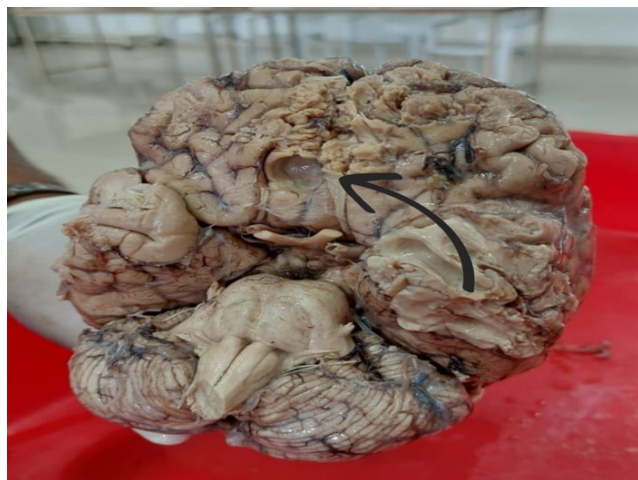

Figure 1: Arrow showing site of the tumor

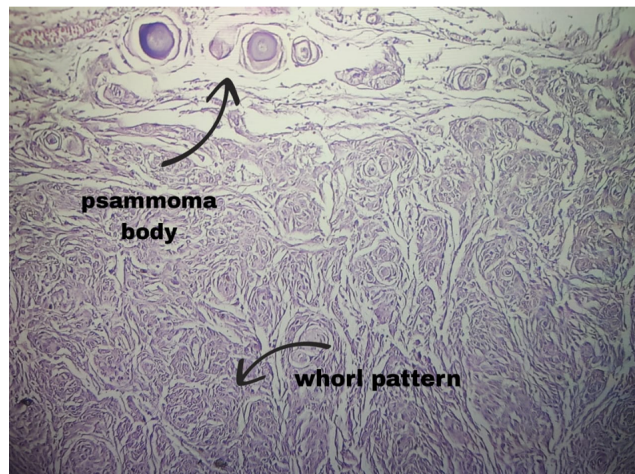


Figure 4: Arrows showing psammoma bodies and whorl pattern of meningo epithelial cells

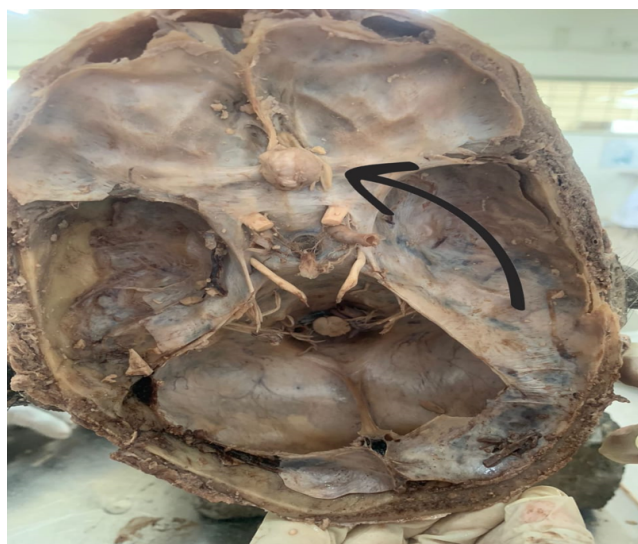

Figure 2: Arrow showing tumor mass

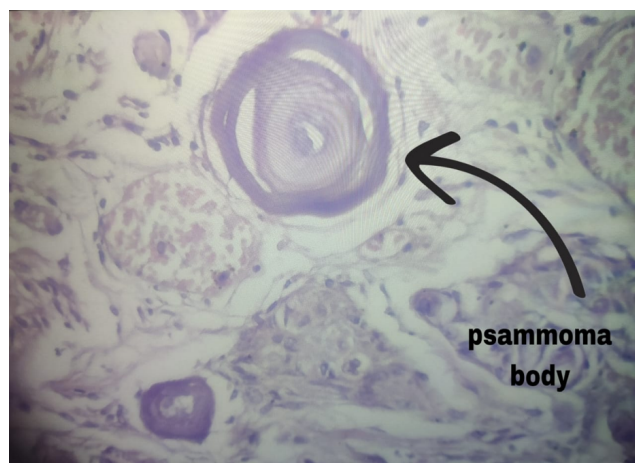


Figure 5: A number of tumor cells, blood vessels, fibrous tissue, and septal plasma bodies, as displayed in Figures 3, 4 and 5. The discussion of the said tumor with the pathology Dept. lead to the diagnosis of this mass as Grade 1 Meningioma

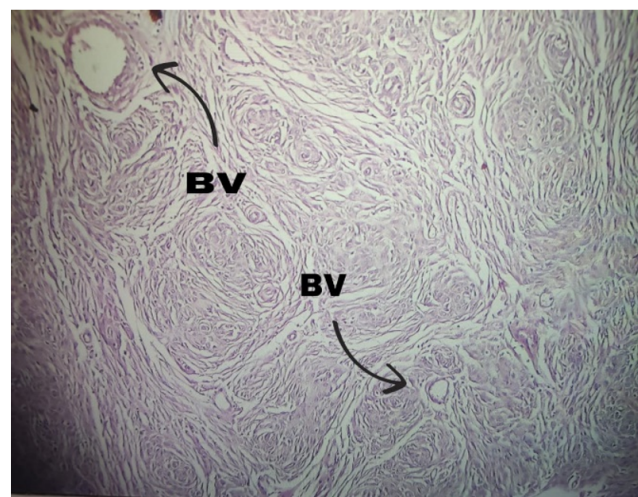


Figure 3: Arrows showing blood vessels

3. Discussion

According to histological structures, WHO has classified meningioma into 3 grades.²

More than 80% of Meningiomas, are of grade I type containing these histological variantions.^{2,8}

1. Meningothelial cells with whorl pattern
2. Fibroblastic cells
3. Psammomatous bodies
4. Angiomatous
5. Microcytic
6. Lymphoplasmacyte features
7. Metaplastic subtypes.

Out of these we have observed Psammoma bodies which are concentric lamellated calcified structures commonly

observed in meningioma grade I as shown in Figure 3.

In Grade 2 following atypical lesion present^{2,3}

1. Necrosis
2. Sheet like growth
3. Prominent nuclei
4. Increased cellularity
5. Increased mitotic activity
6. Atypical, clear and choroid cell subtypes.

In Grade 3 malignant legions are present⁸

1. Sarcomas
2. Carcinomas
3. Melanomas

In Cystic Meningiomas cysts are present within or around tumor in 4-7% of meningioma.⁹

Meningioma en plaque (MEP) is another type of meningioma shows diffuse and extensive involvement of dura mater, usually with extracranial extension into the bones, orbit, dura and the soft tissue. MEP is classified as grade I by WHO.^{10,11} On histopathological study of these hyperostosis in MEP usually contains whorls of Meningothelial cells. Hyperostosis is present in 13 - 49% of MEP cases.^{11,12}

Radiation Induced Meningiomas (RIM) are tumors that develop as a complication from exposure to radiation.

Ossified Meningioma is are tumor characterized by complete ossification or calcification. Ossification differs from these is seen in Psammomatous Meningioma.¹³

We diagnosed the Meningioma as Grade 1 based on, its microscopic study and its site, in the microscopic study Meningothelial cells and whorl patterned psammoma bodies were observed. Hence, it is a Psammomatous type of Grade 1 Meningioma.

4. Conclusion

1. There was a small sized encapsulated tumor on the inferior aspect of the brain no deeper invasion in brain tissue.
2. In the histological study, it showed Meningothelial cells in whorl pattern, blood vessels, fibrous tissue and psammoma bodies, which indicate Grade 1 Meningioma.
3. It was found in aged male cadaver.

5. Source of Funding

None.

6. Conflict of Interest

None.

References

1. Ostrum QT, Cioffi G, Gittleman H, Patil N, Waite K, Kruchko C, et al. CBTRUS Statistical report: Primary Brain and Other Central Nervous System Tumors Diagnosed in the United States in 2012-2016. *Neuro Oncol.* 2019;21(Suppl 5):1–100.
2. Bureki RA, Horbinski CM, Kruser RT, Horowitz PM, James CD, Lukas RV, et al. An overview of meningiomas. *Future Oncol.* 2018;14(21):2161–77.
3. Lim YS, Kim MK, Park BJ, Kim TS, Lim YJ. Long term clinical outcomes of malignant Meningiomas. *Brain Tumor Res Treat.* 2013;1(2):85–90.
4. Wiemels J, Wrensch M, Claus EB. Epidemiology and etiology of Meningioma. *J Neurooncol.* 2010;99(3):307–14.
5. Shao C, Bai LP, Qi ZY, Hui GZ, Wang Z. Overweight, obesity and Meningioma risk: a meta-analysis. *PLoS One.* 2014;9(2):e90167.
6. Connolly ID, Cole T, Veeravagu A, Popat R, Raliff J, Li G. Craniotomy for Resection of Meningioma: An Age-Stratified Analysis of the MarketScan Longitudinal Database. *World Neurosurg.* 2015;84(6).
7. Hortobagyi T, Bencze J, Varkoly G, Koushari MC, Klekner A, Klekner A. Meningioma recurrence. *Open Med (Wars).* 2016;11(1):168–73.
8. Backer-Grondahl T, Moen BH, Torp S. The histopathological spectrum of human meningiomas. *Int J Clin Exp Pathol.* 2012;5(3):231–42.
9. Sotiriadis C, Vo QD, Ciarpaglini R, Hoogewood HM. Cystic meningioma: diagnostic difficulties and utility of MRI in diagnostics and management. *BMJ Case Rep.* 2015;2015:bcr2014208274. doi:10.1136/bcr-2014-208274.
10. Simas NM, Farias JP. Sphenoid Wing en plaque meningiomas: Surgical results and recurrence rates. *Surg Neurol Int.* 2013;4:86.
11. Basu K, Majumdar K, Chatterjee U, Ganguli M, Chatterjee S. En plaque meningioma with angioinvasion. *Indian J Pathol Microbiol.* 2010;53(2):319–21.
12. Baek JU, Cho YD, Yoo JC. An osteolytic meningioma en plaque of the sphenoid ridge. *J Korean Neurosurg Soc.* 2008;43(1):34–6.
13. Murakami T, Tanishima S, Takeda C, Kato S, Nagashima H. Ossified Metaplastic Spinal Meningioma Without Psammomatous Calcification: A Case Report. *Yonago Acta Med.* 2019;62(2):232–5.

Author biography

Shashikala Londhe, Professor

Anjali Gosavi, Professor

Minakshi Kasegaonkar, Associate Professor

Nilesh Bhosle, Associate Professor

Cite this article: Londhe S, Gosavi A, Kasegaonkar M, Bhosle N. Grade I Meningioma in a cadaver – A case report. *Indian J Clin Anat Physiol* 2023;10(4):275-277.