

Content available at: <https://www.ipinnovative.com/open-access-journals>

Indian Journal of Clinical Anatomy and Physiology

Journal homepage: <https://www.ijcap.org/>

## Original Research Article

## Colorimetric variations in cadaveric tissues embalmed with modified Thiel's and Formalin solutions: An objective comparative study using image J

Kalaivani K<sup>1</sup>, Rajasekhar SSSN<sup>1\*</sup><sup>1</sup>Dept. of Anatomy, Jawaharlal Institute of Postgraduate Medical Education and Research, Puducherry, India

## ARTICLE INFO

## Article history:

Received 08-11-2023

Accepted 23-11-2023

Available online 20-01-2024

## Keywords:

Embalming

Formalin

Thiels solution

Tissue colour

Surgical skill training

## ABSTRACT

**Background:** The comparison of tissue colour between Thiel's embalmed cadavers (TEC) and formalin-embalmed cadavers (FEC) is crucial for assessing the efficacy of Thiel embalming technique as a suitable alternative to formalin embalming for surgical skill training and anatomical education. Most of the studies which declare the superiority of tissue colour in TEC over FEC have done subjective assessment and comparison of the tissue colour. This study aims to compare the colour difference between Thiel and formalin embalmed cadavers objectively.

**Materials and Methods:** The current study used six human cadavers to compare the effects of two embalming methods, Modified Thiel's solution (MTS) and Modified Formalin Solution (MFS). The tissues of the cadavers were dissected and photographed to be analysed for Red, Blue, Green values using Image J software.

**Results:** The mean (SD) R-value (Red), G-value (Green), and B-value (Blue) for MTS embalmed cadavers were 149.78 (16.070), 124 (19.675), and 109.96 (9.852), respectively, from pictures of embalmed cadavers from research groups. The mean RGB value of MTS embalmed cadavers was substantially ( $P < 0.05$ ) higher than MFS embalmed cadavers.

**Conclusion:** The current research found that MTS-embalmed cadavers have greater RGB values than MFS-embalmed ones. This information helps to fully understand tissue property changes, evaluate their impact on student perceptions and learning outcomes, and determine Thiel embalming's suitability for surgical training and workshops.

This is an Open Access (OA) journal, and articles are distributed under the terms of the [Creative Commons Attribution-NonCommercial-ShareAlike 4.0 License](https://creativecommons.org/licenses/by/4.0/), which allows others to remix, tweak, and build upon the work non-commercially, as long as appropriate credit is given and the new creations are licensed under the identical terms.

For reprints contact: [reprint@ipinnovative.com](mailto:reprint@ipinnovative.com)

## 1. Introduction

When it comes to surgical and anaesthetic procedures that cannot be practised on real patients, simulators, or animal models, soft-embalmed cadavers are the preferred learning tool. The quality of the tissues is very important when considering using soft embalmed cadavers for surgical skill training (SST). Soft embalmed cadavers are required to be more pliable, easier to manipulate, and appear as natural as possible than formaldehyde-embalmed (FEC) cadavers.<sup>1</sup> Embalming has traditionally involved the use

of formaldehyde, a common fixative. However, the use of formalin as an embalming agent has been found to result in cadavers that do not exhibit the qualities of living organs, including colour.<sup>2</sup> On the other hand, Thiel-embalmed cadavers have been shown to retain tissue colour more effectively compared to FECs.<sup>3</sup> Thiel embalmed cadavers (TECs) have been found to have superior colour retention, flexibility, and overall appearance compared to formalin-fixed specimens.<sup>3</sup> Additionally, TECs have been described as having lifelike tissue colour, consistency, plasticity, and transparency.<sup>1</sup> These findings suggest that there are significant differences in tissue colour between modified TECs and FECs. Most of the studies which declared that

\* Corresponding author.

E-mail address: [sekhar5883@gmail.com](mailto:sekhar5883@gmail.com) (Rajasekhar SSSN).

the tissue colour in MTS embalmed cadavers is superior to FECs are limited to subjective opinion of the surgeons utilising the cadavers for SST. However, there have been no studies that objectively measured the colour difference between MTS and FECs.

A comparison of tissue colour between the cadavers embalmed using different embalming solutions is important. The shift from formalin to Thiel embalming techniques in anatomy departments has raised questions about the changes in tissue properties, including colour.<sup>4</sup> Understanding the differences in tissue colour between these two embalming methods is crucial for planning studies and interpreting findings in the field of anatomy.<sup>4</sup> Furthermore, the use of TECs in the teaching of human anatomy has gained attention, and it is important to assess the impact of embalming methods on student perceptions and learning outcomes.<sup>5</sup>

This implies that colour plays a significant role in determining how realistic the embalming tissues appear. The colour of the embalmed tissues is said to influence realism, teaching and learning, surgical training, and research.<sup>6</sup> Therefore, there is a need to objectively compare the colour difference between the TECs Thiels and the FECs to conclusively establish the superiority of TEC beyond scrutiny. The aim of the present study is to assess the effects of a modified Thiel solution (MTS) and a modified formaldehyde solution (MFS) on the tissue colour by measuring the red, blue, and green (RGB) colour values of human cadaveric tissues.

## 2. Materials and Methods

Six human cadavers were used in the current study which were further divided into two groups (Group A and Group B) containing three cadavers each. Group A was embalmed with MTS, and Group B was embalmed with MFS.<sup>6</sup> After embalming, the bodies in Group A were placed in cold storage at 40 degrees Celsius, while those in Group B were transferred to tanks containing formalin solution. The cadavers in Group A were taken out of cold storage and allowed to thaw for two hours, while the cadavers in Group B were taken out of formalin tanks 14 days after they had been placed there. To ensure that the cadavers in both groups received the same amount of light, they were placed in the same spot in the dissection hall of the anatomy department and lit with artificial light.

The fatty tissue, fascia, and anterior thigh muscles of the cadavers were exposed through dissection of the right lower limb. A three-centimetre-long skin incision was made 4 centimetres below the inguinal ligament, superoinferiorly, in the middle of the anterior thigh. A window was made by reflecting the skin, revealing the underlying fat, fascia, and muscles of the anterior thigh. Dissected areas were photographed less than 5 minutes after being exposed. The lighting and background colour were standardised by

taking the photographs under a constant artificial light source. The software was used to compare the coloration of cadavers preserved using MTS and MFS by analysing the RGB (Red, Green, Blue) values of muscle and adipose tissue in photographs of each cadaver group. The RGB values in the photographs of the various cadavers were determined using ImageJ, an image processing software package, version 1.53t (24 August 2022) (ImageJ: Rasband, W.S., ImageJ, U. S. National Institutes of Health, Bethesda, Maryland, USA, <https://imagej.nih.gov/ij/>, 1997-2018). The RGB values of the photograph were taken from five different spots, including the four corners and the middle. The final RGB value for a given photograph was determined by averaging its five individual values. Normally distributed variables are compared using student's t-test in Microsoft Excel 365. The level of significance considered for this study is 5%,  $\alpha=0.05$ . Figures 1 and 2 depicts the measurement of RGB (red, green and blue) values of muscle and fat tissues using image J analysis of the photographs taken from the dissected front of the thigh in a cadaver embalmed with MFS and MTS, respectively.

## 3. Results

Three cadavers from each group were dissected, for a total of six cadavers, and their photographs were used to determine their respective RGB values (Figures 1 and 2). Among the RGB values extracted from photographs of embalmed cadavers from study groups, the mean (SD) R-value (Red), G-value (Green) and B-value (Blue) for MTS embalmed cadavers were  $149.78 \pm 16.070$ ,  $124 \pm 19.675$ , and  $109.96 \pm 9.852$  respectively. Also, the mean RGB value of MTS embalmed cadavers were significantly ( $P < 0.05$ ) greater than that of MFS embalmed cadavers. The details of the comparison of the RGB values among the study groups are given in Table 1.

## 4. Discussion

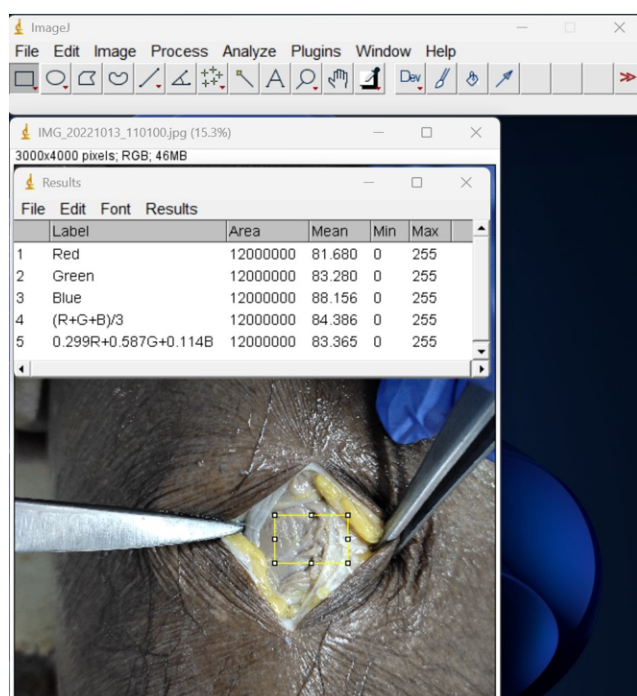
In the present study, RGB values of muscle and fat were determined from photographs of the study groups. The red and green values of the RGB colours captured by photographs of MTS embalmed cadavers were significantly higher than those captured by photographs of MFS embalmed cadavers. Consequently, the quantitative evaluation revealed that the tissue colour of the MTS embalmed cadavers was more realistic, resembling that of living tissues, in comparison to the MFS embalmed cadavers.

According to Jaung et al., the RGB values of pictures of muscle and fat tissue from dead bodies in Graz (Modified Thiels solution) were a lot closer to those of fresh tissue than those from dead bodies in Dodge (Proprietary embalming solution where the components are not revealed by the company) and Genelyn that had been embalmed.<sup>7</sup> The

**Table 1:** Comparison of RGB (Red, green and blue) values of the photographs among the Modified Thiel solution (MTS) and Modified Formaldehyde solution (MFS) groups

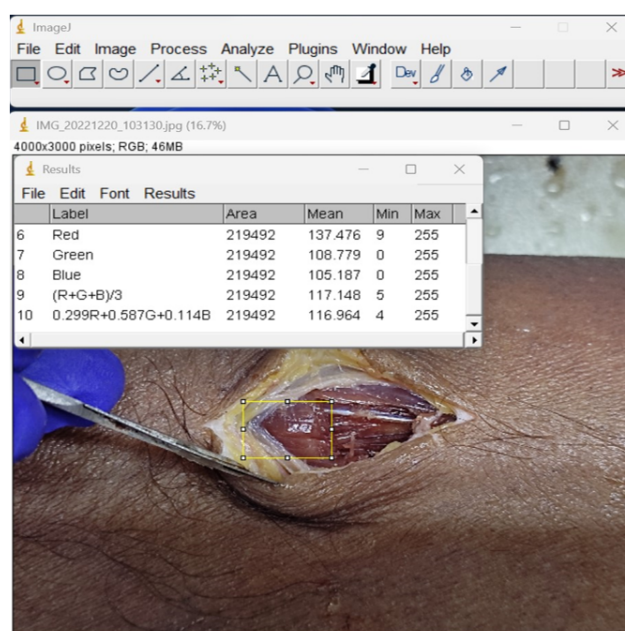
Variable	MTS Mean±SD	MFS Mean±SD	Statistical significance (p value)
R-Value	149.78±16.070	144.82±14.489	P<0.001*
G-Value	124.95±19.675	127.44±9.284	P<0.001*
B-Value	109.96±9.852	98.93±8.770	P<0.05*
RGB Value	128.24±15.199	123.73±5.138	P<0.05*

\* Statistically significant at a 5% level of significance.

**Figure 1:** Measurement of RGB (red, green and blue) values of muscle and fat tissues using image J analysis of the photograph taken from the dissected front of the thigh in a cadaver embalmed with Modified Formalin Solution (MFS)

current study found that MTS embalmed cadavers had significantly higher RGB values of muscle and adipose tissue than MFS embalmed cadavers. The results of the present study compare with those of Jaung et al. Jaung et al. posit that the difference in tissue colour between the study groups may be attributed to the penetrating abilities of the embalming solutions.<sup>7</sup>

Appaji et al. and Hachabizwa et al. reported that the colour of MTS embalmed cadavers was pale and hypopigmented close to the live tissues when compared to the formalin embalmed, which were dark brown in colour.<sup>8,9</sup> The authors speculated that the varying skin tones they observed among their cadavers were due to the chemical peeling of the epidermis induced by Thiel's solution.<sup>8</sup> Consistent with the findings reported by Appaji et al. and Hachabizwa et al., we found that MTS embalmed

**Figure 2:** Measurement of RGB (red, green and blue) values of muscle and fat tissues using image J analysis of the photograph taken from the dissected front of the thigh in a cadaver embalmed with Modified Thiel Solution (MTS)

cadavers had a more natural-looking tissue colour than MFS embalmed cadavers.<sup>8,9</sup> In contrast, Liao et al., proposed that the tissues embalmed with the original Thiel's solution retained their natural colour as opposed to the unfavourable colour of the tissues retained by the MTS.<sup>10</sup> Also, the authors commented that the change in tissue colour could be due to a reduction in strong electrolytes in the MTS compared to the original Thiel solution, which could have affected the MTS's penetration power.<sup>10</sup> However, the majority of present-day practice include the use of MTS rather than the original Thiels solution.<sup>6</sup> The colour of the tissues has a significant impact on their ease of use and drawing similarity to live tissue. Dissection quality and students' understanding of anatomy were found to be significantly enhanced when tissues were preserved in a manner analogous to that of fresh specimens, as reported by Villacorta et al.<sup>11</sup> Tissue colour plays a significant role in the realism and lifelike appearance of cadavers, which

can affect students' comfort levels and engagement during dissection and learning activities.<sup>5,12</sup> Comparing the tissue colour of TECs and FECs can provide insights into the potential benefits and limitations of using Thiel embalming for anatomical education.<sup>5,12</sup> Moreover, the preservation of tissue colour is essential for surgical workshops and training, where the use of cadavers allows for the learning of surgical skills without risk to patients.<sup>7</sup> TECs have been found to exhibit more vivid tissue colour compared to FECs, which can enhance the realism and effectiveness of surgical training.<sup>6,7</sup> Thus, irrespective of the embalming solution employed, it is critical to maintain the cadaver's lifelike tissue colour.

#### 4.1. Comparison of MFS versus MTS as a soft embalming option with respect to tissue colour

Tissue coloration was found to be superior in MTS embalmed cadavers compared to MFS embalmed cadavers in the current study. Bodies that will be used for medical education and research are typically preserved using a formalin embalming solution. However, apart from lifelike tissue colour, MTS has many advantages over the more conventional formalin embalming. Because the cadaver's natural range of motion is preserved through the Thiel embalming method, it can be used for orthopaedic SST.<sup>13</sup> The lower formalin concentration in MTS results in less tissue fixation and more tissue mobility and elasticity.<sup>12,14</sup> MTS is a safer and less toxic alternative to traditional formalin embalming solutions due to its low formalin concentration.<sup>15</sup>

When compared to MTS, MFS may be preferable when conducting SST using radiological images of embalmed cadavers. Balta et al. reported that unlike formalin, which maintains organ and vessel size, Thiel's embalming reduces the size of the cardiovascular system.<sup>16</sup> Formalin embalming, on the other hand, stiffens joints, rendering them unsuitable for SST in orthopaedics.<sup>4</sup> Therefore, there are arguments supporting and opposing the use of MTS as a soft embalming solution. But the selection of a soft embalming solution explicitly depends on the needs of the SST. The present study shows that the MTS is superior to the MFS for preserving lifelike tissue colour.

## 5. Conclusion

The present study assessed the coloration of muscle and adipose tissue in cadavers embalmed using the MTS and MFS methods. The findings of the present study indicate that cadavers preserved with MTS exhibited higher RGB values compared to those preserved with MFS. This information provides valuable insights into comprehensively grasping the alterations occurring in tissue properties, assessing their impact on students' perceptions and learning outcomes, and evaluating the appropriateness

of Thiel embalming for surgical training and workshops.

## 6. Source of Funding

This study received JIPMER intramural funding. No.JIP/Res/Intramural/phs 2/2021-22/No/3., dated : 18/09/2021.

## 7. Conflict of Interest

None.

## 8. Ethical Clearance

No. JIP/IEC2021/131., dated 24/06/2021.

## Acknowledgements


The authors also sincerely thank those who donated their bodies to science so that anatomical research could be performed. Results from such research can potentially increase mankind's overall knowledge that can then improve patient care. Therefore, these donors and their families deserve our highest gratitude.


## References

1. Rajasekhar SSSN, Kumar VD, Raveendranath V, Kalayarasan R, Gnanasekaran S, Pottakkat B. Advanced training in laparoscopic gastrointestinal surgical procedures using genelyn®-embalmed human cadavers: a novel model. *J Minim Access Surg.* 2021;17(4):495–501.
2. Balta JY, Cronin M, Cryan JF, O'Mahony S. Human preservation techniques in anatomy: a 21st century medical education perspective. *Clin Anat.* 2015;28(6):725–34.
3. Hunter A, Eisma R, Lamb C. Thiel embalming fluid-a new way to revive formalin-fixed cadaveric specimens. *Clin Anat.* 2014;27(6):853–5.
4. Eisma R, Lamb C, Soames RW. From formalin to thiel embalming: what changes? one anatomy department's experiences. *Clin Anat.* 2013;26(5):564–71.
5. Balta JY, Lamb C, Soames RW. A pilot study comparing the use of thiel- and formalin-embalmed cadavers in the teaching of human anatomy. *Anat Sci Educ.* 2015;8(1):86–91.
6. Hammer N, Löffler S, Bechmann I, Steinke H, Hädrich C, Feja C. Comparison of modified thiel embalming and ethanol-glycerin fixation in an anatomy environment: potentials and limitations of two complementary techniques. *Anat Sci Educ.* 2014;8(1):74–85.
7. Jaung R, Cook P, Blyth P. A comparison of embalming fluids for use in surgical workshops. *Clin Anat.* 2011;24(2):155–61.
8. Appaji AC. Perception of surgical faculty on the utility of modified Thiel embalmed cadavers. *Int J Anat Radiol Surg.* 2017;6(4):17–22.
9. Hachabizwa C, Banda M, Hainza J, Mutemwa S, Erzingastian K, Kafumukache E. Cadaveric embalming using a modified Thiel method as an alternative to the formalin method. *Anat J Afr.* 2020;9:1797–806.
10. Liao P, Wang Z. Thiel-embalming technique: investigation of possible modification in embalming tissue as evaluation model for radiofrequency ablation. *J Biomed Res.* 2019;33(4):280–8.
11. Villacorta PRF, Hernando H, Abdulla AJA, Barroa JKH. A comparative study of Thiel soft-embalmed and formalin preserved cadavers for anatomy dissection. *Acta Med Phillip.* 2019;53:29–37.
12. Kennel L, Martin DMA, Shaw H, Wilkinson T. Learning anatomy through Thiel- vs. formalin-embalmed cadavers: student perceptions of embalming methods and effect on functional anatomy knowledge. *Anat Sci Educ.* 2018;11(2):166–74.

13. Tsutsumi M, Nimura A, Utsunomiya H, Akita K. Dynamic changes of the joint capsule in relation to the zona orbicularis: an anatomical study with possible implications for hip stability mechanism. *Clin Anat.* 2021;34:1157–64.
14. Miyake S, Suenaga J, Miyazaki R, Sasame J, Akimoto T, Tanaka T. Thiel's embalming method with additional intra-cerebral ventricular formalin injection (TEIF) for cadaver training of head and brain surgery. *Anat Sci Int.* 2020;95:564–70.
15. Morimoto M, Matsuo Y, Ueda G, Kato T, Aoyama Y, Hayashi Y. Exploring the fine-layer structure around a glissonean pedicle in cadaveric models. *SGO.* 2020;25:67.
16. Balta JY, Twomey M, Moloney F, Duggan O, Murphy KP, O'Connor OJ, et al. A comparison of embalming fluids on the structures and properties of tissue in human cadavers. *Anat Histol Embryol.* 2019;48(1):64–73.

### Author biography

**Kalaivani K**, Junior Resident  <https://orcid.org/0000-0002-3711-6643>

**Rajasekhar SSSN**, Additional Professor  <https://orcid.org/0000-0003-4018-8522>

**Cite this article:** Kalaivani K, Rajasekhar SSSN. Colorimetric variations in cadaveric tissues embalmed with modified Thiel's and Formalin solutions: An objective comparative study using image J. *Indian J Clin Anat Physiol* 2023;10(4):210-214.