

Content available at: <https://www.ipinnovative.com/open-access-journals>

Indian Journal of Clinical Anatomy and Physiology

Journal homepage: <https://www.ijcap.org/>

Case Report

A rare variation of omohyoid and its embryological correlations- A case report

Vivek Mishra¹, Prerna Chandra^{1,*}, Shelja Sharma¹

¹Dept. of Anatomy, All India Institute of Medical Sciences, Gorakhpur, Uttar Pradesh, India



ARTICLE INFO

Article history:

Received 06-09-2023

Accepted 22-09-2023

Available online 21-10-2023

Keywords:

Omohyoid muscle

Superior belly

Inferior belly

Radical neck dissection

Anatomical variation

ABSTRACT

The omohyoid muscle is important in radical neck dissection, as it is a landmark for this operation. Because it divides the anterior and posterior cervical triangles into smaller triangles and its particular relationship to the large cervical vessels, the presence of an anatomical variation of the omohyoid muscle is important. Either belly may be absent or double; and the inferior belly may be attached directly to the clavicle and the superior is sometimes fused with sternohyoid. Variations in the omohyoid muscle might be linked to differences in embryological development, which could influence the muscle's final form and function. Anderson (Anderson, 1881) theorized that the superior belly of the omohyoid muscle is a true infrahyoid muscle, whereas the inferior belly most likely shares a common embryology with the subclavius muscle. As omohyoid muscle is used to achieve the reconstruction of the laryngeal muscles and bowed vocal folds, the knowledge of the possible anomalies of the omohyoid muscle is important.

In the present study, we have found a case with two inferior bellies & aberrant course of superior belly of omohyoid on right side of 40 years female cadaver embalmed with formalin during routine dissection at Department of Anatomy AIIMS Gorakhpur.

Omohyoid muscle is closely related to large vessels of neck & brachial plexus, so variations in this muscle are clinically important.

This is an Open Access (OA) journal, and articles are distributed under the terms of the [Creative Commons Attribution-NonCommercial-ShareAlike 4.0 License](https://creativecommons.org/licenses/by-nc-sa/4.0/), which allows others to remix, tweak, and build upon the work non-commercially, as long as appropriate credit is given and the new creations are licensed under the identical terms.

For reprints contact: reprint@ipinnovative.com

1. Introduction

Omohyoid muscle has two bellies which are united by an intermediate tendon. The origin of inferior belly is from the superior border of the scapula, near the scapular notch, and occasionally from the superior transverse scapular ligament. The superior belly arises at the intermediate tendon, and is ends at the inferior border of the body of the hyoid bone. The intermediate tendon of the muscle is attached below to the clavicle and the first rib by a band of deep cervical fascia, which ensheathes the tendon. Either belly may be absent or double; and the inferior belly may be attached directly to the clavicle and the superior is sometimes fused with sternohyoid.¹ The function and embryological origin

of this muscle was first reported by Winslow in 1743, since then it is the subject of debate.² In 1964, Mori classified this muscle into five types based on their origin and insertion.^{3,4} In the radical neck dissection, the omohyoid muscle forms the important landmark for this operation. The presence of an anatomical variation of the omohyoid muscle is important because it divides the anterior and posterior cervical triangles into smaller triangles and also it is related to the large vessels.⁵

2. Case Report

We have found a case with two inferior bellies & aberrant course of superior belly of omohyoid on right side of 40 years female cadaver embalmed with formalin during routine dissection at Department of Anatomy AIIMS

* Corresponding author.

E-mail address: prernachandra307@gmail.com (P. Chandra).

Gorakhpur. During this dissection, we observed two inferior bellies of omohyoid. One inferior belly of omohyoid is arising from superior border of scapula near supra scapular notch then its fibres merges with the sheath surrounding internal jugular vein and other inferior belly is arising from manubrium sternum on the side of suprasternal notch. In this way, the course of Inferior belly was totally aberrant. Superior belly fibres blended with the fibres of sternohyoid unlike normal course of superior belly. On the left side of cadaver, there is no variation of omohyoid. (Figure 1)

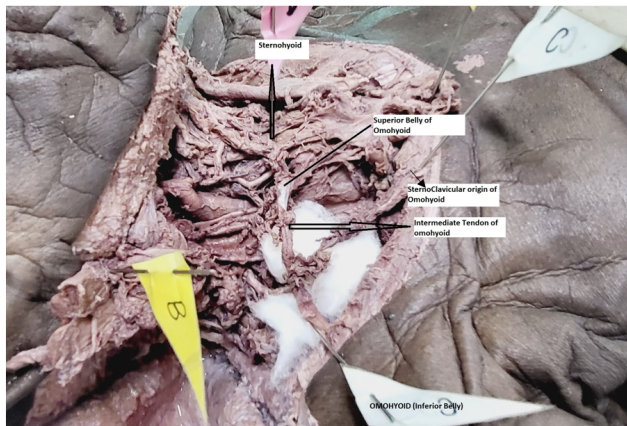


Fig. 1: Variations of omohyoid; inferior belly (white flags) has two origin- scapular & sternoclavicular, both inferior bellies form intermediate tendon from which superior belly (pinned) arises & insert by merging with the fibres of sternohyoid (pink flag), yellow flag - sternocleidomastoid

3. Discussion

For identification of the internal jugular vein (IJV), the omohyoid muscle is the best landmark; thus there are very high chances of the risk of injuring the IJV during surgeries in the lower neck region due to variation of omohyoid.⁶ As intermediate tendon of omohyoid is directly adhere to anterior wall of IJV, when the omohyoid contracts, it affects the lumen of this vessel. The shape of omohyoid muscle often show variation with regards to different insertion points of the superior and inferior bellies, due to common primordium with the sternohyoid.⁷

Anderson theorized that the superior belly of the omohyoid muscle is a true infrahyoid muscle, whereas the inferior belly most likely shares a common embryology with the subclavius muscle.⁸

In the anterior cervical region, the infrahyoid muscles are formed from a muscle primordium. The muscle primordium is first divided into a shallow layer and a deep layer. The shallow layer becomes the splenius muscles & deep layer forms sternothyroid and thyrohyoid. The splenius is separated into the internal and external muscles. The internal muscle becomes the sternohyoid muscle and runs straight into the anterior part of cervical region. The

lower part of the external muscle grows in the external and inferior direction and becomes the omohyoid.⁹ It has been suggested that because the human omohyoid is degenerating, the incidence of anomalies is high.

So in our case, Inferior belly has two bellies. Origin of one inferior belly is normal as arising from scapular notch while other belly is arising from anterior margin of manubrium sternum on each side of suprasternal notch. Embryologically Internal and external muscles of splenius both are giving rise to fibres of omohyoid. Superior belly of omohyoid is embryologically derived from external muscles but in our case, superior belly fibres are blending with fibres of sternohyoid as sternohyoid embryologically develops from internal muscle of splenius. Internal and external muscles of Splenius both are merging together at the insertion of superior belly of omohyoid. In our case superior belly never reaches to hyoid bone.

Currently, infrahyoid muscles are used as myocutaneous flaps for reconstructing surgical defects.¹⁰ When the laryngeal muscles are injured, it is repaired with the use of omohyoid¹¹ and bowed vocal folds can also be corrected with the help of omohyoid.¹²

4. Conclusion

In our case, presence of two inferior bellies of omohyoid might cause confusion if we are not aware of the variations of the muscle. This is also true for surgeons & oncologists. Thus, the knowledge of variations in omohyoid is important for exploration in the anterior cervical region. So reporting of this case is adding literature regarding the variations of this muscle.

5. Source of Funding

None.

6. Conflict of Interest

None.


References

1. Gray H, Williams PL, Bannister LH. Gray's anatomy: The anatomical basis of clinical practice. 41st ed. New York: Churchill Livingstone; 2016.
2. Lehr RP. Musculus levator glandulae thyroideae: an observation. *Anat Anz.* 1979;146(5):494–6.
3. Loukas M, Merbs W, Tubbs RS, Curry B, Jordan R. Levator glandulae thyroideae muscle with three slips. *Anat Sci Int.* 2008;83(4):273–6.
4. Mori M. Statistics on the musculature of the Japanese. *Okajimas Folia Anat Jpn.* 1964;40:195–300.
5. Hatipoğlu ES, Kervancıoğlu P, Tuncer MC. An unusual variation of the omohyoid muscle and review of literature. *Ann Anat.* 2006;188(5):469–72.
6. Kasapoglu F, Dokuzlar U. An Unknown variation of Omohyoid Muscle. *Clin Anat.* 2007;20:964–65.
7. Ziolkowski M, Marek J, Oficjalska-Mlynczak J. The omohyoid muscle during the fetal period in man. *Folia Morphol (Warsz).* 1983;42:21–30.

8. Anderson RJ. The morphology of the omohyoid muscle. *J Med Sci.* 1881;10:1–17.
9. Lewis WH. The development of the muscular system. In: Keibel F, Mall FP, editors. *Manual of Human Embryology.* Philadelphia: Lippincott; 1910. p. 454–522.
10. Wang HS, Shen JW, Ma DB, Wang JD, Tian AL. The infrahyoid myocutaneous flap for reconstruction after resection of head and neck cancer. *Cancer.* 1986;57(3):663–8.
11. Kojima H, Hirano S, Shoji K, Omori K, Honjo I. Omohyoid muscle transposition for the treatment of bowed vocal fold. *Ann Otol Rhinol Laryngol.* 1996;105(7):536–40.
12. Crumley RL. Muscle transfer for laryngeal paralysis. Restoration of inspiratory vocal cord abduction by phrenic-omohyoid transfer. *Arch Otolaryngol Head Neck Surg.* 1991;117(10):1113–7.

Author biography

Vivek Mishra, Additional Professor  <https://orcid.org/0000-0001-7500-2703>

Prerna Chandra, Assistant Professor  <https://orcid.org/0009-0001-9297-9986>

Shelja Sharma, Assistant Professor  <https://orcid.org/0000-0001-7779-7239>

Cite this article: Mishra V, Chandra P, Sharma S. A rare variation of omohyoid and its embryological correlations- A case report. *Indian J Clin Anat Physiol* 2023;10(3):192-194.