

'A Roentgenologic study of epiphyseal union around elbow joints in boys and girls of Bastar Region'

Nandanwar RA^{1,*}, Wahane AM², Dange NS³

¹Assistant Professor, Dept. of Anatomy, ³Associate Professor, Dept. of Biochemistry, Govt. Medical College, Jagdalpur,

²Associate Professor, Dept. of Anatomy, Govt. Medical College, Nagpur

***Corresponding Author:**

Nandanwar RA

Assistant Professor, Dept. of Anatomy, Govt. Medical College, Jagdalpur

Email: rajeshreedng@yahoo.com

Abstract

Age of union of epiphysis is a predominant purpose method of age determination which is an elaborate undertaking for medico legal person. Nevertheless, this age varies with racial, geographic, climatic and quite a lot of other factors. Be trained of quite a lot of textual content books in Anatomy and Radiology displays a obtrusive discrepancy as regards the a long time at which the distinct epiphyses fuse with the respective diaphyses in long bones. These variations have urged want of separate average of ossification for separate regions. This leads us to be taught ages of epiphyseal union around elbow joint, a rarely studied joint. Study was once carried out in total eighty healthful subjects having ages from 13 to 23 years and size of dwelling in Bastar more than 10 years. Chronological age upto the day of examination used to be decided and A-P view of right elbow joint used to be taken in each case. From this radiographs age of union of epiphyses round elbow joint is decided and when compared with the opposite authors from different states of India and in addition with other nations and located to fluctuate substantially.

Keywords: Epiphysis, Elbow joint, Radius, Humerus.

Access this article online	
Quick Response Code:	Website:
	www.innovativepublication.com
	DOI: 10.5958/2394-2126.2016.00050.5

Introduction

Determination of age of an individual is a subject matter of great medico-legal and academic interest. Very frequently doctors are called upon to give an opinion as to the age of a person. It may be for medico-legal purposes, for juvenile court procedures, for entry to the government service or to enable a candidate to sit for university examination etc. The registration of birth is still extremely incomplete in India and many times real age is concealed with various intentions. So it becomes necessary to use some objective method to find out exact age of a particular individual.

The principle means, which enable a medical man to form a fairly accurate opinion about the age of a person, are:- Teeth, height, weight, puberty- changes and ossification of bones etc. Among various methods of age determination, ages of appearance and union of epiphyses with diaphysis, as observed radiological is considered to be a reliable guide and in many cases it is the only guide for anatomists and medico-legal experts for the estimation of age of the individual. The phenomenon of diaphysis-epiphyseal union, particularly in long bones, is to be considered as the most reliable of all the other age indicators of the entire skeleton.

The age of appearance and union of epiphysis is thought to be fairly constant for any particular bone, though real and significant differences in this basic age factor exist. These ages of appearance and union of epiphyses vary with racial, geographic, climatic and various other factors. Study of various text books in Anatomy and Radiology exhibits a glaring discrepancy as regards the ages at which the different epiphyses fuse with the respective diaphysis in long bones. Appreciable variations in the time of fusion of epiphysis with diaphysis have been recorded not only by the workers belonging to different countries^[4,9,10,19,25,26,30] but even by the workers from the various provinces of the Indian subcontinent.^[1,2,5,11,15,17,18,22,23,28,29] Because of the existence of such racial, geographic and climatic variations, need for separate standards of ossification for separate regions have been suggested.^[8,16,21] Ages of epiphyseal fusion have been found to differ in various regions of the same country and this has arisen a need to establish separate standards for separate regions even in the same country. Such standards have been investigated in many states of India e.g. Punjab, Uttar Pradesh, South India, Madhya Pradesh, Gujarat, Bengal etc. but no such standards are present for Bastar region. This compels to study the problem in Bastar. Study also has been carried out to ascertain the commonly accepted view as to the earlier maturity of Indian as compared to Western countries.

Most of the workers have studied hand-wrist radiographs as this is the exposed part of body and there is no need to undress the subject for x-rays. But some workers^[20,31] have shown that choice of area affects skeletal age assessment and also the descriptions of

population based on distribution of skeletal ages from only one part of skeletal may be misleading.

It is a proven fact that sexual dimorphism is present for the time of epiphyseal fusion. In females, epiphyseal fusion is earlier than males though the difference is of 1-2 years only.^[2,12,13,14,19,22,24,29] This necessitates separate standards for males and females.

Thus, the present work is undertaken to investigate the ages of epiphyseal union around elbow radio logically in boys and girls of Bastar region.

Aims and Objectives

The titled 'A Roentgenologic study of epiphyseal union around elbow joint in boys and girls of Bastar Region' was carried out keeping in mind following aims and objectives.

1. To determine ages of epiphyseal union around elbow joints in Bastar region.
2. To compare the ages of epiphyseal union in Bastar region with those reported from other regions in India.
3. To compare the ages of epiphyseal union in Bastar region with those reported from other countries.
4. To study sexual dimorphism in ages of epiphyseal union.

Material and Method

The present study was carried out in the Department of Anatomy, Government Medical College and Hospital, Jagdalpur.

Study was performed in total 80 subjects having ages from 13 to 23 years. The subjects in present study were medical students from Government Medical College, Jagdalpur and the nearby schools. The length of residence of each subject in Bastar region was ascertained and those having less than 10 years stay in the Bastar region were excluded from the present investigation. All the subjects belonged to middle socio-economic status. Freedom from musculo-skeletal, nutritional and endocrine disorders and also from any debilitating ailments in childhood was taken into account. Height, weight and general physical development were recorded in all cases and the menstrual history of girls was also accounted for. Dietetic history was also taken for all subjects.

Out of total 80 students examined, there were 36 boys and 44 girls. Accurate age, as far as possible, was determined in each case based on the statements of the subjects, supported by their school leaving certificates. The subjects were divided into ten groups as 13-14, 14-15, 15-16, 16-17, 17-18, 18-19, 19-20, 20-21, 21-22, and 22-23 years according to their ages. The distribution of boys and girls in each age group is shown in **Table 1**.

All these subjects were examined clinically and radiologically. Antero-posterior views of right elbow were taken in each case. Findings were entered in the proforma.

Ossification of bones: Human bones are mostly preformed in hyaline cartilage called intra- cartilaginous or endochondral ossification; some condense in mesenchyme called intramembranous or mesenchymal ossification. Thus, a soft tissue model appears first and is gradually changed into bone by onset of osteogenesis, often at a centre from which it spreads, until the whole skeletal element is transformed. This centre is called ossification centre.

Such ossification centres appear over a long period, many in embryonic life, some in prenatal life and other well into the postnatal growing period. Accordingly, they are classified as primary centre and secondary centre. Primary centres of ossification are those, which appear before birth, usually during 8th week of intrauterine life. Secondary centres appear after birth with few exceptions.

Many bones ossify from a single centre e.g. carpals, tarsals, lacrimal, nasal bones. However, most of the bones ossify from several centres. Primary centre appears at the centre of future bone; from here ossification progresses towards the ends, which are cartilaginous at birth, although characteristic in shape and articular congruence. These terminal regions ossify from secondary centres. Thus, in long bones, part ossifying from primary centre is called diaphysis and part ossifying from secondary centre is called epiphysis. As the epiphysis enlarges almost all the cartilage is replaced by bone, except for a specialized layer of hyaline cartilage that persists at the joint surface and a thicker zone between diaphysis and epiphysis called epiphyseal plate. Persistence of this epiphyseal plate allows increase in bone length until the usual dimensions are reached and then this epiphyseal plate undergoes ossification. Coalescence of the epiphysis and diaphysis is the union of epiphysis with diaphysis.

The union was considered as complete when space between diaphysis (shaft) and epiphysis was fully obliterated and bony in architecture and density, indistinguishable from the epiphysis and diaphysis in its neighbour- hood. Periosteum between the epiphysis and diaphysis should be in continuity without any notching at the periphery of epiphyseal line. Cases of recent union, where a white transverse line was still seen in place of the epiphyseal cartilage, was also taken as complete union and the so called epiphyseal scar was disregarded. The youngest age group showing complete union in 100% subjects was taken as criteria for generalization.

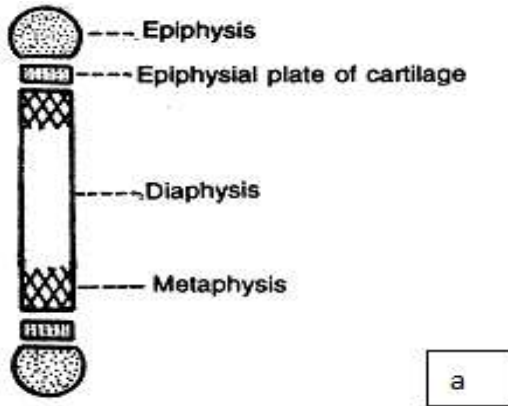


Fig. a: Showing parts of long bone before fusion of epiphysis and diaphysis

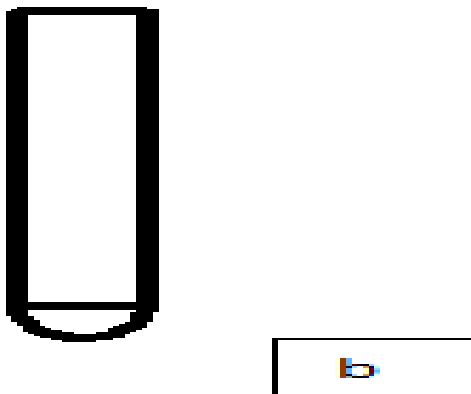


Fig. b: Complete fusion of epiphysis with diaphysis

Observation

Study includes total 80 subjects consisting 36 boys and 44 girls having ages from 13 to 23 years.

In all the subjects, correct age was determined as far as possible and they were subjected to radiological examination. Antero-posterior views of right elbow joint were taken and epiphyseal fusion around this joint was studied. Earliest age group showing complete epiphyseal union in all 100% subjects was taken as the age of union of that particular epiphysis. Data is tabulated and statistically analysed under following heads and subheads-

- i. **Distribution of no. of subjects and their percentage according to age and sex (Table 1).**
- ii. **Ages of union of epiphyses around elbow joint in males and females.**
 - A. Age of union of the composite epiphysis of lower end of humerus with shaft (Table 2).
 - B. Age of union of the medial epicondyle of humerus with shaft (Table 3).
 - C. Age of union of the upper end of radius with shaft (Table 4).
- iii. **Ages of union of various epiphyses for males and females found in present study (Table 5).**

Table 1: Showing Distribution of no. of subjects and their percentage according to age and sex

Age (in years)	No. of cases		Total	%	p-value
	Boys	Girls			
13-14	0	3	3	3.75	8.5 Non-Significant
14-15	0	3	3	3.75	
15-16	5	5	10	12.5	
16-17	4	5	9	11.25	
17-18	5	4	9	11.25	
18-19	5	6	11	13.75	
19-20	5	4	9	11.25	
20-21	4	5	9	11.25	
21-22	4	5	9	11.25	
22-23	4	4	8	10	
Total	36	44	80	100%	

Table 1: Shows distribution of no. of subjects and their percentage according to age and sex and there is no significant difference in distribution of no. of subjects in different age groups.

Table 2: Showing age of union of the composite epiphysis of lower end of humerus with shaft

Age group (Years)	Number of cases examined		Number of cases showing complete union		%	
	Boys	Girls	Boys	Girls	Boys	Girls
13-14	0	3	-	1	-	33.33
14-15	0	3	-	3	-	100
15-16	5	5	2	5	40	100
16-17	4	5	4	5	100	100
17-18	5	4	5	4	100	100
18-19	5	6	5	6	100	100
19-20	5	4	5	4	100	100
20-21	4	5	4	5	100	100
21-22	4	5	4	5	100	100
22-23	4	4	4	4	100	100

Table 2: Shows youngest age group showing complete union of this epiphysis in 100% subjects is 16 to 17 years in case of males and 14 to 15 years in case of females.

Bar diagram showing degree of union of composite epiphysis of lower end of humerus with shaft in various age-groups among boys and girls

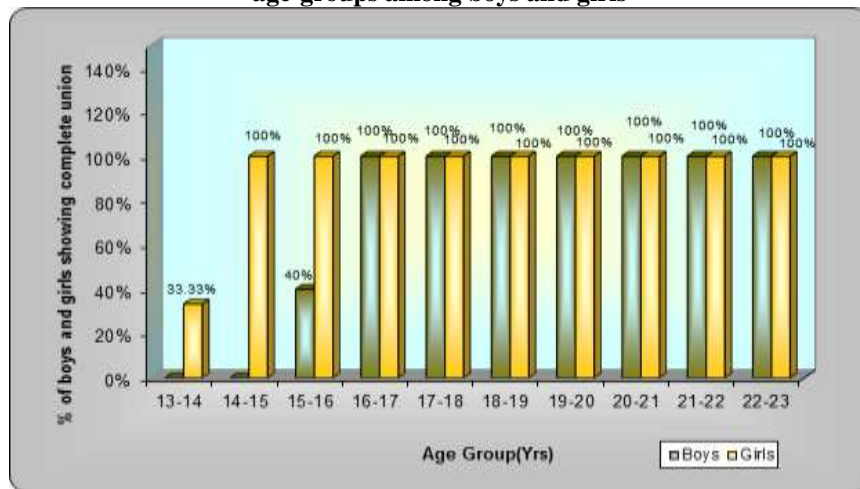


Table 3: Showing age of union of the medial epicondyle of humerus with shaft

Age group (Years)	Number of cases examined		Number of cases showing complete union		%	
	Boys	Girls	Boys	Girls	Boys	Girls
13-14	0	3	-	1	-	33.33
14-15	0	3	-	2	-	66.66
15-16	5	5	2	5	40	100
16-17	4	5	2	5	50	100
17-18	5	4	5	4	100	100
18-19	5	6	5	6	100	100
19-20	5	4	5	4	100	100
20-21	5	5	5	5	100	100
21-22	4	5	4	5	100	100
22-23	4	4	4	4	100	100

Table 3: In case of medial epicondyle of humerus, earliest age showing complete union in 100% cases is 17 to 18 years for males and 15 to 16 years for females.

Bar diagram showing degree of union of medial epicondyle of humerus with shaft in various age-groups among boys and girls

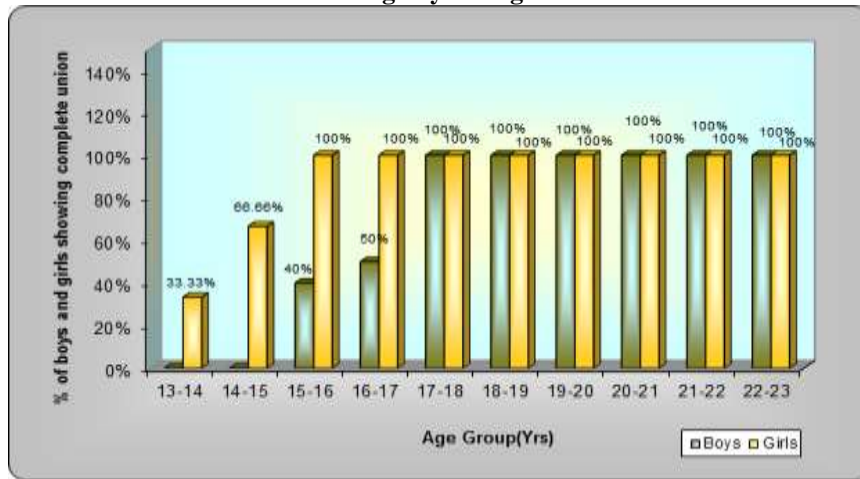


Table 4: Showing age of union of the upper end of radius with shaft

Age group (Years)	Number of cases examined		Number of cases showing complete union		%	
	Boys	Girls	Boys	Girls	Boys	Girls
13-14	0	3	-	2	-	66.66
14-15	0	3	-	3	-	100
15-16	5	5	2	5	40	100
16-17	4	5	2	5	50	100
17-18	5	4	5	4	100	100
18-19	5	6	5	6	100	100
19-20	5	4	5	4	100	100
20-21	4	5	4	5	100	100
21-22	4	5	4	5	100	100
22-23	4	4	4	4	100	100

Table 4: Earliest age group showing complete union of upper end of radius in 100% subjects is 17 to 18 years for males and 14 to 15 years for females.

Bar diagram showing degree of union upper end of radius with shaft in various age-groups among boys and girls

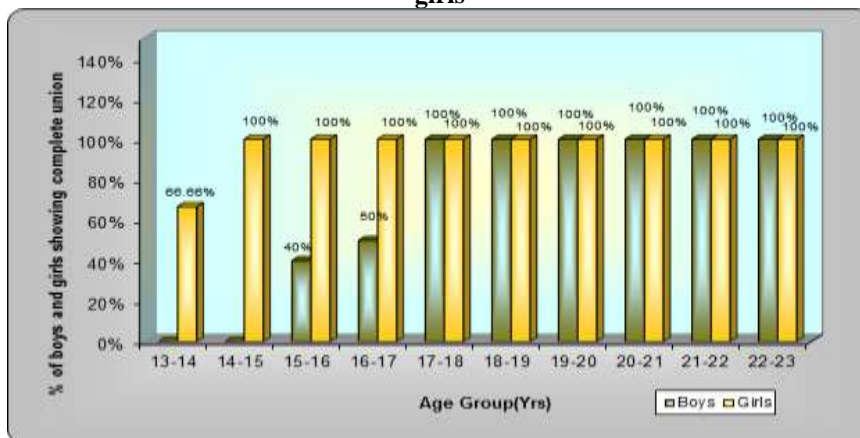


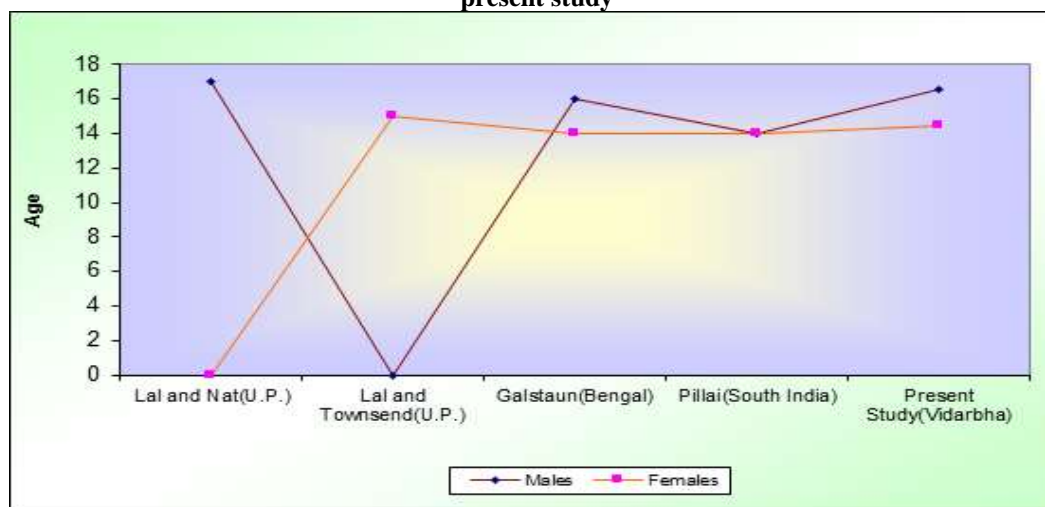
Table 5: Showing the ages of epiphyseal union in boys and girls for various epiphyses in present study

Epiphysis	Age of union (years)	
	Boys	Girls
Composite epiphysis of lower end of humerus	16-17	14-15
Medial epicondyle of humerus	17-18	15-16
Upper end of radius	17-18	14-15

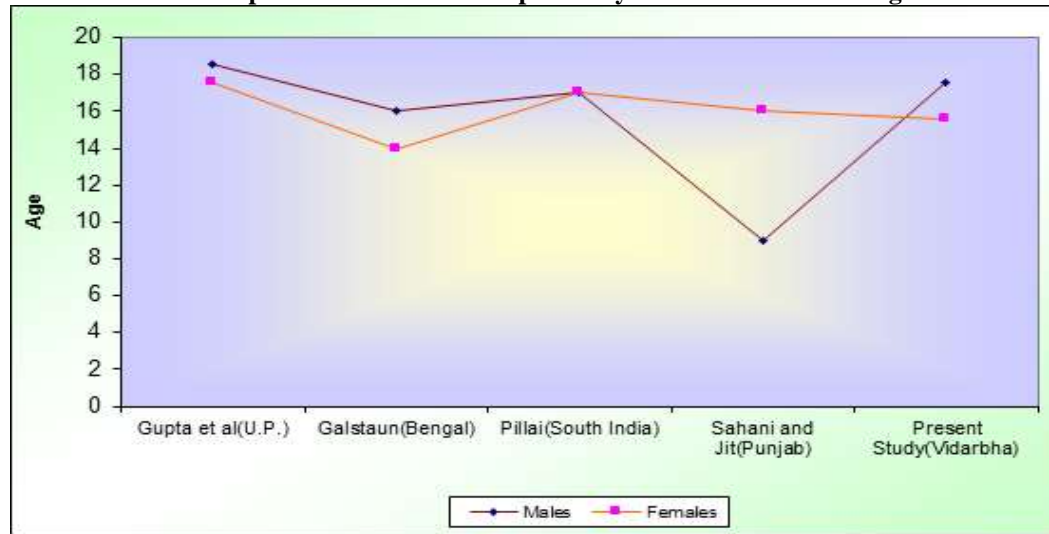
Table 5: As described previously, the youngest age group showing complete union of an epiphysis in 100% subject is taken as the age of union of that particular epiphysis. Using this criterion, above table summaries ages of union of various epiphyses in present study. In case of all epiphyses union is found to be earlier in girls than boys by about 1 to 3 years.

Table 6: Showing comparison of ages (years) of union of epiphyses around Elbow joint given by various workers in India with findings of present study

Authors	Cases Examined				Composite Epiphyses of humerus			Medial Epicondyle			Upper end of Radius		
	Sex	Number	Total	Age-group (years)	Male	Female	Mixed	Male	Female	Mixed	Male	Female	Mixed
Lal and Nat (1934) (U.P.)	Male	52		15-20	17 yrs	-	-	-	-	-	17 yrs	-	-
Lal and Townsend (1939) (U.P.)	Female	125		10-18	-	15 yrs	-	-	-	-	-	16 yrs	-
Gupta et al (1974) (U.P.)	Male Female	44 31	75	16-23	-	-	-	18-19 yrs	17-18 yrs	-	16-17 yrs (Inconclusive)	17-18 yrs (Inconclusive)	-
Galstaun (1937) (Bengal)	Male Female	472 235	707	0-19	16 yrs	14 yrs	-	16 yrs	14 yrs	-	16-17 yrs	14-15 yrs	-
Basu and Basu (1938) (Bengal)	Female	116		7-19	-	13-14 yrs	-	-	-	-	-	13-14 yrs	-
M.J.S. Pillai (1936) (South India)	Not Mentioned	100		10-23	-	-	14 yrs	-	-	17 yrs	-	-	17 yrs
Sahni and Jit (1995) (Punjab)	Female	149		11-19	-	-	-	-	16 yrs	-	-	16 yrs	-
Present Study (2014) (Baster)	Male Female	36 44	80	13-23	16-17 yrs	14-15 yrs	-	17-18 yrs	15-16 yrs	-	17-18 yrs	15-16 yrs	-

Graph A: Diagram showing ages of union of composite epiphysis of lower end of humerus reported by workers from other regions of India in comparison with present study

Graph B: Diagram showing ages of union of medial epicondyle of humerus reported by workers from other regions of India in comparison with present study



Graph C: Diagram showing ages of union of upper end of radius reported by workers from other regions of India in comparison with present study

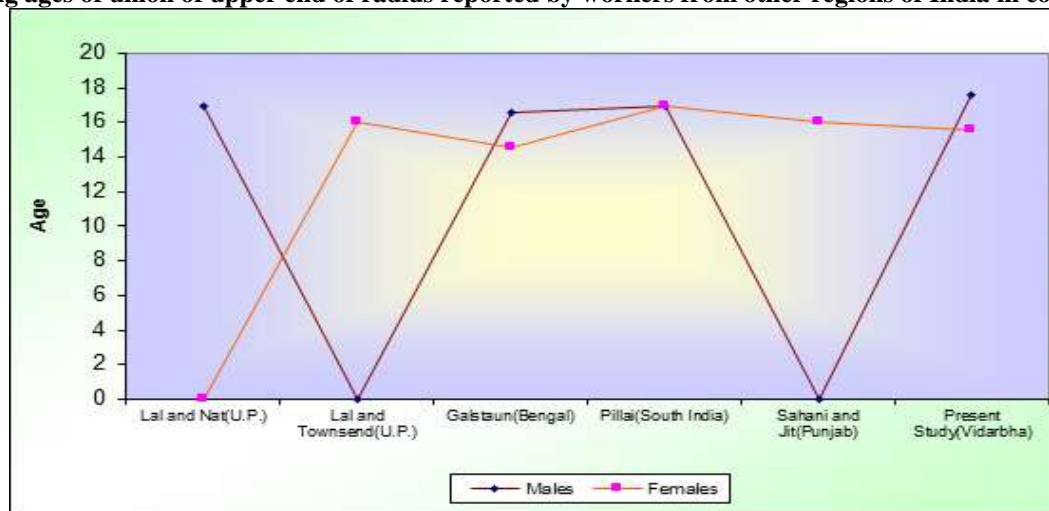
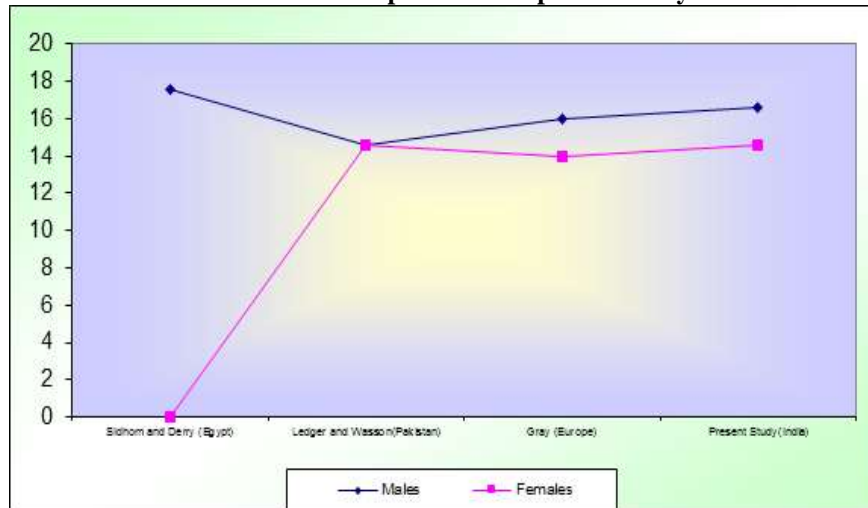


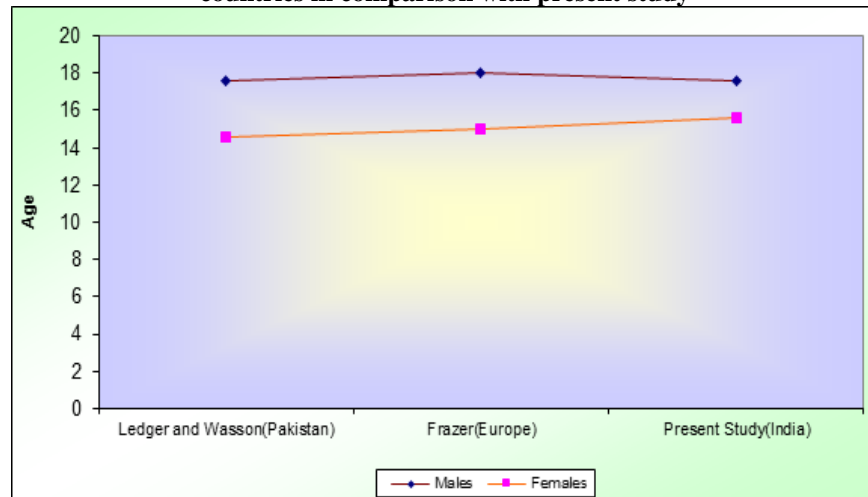
Table 7: Showing comparison of ages (years) of union of epiphyses around Elbow joint given by various workers from other countries with findings of present study

Authors	Cases Examined				Composite Epiphysis of lower end of humerus			Medial Epicondyle			Upper end of Radius		
	Sex	Number	Total	Age group (years)	Male	Female	Mixed	Male	Female	Mixed	Male	Female	Mixed
Sidhom and Derry (1931) (Egyptian)	Male	400		14-20	17-18 yrs	-	-	-	-	-	17 – 18 yrs	-	-
Ledger and Wasson (1941) (Pakistan)	Male Female	189 49	238	13-20	14-15 yrs	14 – 15 yrs	-	17 – 18 yrs	14 – 15 yrs	-	17 – 18 yrs	14 – 15 yrs	-
Frazer (1958) (European)	-	-		-	17 yrs	14 yrs	-	18 yrs	15 yrs	-	16 – 17 yrs	14 – 15 yrs	-
Gray (1995) (European)	-	-		-	16 yrs	14 yrs	-	-	-	20yrs	17 yrs	14 yrs	-
Present study (2014) (Baster-India)	Male Female	36 44	80	13-23	16-17 yrs	14 – 15 yrs	-	17 – 18 yrs	15 – 16 yrs	-	17 – 18 yrs	14 – 15 yrs	-

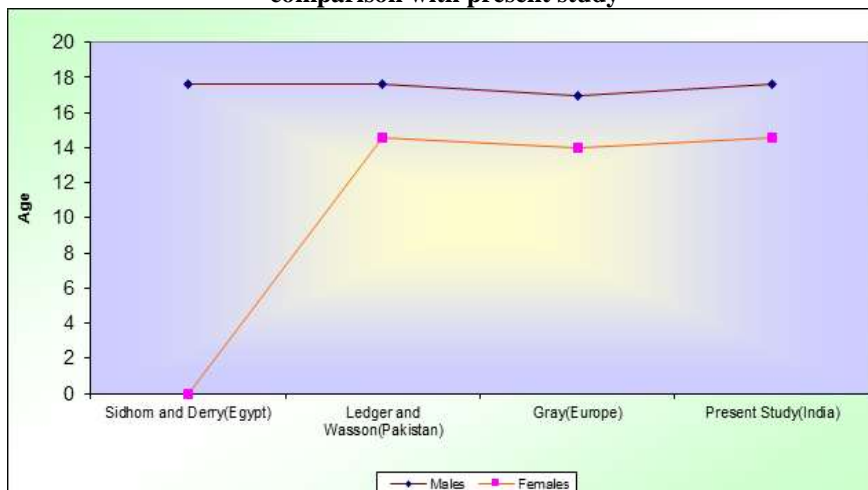
Graph D: Diagram showing ages of union of medial epicondyle of humerus reported by workers from other countries in comparison with present study



Graph E: Diagram showing ages of union of medial epicondyle of humerus reported by workers from other countries in comparison with present study



Graph F: Diagram showing ages of union of upper end of radius reported by workers from other countries in comparison with present study



Discussion

From the observations, various points are discussed under following heads-

- i. Comparison of ages of union of various epiphyses as given by various workers from other regions of India with the findings of present study.
- ii. Comparison of the ages of union of various epiphyses as given by various workers from other countries with the findings of present study.
- iii. Sexual differences in the ages of epiphyseal union.

I. Comparison of ages of union of various epiphyses as given by workers from other regions of India with the findings of present study.

As stated previously, there are appreciable variations in the time of union of epiphyses with the diaphysis in various regions of India. These variations are also reflected in present study.

- a. Comparison of ages of epiphyseal union around elbow joint found in present study with those reported by workers from other regions of India. (Table 6, Graph A, B, C.)

- i. **Composite epiphysis of lower end of humerus:** In present study, the age of fusion of composite epiphysis of lower end of humerus is found to be 16-17 years in males and 14-15 years in females.

According to Lal and Nat^[17] this age for males in Uttar Pradesh is 17 years and according to Lal and Townsend^[18], the same age for girls in Uttar Pradesh is 15 years. These figures given by Galstaun^[11] for Bengalis are 16 years for males and 14 years for females. For Bengali girls, this age is also given by Basu and Basu^[6] as 13-14 years. Pillai^[23] studied the time of fusion of this epiphyses in South Indians and it is found to be 14 years.

Above analysis shows that the age of union of composite epiphysis of lower end of humerus in Bastar region is almost similar or about 1 year earlier than that in Uttar Pradesh but the union of this epiphysis takes place later in Bastar than Bengal and South India.

- ii. **Medial epicondyle of humerus:** In present study, the age of union of medial epicondyle of humerus is found to be 17-18 years for males and 15-16 years for females.

According to Galstaun^[11], this age for Bengali boys is 16 years and that for Bengali girls is 14 years, whereas this age given by Pillai^[23] for South Indians is 17 years. Gupta et al^[12] recorded this age

In subjects of Uttar Pradesh as 18-19 years for boys and 17-18 years for girls. Sahni and Jit^[27] have studied the age of union of this epiphysis for Punjabi females and it is found to be 16 years.

It is found that, the time of union of medial epicondyle found in the present study is later than Bengal and South India but earlier than Punjab and Uttar Pradesh.

- iii. **Upper end of Radius:** In present study, the age of union of upper end of radius with its shaft is

observed to be 17-18 years in boys and 15-16 years in girls.

Lal and Nat^[17] reported this age among males in U.P. as 17 years and Lal and Townsend^[18] found this age for girls in Uttar Pradesh as 16 years. Results of the study of Gupta et al^[12] in Uttar Pradesh were inconclusive as they haven't studied boys under 16 years and girls under 17 years. Galstaun^[11] has given the same age for subjects in Bengal and it is 16-17 years for males and 14-15 years for females whereas this age given by Basu and Basu^[6] for Bengali females is 13-14 years. The time of union of this epiphysis recorded by Pillai^[23] in his study on South Indians is 17 years. According to Sahni and Jit^[27], this age for Punjabi females is 16 years.

From above analysis, the age of union of upper end of radius found in Bastar is almost similar to that in Uttar Pradesh and Punjab but it is later than that in Bengal and the age for South Indians is lower than the present study in case of boys but higher than the present study in case of girls.

II. Comparison of the findings in the present study with those of the workers from other countries.

It is generally accepted that epiphyseal union takes place later in the western races than in the eastern races. But findings during present investigation create considerable doubt in one's mind regarding this widely accepted opinion.

- a. Comparison of ages of epiphyseal union around elbow joint found in the present study with those reported by various workers from other countries.

(Table 7, Graph D, E, F)

- i. **Composite epiphysis of lower end of humerus:** In present study, age of union of this epiphysis is found to be 16-17 years for boys and 14-15 years for girls.

For Europeans, age of union of composite epiphysis of lower end of humerus is given by Frazer^[7] and Gray^[3] and in case of both the authors; findings are almost similar to that found in the present study. Sidhom and Derry^[30] has given this age for Egyptian boys as 17-18 years, which is 1 year later than the present study. Ledger and Wasson^[19] has reported this age for subjects in Pakistan which matches with the age for girls found in the present study but lower than the present study in case of boys.

- ii. **Medial Epicondyle:** In present study, age of union of medial epicondyle is observed to be 17-18 years and 15-16 years for boys and girls respectively.

In this case, age given by Frazer^[7] for Europeans is 18 years in case of boys and 15 years in case of girls almost similar to the findings of the present study but that given by Gray^[3] is 20 years, later than the present study. The findings of Ledger and Wasson^[19] for Pakistani subjects also correspond with the present study.

- iii. **Upper end of radius:** The age of union of this epiphysis found during the present study is 17-18 years and 14-15 years for boys and girls respectively.

In case of upper end of radius, the age of union reported by Frazer^[7] for Europeans is 16-17 years for males and 14-15 years for females which is same as that of the present study in case of girls but lower in case of boys. This age given by Gray^[3] for Europeans matches with the present study. This age reported by Sidhom and Derry^[30] for Egyptian boys and by Ledger and Wasson^[19] for Pakistanis is also similar to that found in the present study.

III. Sexual differences in the ages of epiphyseal Union: The ages of union of various epiphyses for males and females found in the present study are shown in table 5

Ever since Pryor^[26] demonstrated earlier ossification in females, it has been universally accepted and the present work is no exception to this. In almost all cases union is found to be earlier in females by about 1 to 3 years than males. It matches with the findings of most of the workers- Ledger and Wasson^[19], Loomba S.D.^[22], Hassan and Narayan^[14], Bajaj et al^[2], Sharat et al^[29], Gupta et al^[12], Hagg U and Taranger^[13], Molinary Gasser-Largo^[24].

Summary and Conclusions

The present study was carried out in the Department of Anatomy, Government Medical College and Hospital, Jagdalpur.

This study was designed to determine ages of epiphyseal union around elbow and wrist joints in Bastar region and to compare these ages with those reported from other regions of India and also from other countries. The study also aimed at determining sexual dimorphism in ages of epiphyseal union.

In all, 80 students (36 males and 44 females) having length of residence in Bastar more than 10 years have been studied. Their ages varied from 13 to 23 years. Right elbow and wrist have been examined radiologically in all of them. The observation have been tabulated and analysed. Youngest age group showing complete union of an epiphysis in all 100% subjects was taken as the age of union of that epiphysis.

1. In Bastar, the composite epiphysis of lower end humerus fused with the metaphysis between 16 to 17 years in males and between 14 to 15 years in females.
2. Medial epicondyle of humerus united at the age of 17 to 18 years in males and 15 to 16 years in females.
3. Upper end of radius fused with the shaft between 17 to 18 years in males and 14 to 15 years in females.
4. In case of most of the epiphyses, union was found to be later in Bastar than Bengal and South India.
5. Overall comparison with other provinces in India showed that the ages of epiphyseal union varies even in the different provinces of the same country.
6. At present no secure evidence is available to support the commonly accepted view that epiphyseal fusion is earlier in the eastern races than in the western.

7. Again, the ages of epiphyseal union are found to vary greatly all over the world indicating the need for separate standards of ages of epiphyseal union for separate regions.
8. Epiphyseal union found to be earlier in females than males.

Bibliography

1. Agrawal M.L. and Pathak I.C. Roentgenologic study of epiphyseal union in Punjabi girls for determination of age. Indian J. med. Res. 45:283-289,1957.
2. Bajaj I.D et. al. Appearance and fusion of important ossification centres: A study in Delhi population, Ind. J. Med. Res. 55:1064-1067,1967.
3. Bannister L.H. Editor, of Gray's Anatomy Descriptive and applied 38th Ed.: Page no. 626,636, 639,669,684,697,711, 1995.
4. Barrett J.H. The union of certain epiphyses in a mixed female population in Rangoon. J. Anat. 70: 432-434,1936.
5. Basu S.K. and Basu S. The age-order of epiphyseal union in Bengalee girls (a preliminary study). J. Indian M.A. 7:571-578,1938 a.
6. Basu S.K. and Basu S. A contribution to the study of diaphyseoepiphyseal relations at the elbow of young Bengalee girls. Ind. Jour. Paediat. 5:201-204,1938 b.
7. Breathnach A.S. Editor, of Frazer's Anatomy of human 5th ed. London: J.A. Churchill Ltd: page no. 77,87,118,127,142,1958.
8. Crowder C. and Austin D. Age ranges of epiphyseal fusion in the distal tibia and fibula of contemporary males and females. J. Forensic Sci 50(5):1001-1007,2005.
9. Davies D.A. and Parsons P.G. Age order of appearance and union of the normal epiphyses as seen by X-rays. J. Anat 62:58-71,1927.
10. Flecker H. Time of appearance and fusion of ossification centers as observed by Roentgenographic methods. Am. J. Roentg. 47:97-159,1942.
11. Galstaun G. A study of ossification as observed in Indian subjects. Indians J. Med. Res.25:267-324,1937.
12. Gupta et. al. A roentgenologic study of epiphyseal union around elbow, wrist and knee joints and pelvis in Boys and Girls of Uttar Pradesh. J. Indian M.A. 62:10-12,1974.
13. Hagg U. and Taranger J. Skeletal stages of the hand and wrist as indicators of the pubertal growth spurt. Acta odontol scand. 38(3):187-200,1980.
14. Hasan M. and Narayan D. Radiological study of the postnatal ossification of the upper end of humerus in U.P. Indians. J. Anat. Soc. India. 13:70-74,1964.
15. Hepworth S.M. On the determination of age in Indians from a study of the ossification of the epiphyses of the long bones. Ind. Med. Gaz. March: 128-131,1929.
16. Koc A. et al. Assessment of bone ages: is the Greulich-Pyle method sufficient for Turkish boys? Pediatr. Int 43(6):662-665,2001.
17. Lal R. and Nat B.S. Ages of epiphyseal union at the elbow and wrist joints amongst Indians. Indian J. Med. Res. 21:683-689,1934.
18. Lal R. and Townsend R.S. Ages of epiphyseal union at the elbow and wrist joints amongst Indian Girls. Indian Med. Gaz. Oct.:614-615,1939.
19. Ledger L.K. and Wasson T.C. Ages of epiphyseal union at the elbow and wrist joints amongst 238 children in North - West frontier province. Ind. Med. Gaz. 76:81-84,1941.
20. Leite H.R., O'Reilly M.T. and Close J.M. Skeletal age assessment using the first, second and third fingers of the hand. Am. J. Orthod Dentofacial orthop. 92(6):492-498,1987.

21. Loder R.T. et. al. Applicability of the Greulich and Pyle skeletal age standards to black and white children of today. *Am. J Dis. Child* 147(12):1329-1333,1993.
22. Loobma S.D. Age of epiphyseal union at the wrist joint in Uttar Pradesh. *J. Indian M.A.* 30:389-395,1958.
23. M. J.S. Pillai. The study of epiphyseal union for determining the age of South Indians. *Indian J. Med. Res.* 23:1015-1017,1936.
24. Molinari L., Gasser T, and Largo R.H. TW3 bone age: RUS\CB and gender differences of percentiles for score and score increments. *Ann. Hum. Biol* 31(4):421-435,2004.
25. Paterson R.S. Radiological investigation of the epiphyses of the long bones. *J. Anat* 64:28-46,1929.
26. Pryor J.W. Differences in the time of development of the centres of ossification in the male and female skeleton. *Anat. Rec.* 25:252-273,1923.
27. Sahni D. and Jit I. Time of fusion of epiphyses at the elbow and wrist joints in girls of northwest India. *Forensic Sci Int.* 74(1-2):47-55,1995.
28. Saksena J.S. and Vyas S.K. Epiphyseal union at the wrist, knee and iliac crest in Residents of Madhya Pradesh. *J. Indian M.A.* 53:67-68, 1969.
29. Sharat S et. al. Skeletal growth in school children. *Ind. Paediatric* 7:98-108,1970.
30. Sidhom G. and Derry D.E. Dates of union of some epiphyses in Egyptian from X-ray photographs. *J. Anat* 65:196-211,1931.
31. Xi H. J. and Roche A.F. Differences between the hand-wrist and the knee in assigned skeletal ages. *American. J. Phys. Anthropol* 83(1):95-102,1990.