

Sex determination from hard palate measurements using palatine index with reference to its clinical implications

Meera Jacob^{1,*}, Bindhu S.², Ramakrishna Avadhani³

¹Assistant Professor, ²Associate Professor, ³Professor & HOD, Yenepoya Medical College

***Corresponding Author:**

Meera Jacob

Assistant Professor, Yenepoya Medical College

Email: meera_jacob83@yahoo.co.in

Abstract

Objective: To determine the sexual dimorphism of hard palate and to classify hard palate using palatine index.

Method: Present study was conducted in 90 dry skulls of South Indian region. Sex of the skull was determined and various measurements were taken and compared to determine sexual dimorphism. The parameters measured were maximum length of hard palate, maximum width of hard palate and palatine index was calculated.

Results: The average values of maximum length of palate for male and female cases were 3.98 ± 0.44 and 3.72 ± 0.54 cms respectively. The average value of maximum palatal width was 3.53 ± 0.40 cms in males and 3.23 ± 0.45 cms in females. The maximum palatal length and width were higher in males when compared to females (p value < 0.001). The average value of palatal index was 90.3 ± 18.46 in males and 89.7 ± 21.15 in females respectively. P value > 0.05 and it was statistically insignificant. Majority of male skulls had brachystaphyline type of palate (54.17%) whereas in females 40.48% belonged to leptostaphyline and 40.48% to brachystaphyline type.

Conclusion: The study shows that the maximum palatal length and width is higher in males than females in the south Indian population. According to palatine index, Majority of the hard palates belonged to the category of brachystaphyline type in the south Indian region which correlated with other studies conducted in the same population.

Key words: Sexual dimorphism, Hard palate, South India

| Access this article online | |
|---|--|
| Quick Response Code: | Website: www.innovativepublication.com |
|  | DOI: 10.5958/2394-2126.2016.00043.8 |

Introduction

Hard palate forms the roof of the mouth and floor of nasal cavity. It is made up of palatine process of maxilla and horizontal plates of palatine bones. These process meet at the cruciform suture made of intermaxillary, interpalatine and palatomaxillary sutures¹. The mucoperiosteum of hard palate is made of palatine glands, median raphe and transverse palatine folds greater palatine foramen is located close to the lateral border of hard palate medial to the third molar tooth and from it a vascular groove runs forwards. This foramen transmits greater palatine nerves and vessels. The posterior border of hard palate is free and presents a midline projection directed backwards called posterior nasal spine which gives attachment to musculus uvulae on each side². Estimation of sexual dimorphism is a vital determinant for identification of an individual because the skeletal features vary with gender³ Hard palate plays an important role in articulation of speech and therefore any osteological or morphological variations in the bony palate is of great clinical

significance and it will also help in the administration of local anaesthesia and also in palatal surgeries. This study will also help in deriving normal range of palatine index which will act as a baseline for studies of certain oral developmental abnormalities. High and narrow palate have been associated with Apert syndrome, Turners syndrome, Franceschetti-Teacher Collins syndrome, Trisomy 21 syndrome and others. Considering above all, aim of the present study was to determine the palatal length and breadth to stabilise the data for south Indian population. Morphological classification of hard palate was determined by calculating the palatine index and sexual dimorphism in measurements were also noted. Clinically the measurement of hard palate is important for transnasal and transoral approaches for endoscopic anterior skull base surgeries. Due to superior visualisation of the endoscopes and rapidly advancing robotic surgical procedures led skull base surgeries to use minimally invasive techniques to treat complex pathologies. So there is a need for precise geometric understanding of bony limits for transoral and transnasal approaches^{4,5,6}.

Materials and Methods

Present study was undertaken in the Department of Anatomy, Yenepoya Medical College, Mangalore. The study comprised of 90 dry, adult human skulls of either sex. The skulls with sphenoccipital junction synostosed were taken for the study. The skulls that are deformed and juvenile skulls were excluded from the

study. Dry skulls included for the study was first examined for sex determination using various traits. Following parameters were measured in cms by using vernier callipers

1. **Palatine length:** Maximum length of hard palate was measured from the anterior margin of incisive fossa to the posterior nasal spine.(Fig. 1)

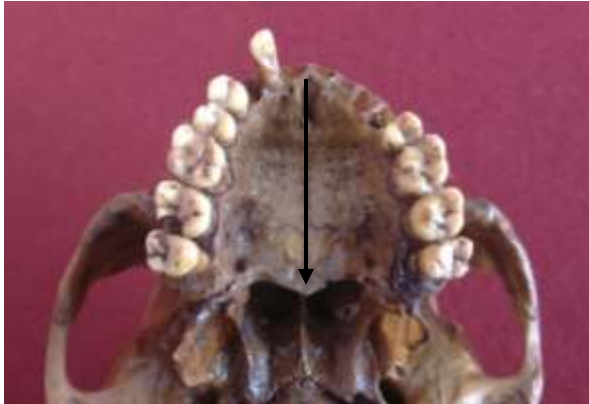


Fig. 1: Shows the length of the hard palate is taken from anterior margin of incisive fosse to the posterior nasal spine

2. **Palatine breadth:** Maximum breadth was calculated from the outer border of maxillary second molar teeth.(Fig. 2)
3. **Palatine index was calculated by using the formula:** Maximum palatine breadth /Maximum palatine length x 100

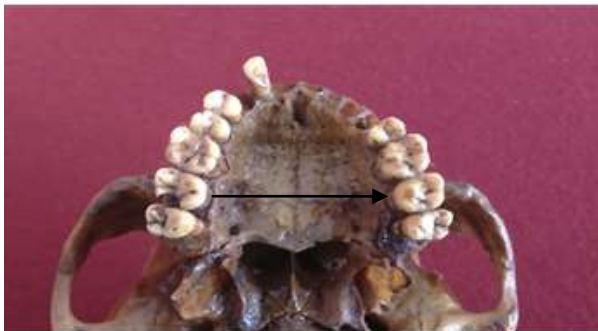

Fig. 2: Shows the maximum width of the hard palate is taken at the gingival margin of second molar tooth

Each reading was repeated twice by the same observer to avoid any manual error. The data obtained was statistically analysed.

Results

Out of 90 skulls studied 48 were of males and 42 skulls were of females. The range of palatal length in males were 2.52 to 4.73 cms and for females it was 2.20 to 4.81 cms. The average of maximum palatal length is presented in Table 1. The average value for male cases and female cases were 3.98 ± 0.44 cms and 3.72 ± 0.54 cms respectively.

Table 1: Mean palatal length

| Sex | N | Mean | SD | Minimum | Maximum |
|--------|----|------|------|---------|---------|
| Male | 48 | 3.98 | 0.44 | 2.52 | 4.73 |
| Female | 42 | 3.72 | 0.54 | 2.20 | 4.81 |

P value <0.001 and is statistically significant

The range of palatal width in males were 2.81 to 4.51 cms and for females it was 2.22 to 4.51 cms. The average of maximum palatal length is presented in Table 2. The average value for male cases and female cases were 3.53 ± 0.40 cms and 3.23 ± 0.45 cms respectively.

Table 2: Mean palatal width

| Sex | N | Mean | SD | Min | Max |
|--------|----|------|------|------|------|
| Male | 48 | 3.53 | 0.40 | 2.81 | 4.51 |
| Female | 42 | 3.23 | 0.45 | 2.22 | 4.51 |

P value <0.001 and is statistically significant

Table 3: Mean palatine index

| Sex | N | Mean | S.D | SEM |
|--------|----|------|-------|------|
| Male | 48 | 90.3 | 18.46 | 2.66 |
| Female | 42 | 89.7 | 21.15 | 3.26 |

P value >0.05 and is not statistically significant

The average palatine index calculated is presented in Table 3. The average values in males and females were $90.3(\pm 18.46)$ and $89.7(\pm 21.15)$ respectively. There was no significant statistical difference found in the palatine index of males and females. As per palatine index, the hard palate can be classified as Leptostaphyline means narrow palate having palatine index less than 80%, Mesostaphyline were palatine index is between 80-85% and brachystaphyline means wide palate with palatine index above 85%. Table 3 shows the frequency of palatine index in different types of palate.

Table 3: Palatine Index frequency in different types of palate

| Type | Range | Total Sample (90) | | Male skull (48) | | Female skull (42) | |
|------------------|--------|-------------------|-------|-----------------|-------|-------------------|-------|
| | | N | % | N | % | N | % |
| Leptostaphyline | <80% | 30 | 33.33 | 13 | 27.08 | 17 | 40.48 |
| Mesostaphyline | 80-85% | 17 | 18.89 | 09 | 18.75 | 08 | 19.04 |
| Brachystaphyline | >85% | 43 | | 26 | 54.17 | 17 | 40.48 |

From the above Table, it is seen that majority of male skulls had brachystaphyline type of palate (54.17%) whereas in females 40.48% belonged to leptostaphyline and 40.48% to brachystaphyline type.

Discussion

Studies on hard palate is an important tool in anthropology, fabricating maxillary dentures for edentulous patients and it is also very useful in better assessment of bony anatomy in patients with palatal inadequacy. Values of mean palatal length and breadth were 3.98 and 3.53 cms in males and 3.72 cms and 3.23 cms in females. According to Gray's Anatomy, the mean palatal width mentioned is 50mm which is higher than the observations of the present study⁷. Robert S. Redman, Burton L, Sharpio studied the palatal measurements in various age groups from Minnesota. It was observed that there was significant difference between male and female cases⁸.

Hassanali J et al studied 125 hard palates of African dry skulls and found that 43.2% of total skulls belonged to leptostaphyline group, 23.7% mesostaphyline (intermediate) and 33.1% brachystaphyline palates(wide palate)⁹. In the present study according to palatine index 47.78% skulls belonged to brachystaphyline type, 18.89% mesostaphyline and 33.3% leptostaphyline palates. These findings correlated with another study conducted by D'Souza et al, where brachystaphyline was more common than leptostaphyline¹⁰. Woo in 1949 studied hard palates of 2,214 skulls in different racial groups and note that palatine index of males is smaller than that of females. It was suggested that mean palatine indices increase in order that the percentages of anterior direction of palatine sutures decrease¹¹. Skulls of American Indian series were not included in the study. Larnach and Macintosh in their studies in Coastal New South Wales found that mean palatine index was more in males when compared to female skulls¹². These findings were similar to the findings of the present study where mean palatine index was more in males when compared to females. From the above studies it is shown that palatine index can be considered as a tool for sex determination which should be necessarily preceded by determination of race.

Conclusion

The knowledge of the morphological variations in the hard palate is very helpful in maxillofacial surgeries and also in repair of cleft palate. These data is also

helpful in determination of sex when fragmentary remains are available for forensic identification. By calculating the palatine index we can compare the skull of various regions and different races.

References

1. Chaurasia BD. Osteology of the Head and Neck. In: Human Anatomy Regional and Applied Volume 3. 4th ed. New Delhi: CBS Publishers & Distributors. 2008: 12-13.
2. Datta A.K. Essentials of Human Anatomy. Head and Neck 5th Edition, Current books international 2009:33.
3. Trotter M and Gleser GC (1958). A re-evaluation of estimation based on measurements of stature taken during life and of long bones after death. American Journal of Physical Anthropology 16 79-123.
4. Kennedy D W. Technical innovations and the evolution of endoscopic sinus surgery. Ann Otol Rhinol Laryngol Suppl. 2006;196:3-12.
5. Xia T, Baird C, Jallo G, et al. An integrated system for planning, navigation and robotic assistance for skull base surgery. Int J Med Robot. 2008;4:321-330.
6. Pillai P, Baig M N, Karas C S, Ammirati M. Endoscopic image-guided transoral approach to the craniovertebral junction: an anatomic study comparing surgical exposure and surgical freedom obtained with the endoscope and the operating microscope. Neurosurgery. 2009;64(5) 02:437-442.
7. Standring S., Gray's Anatomy- Anatomical basis of clinical practice, 39th ed. 2005, p. 459.
8. Robert S. Sandman, Burton L. Shapiro and Robert J. Gorlin. 'Measurement of Normal and Reportedly malformed Palatal Vaults. II Normal Juvenile measurements' J. dent. Res. March- April 1966 Vol. 45- No.-2 pages 267-269.
9. Hassanali J. and Mwaniki D. Palatal analysis and osteology of the hard palate of the Kenyan African skulls. Anat Rec 1984; 209(2):273-80.
10. D'Souza AS, Mamatha H, Jyothi N. 2012.Morphometric analysis of hard palate in South Indian skulls. Biomed Res 23:173-75.
11. Woo JK. Direction and type of transverse palatine suture and its relation to the form of hard palate. American Journal of Physical Anthropology 1949;7(NS):385-399.
12. Laranch SL and Macintosh NWG (1966). The craniology of the aborigines of Coastal New South Wales. The Oceania Monographs 13;72-73.