

Content available at: <https://www.ipinnovative.com/open-access-journals>

Indian Journal of Clinical Anatomy and Physiology

Journal homepage: <https://www.ijcap.org/>

Case Report

The costocoracoid ligament: A case report

Rajvardhan Sisodia¹, Ameet Julka², Prisha Rishi², Aprajita Awasthi^{2,*}

¹Mahatma Gandhi Memorial Medical College, Indore, Madhya Pradesh, India

²Dept. of Anatomy, Mahatma Gandhi Memorial Medical College, Indore, Madhya Pradesh, India



ARTICLE INFO

Article history:

Received 08-02-2022

Accepted 09-02-2022

Available online 19-04-2023

Keywords:

Clavipectoral fascia

Thoracic outlet syndrome

Superior thoracic aperture

Subclavian

Brachial plexus

ABSTRACT

During routine dissection of a human cadaver, the costocoracoid ligament was observed as a thick, fibrous band extending from the ventral surface of the costal cartilage of the 1st rib to the coracoid process. It is part of the clavipectoral fascia and lies close to the costoclavicular space of the superior thoracic aperture, consequently affecting structures passing through it like the subclavian vessels and the brachial plexus. Abnormalities in the costocoracoid ligament may therefore result in clinical conditions, surgical complications and/or cosmetic deformities.

This is one of the few papers describing the anatomy of the costocoracoid ligament in a cadaver, and aims to provide a better understanding of the topic. A better understanding of the anatomy and practical significance of the costocoracoid ligament could aid in better understanding of the anatomy of the surrounding region and improve the course of healthcare for relevant cases.

This is an Open Access (OA) journal, and articles are distributed under the terms of the [Creative Commons Attribution-NonCommercial-ShareAlike 4.0 License](https://creativecommons.org/licenses/by-nc-sa/4.0/), which allows others to remix, tweak, and build upon the work non-commercially, as long as appropriate credit is given and the new creations are licensed under the identical terms.

For reprints contact: reprint@ipinnovative.com

1. Introduction

The costocoracoid ligament is a relatively understudied structure of the pectoral region that finds few mentions during routine cadaveric dissection and also in published literature.

The clavipectoral fascia is also known as the coracoclavicular or costocoracoid fascia.¹ Between the first rib and coracoid process, the fascia often thickens to form a band, the costocoracoid ligament.²

Previously only one case report of unilateral costocoracoid ligament in a cadaver has been reported.³

2. Case Report

The presence of the costocoracoid ligament (hereby referred to as the CCL) on the right side was noted in the pectoral region during routine dissection on a male cadaver aged 94

years (Figure 1), by first year medical students of Mahatma Gandhi Memorial Medical College, Indore (M.P.), India.

The pectoral region was carefully dissected to remove the skin and superficial fascia following which the sternal and clavicular fibres of the Pectoralis major were cut and reflected. This exposed the underlying clavipectoral fascia and Pectoralis minor muscle. After careful blunt dissection, our attention was drawn towards a thick fibrous band extending from the upper surface of the first rib to the coracoid process and lying inferior to the Subclavius muscle. Although not clearly distinguishable from the surrounding tissue on the basis of colour, what set it apart was its toughness and unyielding nature when subjected to pressure and pull by forceps.

The CCL was consequently preserved by continuing further dissection around it to identify its relation with other vital structures in the region. Henceforth, the subclavian artery and subclavian vein were dissected out deep to the CCL along with the medial and lateral cords of the brachial

* Corresponding author.

E-mail address: aprajitaawasthi@gmail.com (A. Awasthi).

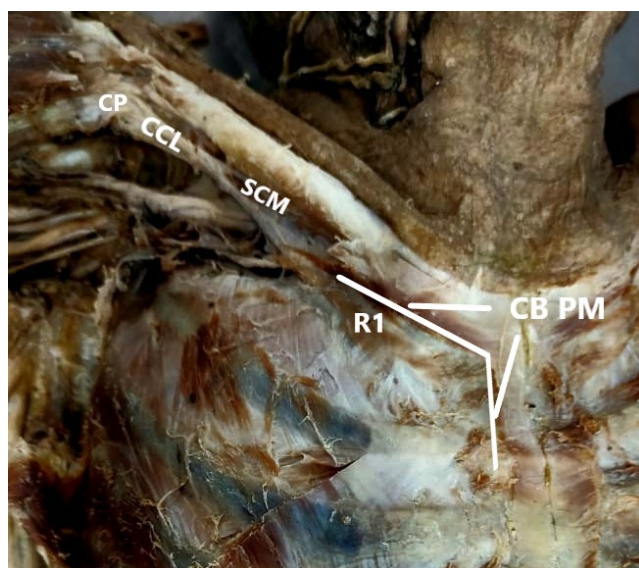


Fig. 1: Costocoracoid ligament anatomy

plexus on their way to the axilla (Figure 2).

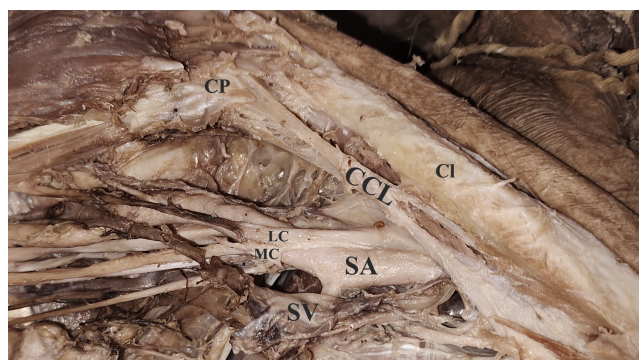


Fig. 2: Costocoracoid ligament relations

A significant stretching of the CCL was observed upon the abduction of the cadaver's arm.

However, no such band was observed in the left pectoral region where the clavipectoral fascia exhibited its usual soft connective tissue character and consistency.

3. Discussion

The clavipectoral fascia is a strong fascial sheet deep to the Pectoralis major occupying the interval between the clavicle and Pectoralis minor.⁴ Its upper part, namely the costocoracoid membrane, is attached to the coracoid process of scapula laterally while blending with the external intercostal membrane of the upper two spaces medially.⁵ Extending between the Subclavius and Pectoralis minor, the costocoracoid membrane is pierced by the lateral pectoral nerve.⁶

The clavipectoral fascia splits around Subclavius and is attached to the clavicle both anterior and posterior to the groove for subclavius.^{2,5} The posterior layer of the fascia blends with the axillary sheath and extends upwards to anchor the inferior belly of Omohyoid to the clavicle.⁴

Below, the fascia splits to enclose the Pectoralis minor and after re-uniting at its lower border, it extends downwards as the suspensory ligament of axilla, which blends with summit of the axillary fascia.⁴ The suspensory ligament of axilla pulls up the axillary fascia and the overlying skin upwards during abduction of the arm forming the axillary fossa.⁶

Laterally, while attaching to the coracoid process, the clavipectoral fascia blends with the coracoclavicular ligament.⁴

Gray states that the part of the clavipectoral fascia lying between the first rib and coracoid process is often a thickened band called the costocoracoid ligament below which the clavipectoral fascia is thin.² Datta, Last and Hollinshead state that the CCL extends from the knuckle of coracoid process to the first costochondral junction.^{1,4,5}

Chandrika G Teli et al. reported a case of right-sided costocoracoid ligament in a cadaver extending from the first costal cartilage to the acromion process of scapula.³

Genetically, the CCL has been reported to be congenitally short in a group of related individuals in whom a pedigree analysis suggests an autosomal dominant mode of inheritance.⁷ Although there was no hindrance in carrying out daily activities, the major cause of concern was a cosmetic deformity with excessively round and sloping shoulders along with a loss of anterior clavicular contour. There was also limitation in rotation and retraction of scapula.

The thoracic outlet encompasses the space extending from supraclavicular fossa upto the axilla. The pathophysiology of symptoms helps to categorize thoracic outlet syndrome (TOS) into neurogenic thoracic outlet syndrome (nTOS), venous thoracic outlet syndrome (vTOS) and arterial thoracic outlet syndrome (aTOS), depending on the compression of brachial plexus nerves, subclavian artery and vein, and axillary artery and vein in interscalene triangle, costococlavicular space and subcoracoid space.⁸

The presence of these structures deep to the CCL on their way to the axilla may warrant an array of investigative procedures to delineate it as a probable causative factor in the symptomatology of TOS.

McCleery syndrome is defined as intermittent obstruction of the subclavian vein without thrombosis, which mostly occurs due to compression of the vein between the Subclavius tendon and anterior Scalene muscle which is worsened by arm abduction.⁹

The CCL may represent the expression of an atavistic trait as suggested in a study by Cantu and Ruiz.^{7,10}

4. Conclusion

Although a rare entity, the costocoracoid ligament may unassumingly attain much significance when it becomes the corner stone for certain clinical presentations associated with cosmetic manifestations.

A more in-depth study of the morphology and variations of the CCL will expand our horizon and assist in refining our diagnostic aids and surgical decisions.

A paucity of literature results in a lack of awareness about the CCL, making it more likely to overlook its presence during academic dissections, thereby further propagating a lack of appropriate cognizance for this structure in a cycle. Hence, a concerted effort and a watchful eye for detail during dissection of the pectoral region may go a long way in alleviating certain functional disabilities that arise due to decreased range of mobility of the pectoral girdle due to the presence of the CCL and its variations.

5. Source of Funding

This research did not receive any specific grant from funding agencies in the public, commercial, or not-for-profit sectors.


6. Conflict of Interest

None.

References

- Hollinshead WH. Anatomy for Surgeons: The Back and Limb. vol. 3. New York: Hoeber Medical; 1968. p. 281–2.
- Standring S. Pectoral girdle, shoulder region and axilla. In: Gray's anatomy: The Anatomical Basis of Clinical Practice. United Kingdom: Churchill Livingstone; 2008. p. 791.
- Teli CG, Vanitha, Kadlimatti HS, Kate N. Right Sided Costocoracoid Ligament- A Case Report. *Int J Anat Radiol Surg.* 2015;4(4):39–40.
- Datta AK. Pectoral Region. In: Essentials of Human Anatomy. West Bengal, India: Current Books International; 2012. p. 42.
- Sinnatamby CS. Last's Anatomy: Regional and Applied; Upper Limb. 12th ed. United Kingdom: Churchill Livingstone; 2013. p. 39.
- Moore KL, Dalley AF, Agur AMR. Clinically Oriented Anatomy; Upper Limb. 7th ed. United States: Lippincott Williams & Wilkins; 2014. p. 688.
- Bamforth JS, Bell MH, Hall JG, Salter RB. Congenital shortness of the costocoracoid ligament. *Am J Med Genet.* 1989;33(4):444–6.
- Jones MR, Prabhakar A, Viswanath O, Urits I, Green JB, Kendrick JB, et al. Thoracic Outlet Syndrome: A Comprehensive Review of Pathophysiology. *Pain Ther.* 2019;8(1):5–18.
- McCleery RS, Kesterson JE, Kirtley JA, Love RB. Subclavius and anterior scalene muscle compression as a cause of intermittent obstruction of the subclavian vein. *Ann Surg.* 1951;133(5):588–602.
- Cantu JM, Ruiz C. On atavisms and atavistic genes. *Ann Genet.* 1985;28(3):141–2.

Author biography

Rajvardhan Sisodia, 1st Year MBBS Student  <https://orcid.org/0000-0002-9473-3218>

Ameet Julka, Professor and HOD

Prisha Rishi, PG Student, 3rd Year

Aprajita Awasthi, Assistant Professor

Cite this article: Sisodia R, Ameet Julka, Rishi P, Awasthi A. The costocoracoid ligament: A case report. *Indian J Clin Anat Physiol* 2023;10(1):58-60.