

Content available at: <https://www.ipinnovative.com/open-access-journals>

Indian Journal of Clinical Anatomy and Physiology

Journal homepage: <https://www.ijcap.org/>

## Case Report

# Accessory iliolumbar artery- A case report

Sankaranarayanan G<sup>1</sup>, Rajasekhar SSSN<sup>2,\*</sup>, Kalaivani K<sup>2</sup>

<sup>1</sup>Saveetha Medical College, Chennai, Tamil Nadu, India

<sup>2</sup>Dept. of Anatomy, Jawaharlal Institute of Postgraduate Medical Education and Research Institute (JIPMER), Puducherry, India



### ARTICLE INFO

#### Article history:

Received 25-03-2023

Accepted 13-04-2023

Available online 19-04-2023

#### Keywords:

Arterial variation

Cadaver

Iliolumbar artery

Internal iliac artery

### ABSTRACT

The variant anatomy of pelvic vasculature is reported in fewer studies, especially the internal iliac artery branching pattern. Branches of the internal iliac artery are more critical when considering procedures such as iliac bone grafting, surgical approach to fix pelvic fractures or iatrogenic vascular haemorrhages in the pelvis. The present case shows the variation in the right ileal system, i.e. the accessory iliolumbar artery (ILA), in addition to the principal ILA on the right side, which supplies the iliac and lumbar region.

This is an Open Access (OA) journal, and articles are distributed under the terms of the [Creative Commons Attribution-NonCommercial-ShareAlike 4.0 License](https://creativecommons.org/licenses/by-nc-sa/4.0/), which allows others to remix, tweak, and build upon the work non-commercially, as long as appropriate credit is given and the new creations are licensed under the identical terms.

For reprints contact: [reprint@ipinnovative.com](mailto:reprint@ipinnovative.com)

## 1. Introduction

The iliolumbar artery (ILA) is the first of the three branches sprouting from the posterior division (PD) of the internal iliac artery (IIA). After its origin, it takes an oblique course anterior to the sacroiliac joint (SIJ), crossing the lumbosacral trunk (LST) and obturator nerve (ON). Upon reaching the medial border of the psoas major, it gets divided into ileal and lumbar arteries. The iliac artery supplies the iliacus muscle and participates in gluteal anastomoses.<sup>1,2</sup> The lumbar branch travels between the first sacral and fifth lumbar vertebrae. It then passes through the vertebral canal to supply the spinal nerves.<sup>1</sup> The presence of an additional ILA other than the principal ILA which arises from the posterior division of IIA or trunk of IIA or obturator artery or common iliac artery is said to be the accessory ILA.<sup>3,4</sup> As the ILA and its branches are closely related to the iliac fossa and lumbar vertebra, it is one of the vessels prone to get injured in cases of pelvic trauma and during spinal surgeries.<sup>4</sup>

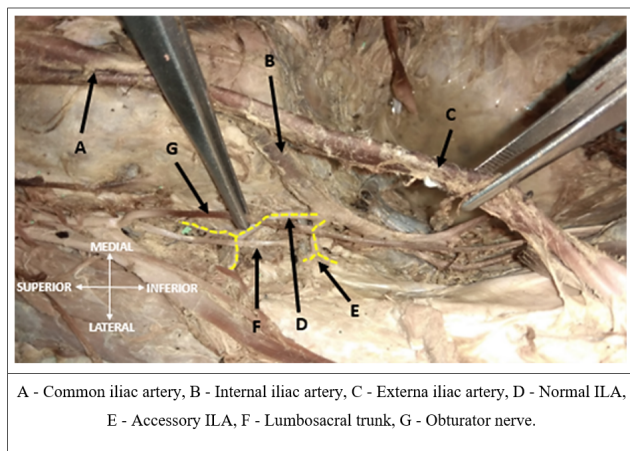
On the other hand, this anatomical disposition quantifies it to be commonly used as a feeding pedicle while taking bone flaps.<sup>4</sup> Even though the ILA arise from its stipulated parent vessel (IIA) in the majority of the cases, variations tend to occur in terms of origin and in those cases, ILA is given off by all possible neighbouring vessels, including common iliac artery, internal iliac, external iliac or from other branches of the internal iliac in both sexes.<sup>5</sup> Here in our cadaver, the novel variation in the origin of ILA was noted from its parent vessel, i.e. an additional ILA distal to the principal ILA (Accessory ILA) originated from the PD of IIA. Encountering such an unexpected variant in pelvic vasculature may lead to inadvertent blood loss during gynaecological and other pelvic surgical procedures. The present study aims to create awareness among surgeons regarding the variation in the origin of ILA (as an accessory ILA), which originated from the PD of IIA to avoid iatrogenic complications during pelvic and gynaecological surgeries.

\* Corresponding author.

E-mail address: [sekhar5883@gmail.com](mailto:sekhar5883@gmail.com) (Rajasekhar SSSN).

## 2. Case Report

We encountered a variation in the pelvic vasculature during the routine dissection of an approximately 60-year-old formalin-embalmed male cadaver at our institution. While dissecting the pelvic region, we visualised the ILA maintaining its conventional course. In addition, we found an accessory vessel arising from the PD of the right IIA just distal to the origin of normal ILA (Figure 1). The principal ILA ascended laterally in front of SIJ, behind the ON and the LST. Further, it coursed towards the medial border of the psoas major muscle where the ILA ended by dividing into iliac and lumbar branches. The iliac branch passed between the iliacus muscle and the bone supplying the iliacus muscle and entered into the nutrient foramen of the iliac bone as a pedicle to supply it. The lumbar branch ascended up to supply the psoas major and quadratus lumborum muscles. The accessory ILA passed laterally in front of SIJ as well as LST and behind the ON and then after reaching the medial border of the psoas major muscle where it ends by giving two stumps, both of which supplied the iliacus muscle and bone (nutrient artery) after passing between them. The distance between the origin and bifurcation of principal ILA is 1.36 cm and between the origin of ILA and the lower edge of L5 was 3.52 cm. The distance between the origin of ILA and the bifurcation of the common iliac artery was 6.47 cm. The distance between accessory ILA and principal ILA was 0.18 cm, and the distance between the origin of accessory ILA and its bifurcation was 0.84 cm. There were no variations in the ILA’s origin, course and termination on the left side. Also, there were no other abnormalities in the pelvic viscera or any other arterial variations in the cadaver.



**Fig. 1:** The right hemi pelvis showing the accessory ILA arising from the PD of right IIA distal to the principal ILA

## 3. Discussion

We report an accessory ILA originating 0.18 cm distal to the origin of principal ILA from the PD of right IIA. The

accessory ILA had the course in front of SIJ, LST, but behind the ON and ended up dividing into iliac and lumbar branches medial to the psoas major muscle (0.84 cm distal from its origin).

Vazquez N et al. dissected the pelvic cavity in Pampas deer and observed two ILA arising as dorsal parietal branches from the IIA.<sup>6</sup> These two arteries arose from a single common trunk, and a similar pattern could be observed in ruminants and swine.<sup>7</sup> In contrast, the human ILA originated from the gluteal cranial artery, similar to feline, equine and rabbit.<sup>7</sup> The dorsal aorta gives rise to the umbilical arteries ventrolaterally. The proximal part of the umbilical artery is joined by a new vessel close to the distal end of the dorsal aorta. The umbilical artery now presents a ventral root, the original stem, and a dorsal root, the new vessel (fifth lumbar intersegmental artery). The ventral root of the umbilical artery completely disappears. The external iliac artery arises from the proximal part of the dorsal root, and the part of the dorsal root distal to the external iliac artery forms the IIA.<sup>8</sup> The IIA divides into anterior and posterior divisions. Ilio lumbar artery arises as the first branch of the PD of the IIA as well as from the trunk of IIA or the obturator artery.<sup>3</sup>

So, the accessory ILA could be attributed to the critical events during the embryological period. These critical events could be due to localised factors, such as increased vascular demand in the pelvic region or generalised factors mediated by genes. These critical events would have resulted in the failure of regression of primitive ILA plexus and getting manifested as double ILAs. With the absence of accessory ILA on the contralateral side, this plausible hypothesis would be localised ischemia generating increased vascular demand.

The accessory ILA, which was encountered in the present case, is rare, and literature regarding the variations of pelvic vasculature is scarce. Bhardwaj et al. conducted a study using 50 formalin-fixed hemipelvis. The site of origin of the ILA and its course was studied. The ILA arose for PD of IIA in 52% of the specimens, from the trunk of the IIA in 38% of the specimens, from the obturator artery in 4% of specimens, and the ILA was absent in 6% of the specimens. In 90% of the specimens, single IIA was noted; in 4%, it was double, and in 6%, it was absent.<sup>3</sup> In the present study, we noted that the accessory ILA arose from the PD of IIA distal to the principal ILA.

ILA is increasingly used as the vascular pedicle for harvesting bone graft because of two reasons: 1) it can be easily identified in the loose connective tissue surrounding the bone and 2) it has sufficient length and diameter, which allows rotation of the pedicle.<sup>9</sup> But these same features make it vulnerable to injuries leading to pelvic haemorrhage. Similarly, when pelvic fractures are treated via an anterior approach, the ILA constitutes one of the vulnerable relations to the sacroiliac joint.<sup>10</sup> Teli et al.

observed that ILA crosses anterior to LST in 30%, posterior in 54% and cleaved course in 8% of the cases.<sup>9</sup> In a case report by Radhakrishnan et al. a complete absence of iliac arterial system on the right side in a 34-year-old man was observed.<sup>11</sup>

The variation in vascular supply is essential while accounting for the fractures involving the ilium. Of the various types, posterior transiliac fractures and pure sacroiliac disruptions are more prone to the risk of haemorrhage for two reasons: a) multiple nutrient vessels entering and supplying the posterior zone of the ilium and b) proximity of sacroiliac joint.<sup>10</sup> Also, Baqué P et al. observed that the origin of ILA projects inside the axis of sacroiliac joint and the mean intersection angle between the joint and artery ranges between 55 and 110.<sup>12</sup> When open-book fractures were simulated in laboratory settings, iliolumbar venous dilacerations was observed in 60% of the cases and no accompanying rupture of ILA.<sup>12</sup> Thus, variations related to iliolumbar vasculature, if any, is critical in determining the outcome of pelvic fractures and associated surgeries. The presence of accessory ILA makes the subject vulnerable to injury during lateral disc excision procedures of L5 and S.<sup>13</sup> ILA also supplies collateral branches to the sacral plexus and variability in the anatomy of ILA could modify the arterial supply of the LST manifesting as iatrogenic sciatica.<sup>14</sup>

#### 4. Conclusion

Even though accessory ILA might be clinically asymptomatic under normal conditions, the knowledge about this would greatly help salvage the patient from being vulnerable to iatrogenic injuries during anterior exposure of lumbosacral junction and posterior sacroiliac fixations. This rare case report adds to the pool of available literature regarding the variations of ILA, which is more relevant from a utilitarian perspective, especially when surgeons decide to harvest iliac bone graft with ILA pedicle and while interpreting CT angiograms of the pelvis.

#### 5. Source of Funding

None.

#### 6. Conflict of Interest

None.


#### References


1. Winters HA, Harten SMV, Royen BJV. The iliolumbar artery as the nutrient pedicle for an iliac crest graft: a new technique

in reconstruction of the lumbar spine. *Plast Reconstr Surg.* 2002;109(1):249–52.

2. Ebraheim NA, Lu J, Biyani A, Yang H. Anatomic considerations of the principal nutrient foramen and artery on internal surface of the ilium. *Surg Radiol Anat.* 1997;19(4):237–9.
3. Bhardwaj R, Bhatnagar S, Suttarwala I, Joshi HR, Hathila S, Vaniya VH. Variations in the origin of iliolumbar artery with its clinical significance. *Int J Health Sci.* 2022;6:3018–25.
4. Chen RS, Liu YX, Liu CB, Hu YS, Xu DC, Zhong SZ, et al. Anatomic basis of iliac crest flap pedicled on the iliolumbar artery. *Surg Radiol Anat.* 1999;21:103–7.
5. Kiray A, Akçalı O, Tayefi H, Koşay C, Ergür I. Anatomical variations of the iliolumbar artery and its relation with surgical landmarks. *Acta Orthop Traumatol Turc.* 2010;44(6):464–8.
6. Vazquez N, Ríos C, Sorriba V, Pérez W. Arterial distribution to the pelvic cavity and pelvic limb in the pampas deer (*Ozotoceros bezoarticus*, Linnaeus 1758). *Anat Histol Embryol.* 2018;47(2):133–9.
7. Barone R. Comparative anatomy of domestic mammals. vol. Vol 5. Paris: Vigot; 2011. p. 904.
8. Tickle C. Development of the limbs. In: Stranding S, editor. *Gray's Anatomy - The anatomical basis of clinical practice.* Edinburgh: Elsevier Churchill Living Stone; 2020. p. 303–14.
9. Teli CG, Kate NN, Kothandaraman U. Morphometry of the iliolumbar artery and the iliolumbar veins and their correlations with the lumbosacral trunk and the obturator nevre. *J Clin Diagn Res.* 2013;7(3):422–6.
10. Yiming A, Baqué P, Rahili A, Mayer J, Braccini AL, Fontaine A, et al. Anatomical study of the blood supply of the coxal bone: radiological and clinical application. *Surg Radiol Anat.* 2002;24(2):81–6.
11. Radhakrishnan V, Kumar R, George D, Abraham GP. Absent right side iliac arterial system, an intraoperative surprise during live related recipient renal transplantation. *Case Rep Transplant.* 2015;2015:894786. doi:10.1155/2015/894786.
12. Baqué P, Trojani C, Delotte J, Séjor E, Senni-Buratti M, DeBaqué F, et al. Anatomical consequences of “open-book” pelvic ring disruption. A cadaver experimental study. *Surg Radiol Anat.* 2005;27(6):487–90.
13. Harrington JF. Far lateral disc excision at L5-S1 complicated by iliolumbar artery incursion: case report. *Neurosurgery.* 2001;48(6):1377–9.
14. Talalwah WA, Dorazi SAA, Soames R. The origin variability of the iliolumbar artery and iatrogenic sciatica. *Eur J Orthop Surg Traumatol.* 2015;25(Suppl 1):199–204.

#### Author biography

**Sankaranarayanan G**, Assistant Professor  <https://orcid.org/0000-0002-7096-0045>

**Rajasekhar SSSN**, Additional Professor  <https://orcid.org/0000-0003-4018-8522>

**Kalaivani K**, Junior Resident  <https://orcid.org/0000-0002-3711-6643>

**Cite this article:** Sankaranarayanan G, Rajasekhar SSSN, Kalaivani K. Accessory iliolumbar artery- A case report. *Indian J Clin Anat Physiol* 2023;10(1):55-57.