

Content available at: <https://www.ipinnovative.com/open-access-journals>

Indian Journal of Clinical Anatomy and Physiology

Journal homepage: <https://www.ijcap.org/>

Review Article

Correlation of functional anatomy of hip musculature with yogic postures- Narrative review

Mrithunjay Rathore^{1,*}, Charu Gupta², Neha Agarwal³, Myuren Jayamohan⁴

¹Dept. of Anatomy, All India Institute of Medical Sciences, Raipur, Chhattisgarh, India

²Morarji Desai National Institute of Yoga, New Delhi, India

³Yoga Therapist, New Delhi, India

⁴Yoga Scholar, Canada



ARTICLE INFO

Article history:

Received 06-10-2022

Accepted 17-10-2022

Available online 12-01-2023

Keywords:

Hip musculature

Yoga asanas

Injuries

ABSTRACT

The present study endeavours to explore the significant role pelvic stability contributes to maintaining the desired alignment in yoga asanas. The faulty postures due to sedentary lifestyles cause weakening of the muscles. This paper explains how Hip Musculature essentially The Gluteus Maximus and Gluteus Medius play an essential role in pelvic stability in many yoga asanas as well as a vital role in the health of our lumbar spine, sacrum, hip joints, and knees. Further, given the recent global interest in yoga asanas, it is critical to identify particular risk factors and injury processes to decrease the frequency with which these injuries occur. Also, this narrative review of the literature on hip musculature and its correlation with yoga asanas focuses on the factors leading to injuries, thereby helping to determine which asanas represent the greatest risk of injury and propose injury-prevention techniques.

This is an Open Access (OA) journal, and articles are distributed under the terms of the [Creative Commons Attribution-NonCommercial-ShareAlike 4.0 License](https://creativecommons.org/licenses/by-nc-sa/4.0/), which allows others to remix, tweak, and build upon the work non-commercially, as long as appropriate credit is given and the new creations are licensed under the identical terms.

For reprints contact: reprint@ipinnovative.com

1. Introduction

Through qualitative and quantitative analysis, this review endeavors to explore the significant role pelvic stability contributes to maintaining the desired alignment in yoga asanas. Yoga asanas are defined as a pose or a posture by engages specific body limbs. Hip musculature (HM) plays an essential role in pelvic stability in many yoga asanas and plays a vital role in the health of our lumbar spine, sacrum, hip joints, and knees. The Gluteus Maximus (GM) and Gluteus Medius (Glu Med) are the body's strongest muscles. They are essential for pelvic and spinal stabilization. They are often used to accelerate the body upward and forward from a position of hip flexion. The imbalance of the hip musculature involved in the movement of the hip girdle is frequently seen in people with complaints

of Lower Back Pain (LBP).¹ Weak hip musculature is commonly associated with a disruption in the joint loading patterns, leading to damage,² Patellofemoral pain syndrome,³ iliotibial band friction syndrome,⁴ anterior cruciate ligament sprain⁵ and chronic ankle instability⁶ are common.

Yoga asana practice is generally thought to be safe; but, as the number of yoga practitioners has increased, so has the number of asana-related injuries. There is limited published evidence on injury rates in yoga asana practices.⁷ Overall, lower extremity injuries comprised 64% of total injuries; specifically, the hip musculature, knee, ankle, feet, and toe.⁸

Given the recent global interest in yoga asanas, it is critical to describe the type and frequency of possible injuries. It is also essential to identify particular risk factors and injury processes to decrease the frequency with which these injuries occur. This narrative review of the literature on hip musculature and its correlation with yoga asanas

* Corresponding author.

E-mail address: drmrithunjay77@gmail.com (M. Rathore).

focuses on the factors leading to injuries. Thereby helping to determine which asanas represent the greatest risk of injury, and propose injury-prevention techniques.

2. Functional Anatomy of Gluteal Muscle

GM is superficially the largest muscle of the body. This single-joint muscle allows for the increased force production to maintain an upright position needed for walking. GM proximally originated from (Figure 2) the sacrum, dorsal sacral ligament, posterior aspect of the iliac crest, and Sacro tuberos ligament. The muscle fibers run distally and inferiorly to distal insertion, where they split into two compartments. The upper part of the muscle is inserted into the iliotibial tract while the lower part of the muscle is attached to the gluteal tuberosity of the femur. Due to its attachments, GM is primarily involved in hip extension and lateral rotation. GM has many different functions such as providing sacroiliac joint stability (SIJ). There is very little movement at the SIJ which is important for the primary function of load transfer from the trunk to the legs. If the movement occurs at the joint, a positional change may occur at the SIJ and could lead to SIJ dysfunction and low back pain. The tightness of GM limits forward bending at the hips such as in Uttanasana (Standing Forward Bend) and weakness limits the backbends. GM assumes two basic functions, to act as both a local and global stabilizer. As a local stabilizer, the GM roles include segmental stabilization, of the lower back via its connection with erector spinae and thoracolumbar fascia,⁹ which forms the rigging of the lower back, which supports the spine, holding it up like rigging to the mast of a ship. When thgluteus maximus contracts, it tightens the rigging downward in a crosswise fashion, lengthening the lumbar spine and stabilizing the sacrum, especially in activities in which the gluteal are active, such as walking and bending forward. Sacroiliac joint by bracing and compression¹⁰ lumbosacral region via co-contraction with psoas major¹¹ as well as femoral head stabilization in the acetabulum and due to its attachment into the iliotibial band, it plays a role in stabilizing the knee joint in extension.

Disuse of gluteal muscles leads to atrophy, and unfortunately many have postural habits that largely avoid the use of the gluteal. A common habit is a swayback posture, in which the hips sway forward of the line of gravity that is running through the legs. To compensate for this misalignment, the knees usually lock backward while the hips tilt forward and the upper back rounds. Weakness of the GM has been implicated in numerous injury types such as anterior knee pain¹² anterior cruciate ligaments injuries¹³ low back pain¹⁴ hamstring strain¹⁵ femoral acetabular impingement syndrome ankle sprains.¹⁶

Faulty postures due to sedentary lifestyles cause weakening of the GM. It is thought prolonged sitting reduces the activation of GM and over time these muscles

become weak.¹⁷ This weakness of GM is thought to increase reliance on the secondary hip extensor muscles, such as the hamstrings and hip adductors to produce hip extension torque¹⁸ clinically referred to as synergistic dominance. This is due to the human body utilizing the path of least resistance, which refers to utilizing the energy-efficient motor pattern regardless whether this uses what would be considered the primary agonist for that role.¹⁹ This would increase the relative demands placed upon the synergist muscles and potentially contribute to pain and strain injuries associated with these muscles. Furthermore, altered posture of the pelvis can influence the length-tension relationship of GM, as such, reducing its stabilizing capacity. Associated with hip flexor and lower back muscle tightness and local core weakness is an anterior tilted pelvis, it is called as lower cross imbalance, which elongates the GM and places the muscle in a mechanically disadvantaged position.

To begin to correct these lower crossed imbalances, start with hip flexor opening movements like lunge variations with the back knee down and lower back opening movements such as Pawanmuktasana (knee-to-chest pose). Also include abdominal strengthening poses or movements like plank and gluteal strengthening poses like Utkatasana (Chair Pose).

The Gmed is the abductor of the hip joint and it is attached proximally to the external surface of the ilium above the gluteal line and distally attached onto the lateral aspect of the greater trochanter.(Figure 1) Anatomically, Gmed is the largest abductor of the femur from the pelvis, accounting for 60% of the total abductor cross-sectional area and leg abduction to the tibia is caused by other abductors such as TFL and gluteus maximus.²⁰ In particular, the posterior fibers of Gmed also act as external rotators of the hip. The Gluteus Minimus, Tensor Fascia Lata (TFL) and Piriformis are the synergist muscle and adductor groups are the antagonistic muscle of Gmed. The Gmed (especially the posterior fibers) controls femoral adduction and stabilize the pelvis by counteracting gravity during dynamic lower-extremity motion²¹ and is commonly activated during walking.

Coordinate control of the hip and ankle is important for maintaining postural stability. Results show that individuals with diminished hip abductor muscle strength demonstrated decrease medial lateral postural stability.²² Traditionally, impaired function of the hip abductors was considered the cause of the Trendelenburg gait, which is characterized by an excessive pelvic drop towards the contralateral side.

As the weight of the body is suspended on one leg, these muscles prevent the opposite hip from sagging. Weakness in this muscle can result in Trendelenburg gait in which the individuals opposite hip sag upon weight bearing hip. Fall while walking, a common feature in the old age, is generally due to weakness of the Glu Med. Weakness in

Glu Med also limits standing pose on one leg Utthita Hasta Padangusthasana (Extended hand-to-big-toe pose). Similarly, tightness in the Glu Med limits yoga asanas that require extensive external rotation of the femur at the hip Padmasana (Lotus Pose). Parsvottanasana (Pyramid Pose), the lateral extension, is a standing posture which lengthen the torso over one leg and bending forward from the hip joints awakens an intense stretch in the deep muscles of the gluteal region as well as in the hamstrings, and dramatically strengthens the lower back. Parsvottanasana also improves balance and isolates the movement of the pelvis from that of the upper torso.

3. Gluteal Muscle Activation during Yoga Asana

The hips are the base of support for the spine. Gluteal weakness is commonly associated with an imbalance in the joint loading patterns and further; lead to various skeletomuscular disorders; therefore, gluteal muscle activation is necessary to avoid such type of muscular imbalance. Gluteal muscle activation of a specific form of yoga helps establish natural harmony and functional balance between various organ systems, leading to better health and a feeling of well-being. The practice-specific asana has developed as an approach to align, strengthen, and balance the body's structure. Further, it has been used to enhance dynamic control of gluteal muscles to reduce lower back pain (LBP) through increased hip and spinal flexibility.

Alternation in function and properties of GM have been found in association with kinetic chain changes of the lower limb due to pain and injury. For example, patients (N=20) suffering from ankle sprain injuries have been shown reduce activation levels of GM.¹⁶ GM has also been found fatigue faster in subjects with chronic lower back pain with avoidance of aggravating movement of the lumbar spine leading to subsequent deconditioning of the back and hip extensor muscles.¹⁴

A study of the muscle activation pattern of GM and Glu Med in the tree pose, warrior two pose, warrior three pose, half moon pose, and bird dog pose. They found greatest GM activation occurred during Half Moon Pose on the lifted/back leg (63.3% MVIC), followed by Half Moon Pose on the stance/front leg (61.7% MVIC), then on the lifted/back leg during Warrior Three Pose (46.1% MVIC). The highest G Med activation was recorded during Half Moon Pose on the lifted/back leg (41.8% MVIC), followed by Warrior Three Pose on the lifted/back leg (41.6% MVIC). The results of the current study indicate that the Half Moon Pose and Warrior Three Pose had the highest activation for the gluteal muscles studied in healthy young adults with variable yoga experience. The high to very high activation levels found indicates that both of these poses have the potential to provide strengthening stimuli.²³

Mullerpatan et al studied the muscle activation of Surya namaskar and they found the gluteus maximus muscle

activation is higher in the Ashwa Sanchalanasana (Low lunge pose) about 38.5% MVC in Poses 9 and 4^{24,25} shown that GTA (gluteal to TFL muscle activation index) significantly higher on the side bridge lifting the dominant leg and side bridges exercise improve the gluteal muscle activation. (26) quantify the muscle activation patterns of Rectus abdominis (RA), External oblique (EO), Erector spinae (ES), Lumbar multifidus (LM), Gmax, and tensor fasciae lata (TFL) during Side sling plank (SSP) with three different hip rotation compared to side lying hip abduction (SHA) exercise in the subject with the GluMed weakness. They found SSP could be prescribe for the patients who have reduced Glu med strength after injuries. Especially, SSP- M could be applied for patients who have Glu med weakness with dominant TFL.

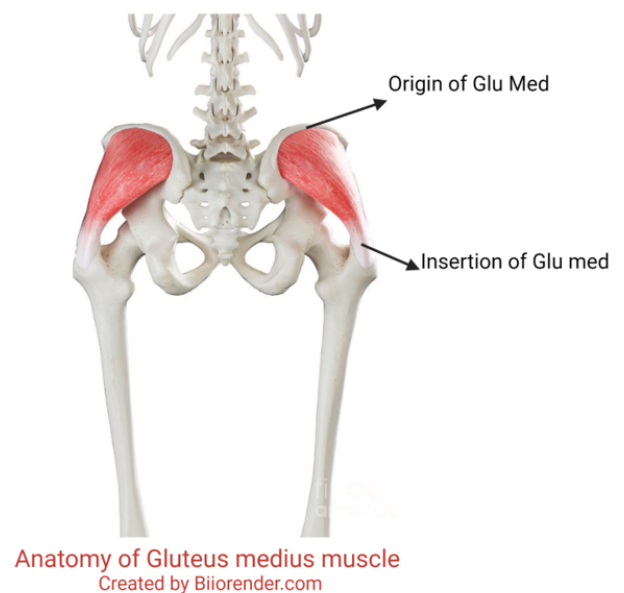
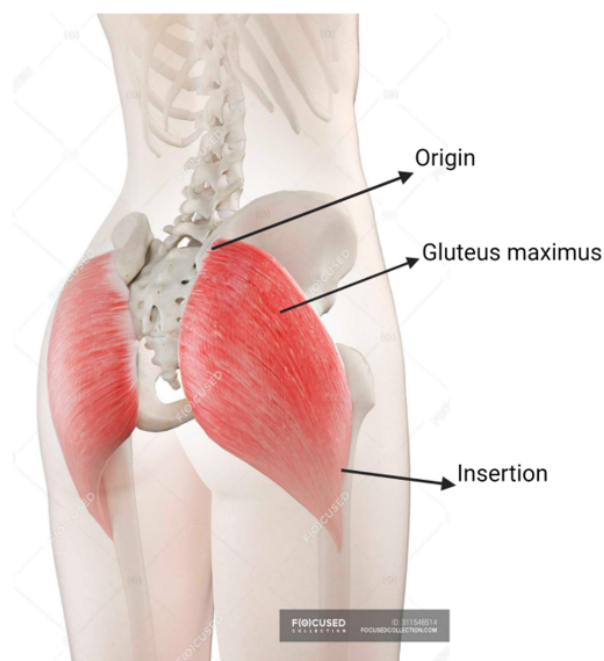

Fig. 1: Trochanter

An observed study on the analysis of Trikonasana (Triangle pose) had found that muscle groups such as external right obliques muscle, rectus abdominis of the front leg, and GM and Glu Med of the rear leg were observed to undergo major activation during an isometric contraction while performing Trikonasana.²⁶ (Kathleen et al) studied the muscle activation patterns of anterior tibialis (TA), medial head of gastrocnemius (GA), rectus femoris (RF), biceps femoris (BF) and gluteus medius (GM) in experienced yoga practitioners during selected yoga asanas. They found that half-moon (HM) and warrior (WR) the GA muscle showed the greatest activity.²⁷ Reiman et al studied the trunk and hip muscle activation during yoga pose and they found that High Plank ($P < 0.0001$) generated greater activation of the GM.²⁸ (Ni et al.)²⁹ observed maximum GM activity in Virabhadrasana-I (Warrior pose I). (Queiroz



Anatomy of Gluteus maximus muscle
Created by Biorender.com

Fig. 2: Sacrotuberus ligaments

et al.),³⁰ studied muscle activation pattern variation in various pelvic and trunk positions in knee stretch exercises and found that exercises involving pelvic retroversion and trunk flexion, resembling Vyaghrasana (Tiger pose), consistently increased GM activity compared to other trunk and pelvis positions. Ekstrom et al.,³¹ studied the muscle activities of RA, EO, LT, GM, Glu Med, and hamstring in nine rehabilitation exercises and reported that the muscle activation pattern of GM had significantly greater activation with the Quadruped arm/lower extremity lift similar to variation of Marjariasana (Cat stretch pose) ($56\% \pm 22\%$ MVIC). Distefano et al.,³² studied gluteal muscle activation during common therapeutic exercises and reported that GM activation during the single limb squat and single limb dead lift (as in Virabhadrasana) was significantly greater than during the lateral band walk ($27\% \pm 16\%$ MVIC), hip clam ($34\% \pm 27\%$ MVIC) and hop forward exercises ($35\% \pm 22\%$ MVIC). Farrokhi et al.¹⁸ also found GM activation was highest when the subjects performed a forward lunge with flexed forward Low Anjaneyasan (Low lunge pose) (22% MVIC) relative to the hip and pelvis. Reiman et al.²⁸ observed GM and Glu Med activation during rehabilitation exercise in both patients with LBP and in patients with lower extremity pathology. They found GM activation during the single limb dead lift ($59\% \pm 28\%$ MVIC) was significantly greater than other rehabilitation exercise modules, and Glu Med activation during side bridge ($74\% \pm 30\%$ MVIC) was significantly higher than other rehabilitation exercise

modules.

Ekstrom et al., studied RA, EO, LT, GM, Glu Med and hamstrings muscle in nine rehabilitation exercise for spine, hip and knee which are important for core stabilization.³¹ They observed that Glu Med showed greater activation with the side bridge posture (Vasisthasana) ($74\% \pm 30\%$ MVIC). Yu et al.,³³ studied physical demands of Vrikshasana (Tree pose) and Utthita Hasta Padangusthasana (Standing hand to big toe pose) when performed by geriatric subjects and showed that the average EMG activity of Glu Med in Vakrasana was $32.15\% \pm 7.13\%$ MVIC and Utthita Hasta Padangusthasana was $44.28\% \pm 6.38\%$ MVIC. Wang et al.,³⁴ studied the biomechanical demands of standing yogic postures in elderly and showed that average EMG signals of hamstring was significantly higher in Utthita Hasta Padangusthasana ($85.9\% \pm 112.0\%$ MVIC) and Vrikshasana ($37.9\% \pm 25.2\%$ MVIC).

Distefano et al.,³² studied gluteal muscle activation during common therapeutic exercises used in rehabilitation and injuries prevention programs and observed that Glu Med activity was significantly greater during side lying hip abduction posture similar to variation of Vasisthasana (Side plank pose) ($81\% \pm 42\%$ MVIC) compared to hip clam ($40\% \pm 38\%$ MVIC), lunges ($48\% \pm 21\%$ MVIC), and hop ($48\% \pm 25\%$ MVIC) exercises. Oliver et al.³⁵ studied select muscle activation during isometric core exercises, and showed that Glu Med activity was significantly higher to a variation of Setu Bandhasana (Bridge pose).

Hip dysfunction, which result in weakness and limited range of motion, is one of the causes for LBP and various pathologies of lower extremities involving the knee. The practice of the above-mentioned yogic asana may minimize the possibility of these injuries by activating the specific hip musculature and can be used as the therapeutic yoga protocol for various Musculoskeletal disorders.

4. Conclusion

There were clear benefits to be seen in effect of various yoga asanas in the hip musculature and its practice may minimize the possibility of these injuries by activating the specific hip musculature and can be used as the therapeutic yoga protocol for various Musculoskeletal disorders.

5. Source of Funding

None.

6. Conflict of Interest

None.

References

1. Shum GLK, Crosbie J, Lee RYW. Movement coordination of the lumbar spine and hip during a picking up activity in low back pain subjects. *Eur Spine J.* 2007;16(6):749–58.

2. Guilak F. Biomechanical factors in osteoarthritis. *Best Pract Res Clin Rheumatol*. 2011;25(6):815–23.
3. Petersen W, Ellermann A, Gösele-Koppenburg A, Best R, Rembitzki IV, Brüggemann GP, et al. Patellofemoral pain syndrome. *Knee Surg Sports Traumatol Arthrosc*. 2014;22(10):2264–74.
4. Lavine R. Iliotibial band friction syndrome. *Curr Rev Musculoskelet Med*. 2010;3(1-4):18–22.
5. Hewett TE, Myer GD, Ford KR. Anterior cruciate ligament injuries in female athletes: Part 1, mechanisms and risk factors. *Am J Sports Med*. 2006;34(2):299–311.
6. Xue X, Ma T, Li Q, Song Y, Hua Y. Chronic ankle instability is associated with proprioception deficits: A systematic review and meta-analysis. *J Sport Heal Sci*. 2021;10(2):182–91.
7. Cramer H, Quinker D, Schumann D, Wardle J, Dobos G, Lauche R. Adverse effects of yoga: a national cross-sectional survey. *BMC Complement Altern Med*. 2019;19. doi:10.1186/s12906-019-2612-7.
8. Bekhradi A, Wong D, Gerrie BJ, McCulloch PC, Varner KE, Ellis TJ, et al. Although the injury rate of yoga is low, nearly two-thirds of musculoskeletal injuries in yoga affect the lower extremity: a systematic review. *J ISAKOS*. 2018;3(4):229–34.
9. Barker PJ, Hapuarachchi KS, Ross JA, Sambaiw E, Ranger TA, Briggs CA. Anatomy and biomechanics of gluteus maximus and the thoracolumbar fascia at the sacroiliac joint. *Clin Anat*. 2014;27(2):234–40.
10. Kawaguchi K, Taketomi S, Mizutani Y, Inui H, Yamagami R, Kono K, et al. Hip Abductor Muscle Strength Deficit as a Risk Factor for Inversion Ankle Sprain in Male College Soccer Players: A Prospective Cohort Study. *Orthop J Sport Med*. 2021;9(7). doi:10.1177/23259671211020287.
11. Lewis CL, Sahrman SA, Moran DW. Anterior hip joint force increases with hip extension, decreased gluteal force, or decreased iliopsoas force. *J Biomech*. 2007;40(16):3725–31.
12. Powers CM, Ward SR, Fredericson M, Guillet M, Shellock FG. Patellofemoral kinematics during weight-bearing and non-weight-bearing knee extension in persons with lateral subluxation of the patella: a preliminary study. *J Orthop Sports Phys Ther*. 2003;33(11):677–85.
13. Khayambashi K, Ghoddosi N, Straub RK, Powers CM. Hip Muscle Strength Predicts Noncontact Anterior Cruciate Ligament Injury in Male and Female Athletes: A Prospective Study. *Am J Sports Med*. 2016;44(2):355–61.
14. Kankaanpää M, Taimela S, Laaksonen D, Hänninen O, Airaksinen O. Back and hip extensor fatigability in chronic low back pain patients and controls. *Arch Phys Med Rehabil*. 1998;79(4):412–7.
15. Schuermans J, Danneels L, Tiggelen DV, Palmans T, Witvrouw E. Proximal Neuromuscular Control Protects Against Hamstring Injuries in Male Soccer Players: A Prospective Study With Electromyography Time-Series Analysis During Maximal Sprinting. *Am J Sports Med*. 2017;45(6):1315–25.
16. Bullock-Saxton JE, Janda V, Bullock MI. The influence of ankle sprain injury on muscle activation during hip extension. *Int J Sports Med*. 1994;15(6):330–4.
17. Marzke MW, Longhill JM, Rasmussen SA. Gluteus maximus muscle function and the origin of hominid bipedality. *Am J Phys Anthropol*. 1988;77(4):519–28.
18. Wagner T, Behnia N, Ancheta W, Shen R, Farrokhi S, Powers CM. Strengthening and neuromuscular reeducation of the gluteus maximus in a triathlete with exercise-associated cramping of the hamstrings. *J Orthop Sports Phys Ther*. 2010;40(2):112–9.
19. Sahrman S, Azevedo DC, Dillena LV. Diagnosis and treatment of movement system impairment syndromes. *Braz J Phys Ther*. 2017;21(6):391–9.
20. Osborne HR, Quinlan JF, Allison GT. Hip abduction weakness in elite junior footballers is common but easy to correct quickly: a prospective sports team cohort based study. *Sports Med Arthrosc Rehabil Ther Technol*. 2012;4(1):37. doi:10.1186/1758-2555-4-37.
21. O'sullivan K, Smith SM, Sainsbury D. Electromyographic analysis of the three subdivisions of gluteus medius during weight-bearing exercises. *Sports Med Arthrosc Rehabil Ther Technol*. 2010;2:17. doi:10.1186/1758-2555-2-17.
22. Lee SP, Powers CM. Individuals with diminished hip abductor muscle strength exhibit altered ankle biomechanics and neuromuscular activation during unipedal balance tasks. *Gait Posture*. 2014;39(3):933–8.
23. Lehecka BJ, Stoffregen S, May A, Thomas J, Mettling A, Hoover J, et al. Gluteal Muscle Activation During Common Yoga Poses. *Int J Sports Phys Ther*. 2021;16(3):662–70.
24. Mullerpatan RP, Agarwal BM, Shetty TV. Exploration of Muscle Activity Using Surface Electromyography While Performing Surya Namaskar. *Int J Yoga*. 2020;13(2):137–43.
25. Khosrokiani Z, Letafatkar A, Sheikhi B, Thomas AC, Aghaie-Ataabadi P, Hedayati MT. Hip and Core Muscle Activation During High-Load Core Stabilization Exercises. *Sports Health*. 2022;14(3):415–23.
26. Kumar A, Kapse RC, Paul N, Vanjare AM, Omkar SN. Musculoskeletal Modeling and Analysis of Trikonasana. *Int J Yoga*. 2018;11(3):201–7.
27. Kelley K, Slattery K, Apollo K. An electromyographic analysis of selected asana in experienced yogic practitioners. *J Bodyw Mov Ther*. 2018;22(1):152–8.
28. Reiman MP, Bolgla LA, Loudon JK. A literature review of studies evaluating gluteus maximus and gluteus medius activation during rehabilitation exercises. *Physiother Theory Pract*. 2012;28(4):257–68.
29. Ni M, Mooney K, Harriell K, Balachandran A, Signorile J. Core muscle function during specific yoga poses. *Complement Ther Med*. 2014;22(2):235–43.
30. Queiroz BC, Cagliari MF, Amorim CF, Sacco IC. Muscle activation during four Pilates core stability exercises in quadruped position. *Arch Phys Med Rehabil*. 2010;91(1):86–92.
31. Ekstrom RA, Donatelli RA, Carp KC. Electromyographic analysis of core trunk, hip, and thigh muscles during 9 rehabilitation exercises. *J Orthop Sports Phys Ther*. 2007;37(12):754–62.
32. Distefano LJ, Blackburn JT, Marshall SW, Padua DA. Gluteal muscle activation during common therapeutic exercises. *J Orthop Sports Phys Ther*. 2009;39(7):532–40.
33. Yu SSY, Wang MY, Samarawickrame S, Hashish R, Kazadi L, Greendale GA, et al. The Physical Demands of the Tree (Vrikshasana) and One-Leg Balance (Utthita Hasta Padangusthasana) Poses Performed by Seniors: A Biomechanical Examination. *Evid Based Complement Alternat Med*. 2012;2012:971896.
34. Salem GJ, Yu SSY, Wang MY, Samarawickrame S, Hashish R, Azen SP, et al. Physical demand profiles of Hatha yoga postures performed by older adults. *Evid Based Complement Alternat Med*. 2013;2013:165763.
35. Oliver GD, Stone AJ, Plummer H. Electromyographic examination of selected muscle activation during isometric core exercises. *Clin J Sport Med*. 2010;20(6):452–7.

Author biography

Mrithunjay Rathore, Additional Professor

Charu Gupta, Yoga Student

Neha Agarwal, Yoga Therapist

Myuren Jayamohan, Yoga Scholar

Cite this article: Rathore M, Gupta C, Agarwal N, Jayamohan M. Correlation of functional anatomy of hip musculature with yogic postures- Narrative review. *Indian J Clin Anat Physiol* 2022;9(4):231-235.