

Content available at: <https://www.ipinnovative.com/open-access-journals>

Indian Journal of Clinical Anatomy and Physiology

Journal homepage: <https://www.ijcap.org/>

Case Report

Presence of radix entomolaris and paramolaris in primary teeth in children of Garhwa district: A report on two cases

Nilotpol Kashyap^{1,*}, Soni Patel¹, Shreya Rani¹, Nishi Singh¹, Chitra Ranjan Singh¹

¹Vananchal Dental College and Hospital, Garhwa, Jharkhand, India



ARTICLE INFO

Article history:

Received 28-07-2022

Accepted 29-09-2022

Available online 10-10-2022

Keywords:

Extra roots

Radix Entomolaris

Radix paramolaris periapical radiographs

ABSTRACT

Pediatric dentistry is not only about the hard (Teeth) and soft tissues which are visible and can be treated. There are so many dental anomalies which can not be seen through naked eyes inspite of them being in the oral cavity unnoticed i.e, anomalies of the root.¹

These anomalies are detected only while patient undergo treatment for the culprit tooth and these anomalies are present adjacent to the tooth or the tooth which undergoes radiographic examination for the diagnosis.² During diagnosis primary molar radiographs shows extra root (Supernumerary root). The normal anatomy of mandibular molars consists of two roots but in rarest of the rare conditions there are three roots called extra roots. When this extra root is present distolingually to the main distal root it is called “Radix Entomolaris” and when it is present mesiobuccally to main mesial root it is called “Paramolaris”. The purpose of this article is to discuss the prevalence, anatomy, classification, clinical and radiographic diagnosis, and significance of supernumerary roots in contemporary clinical pediatric dentistry practice.

This is an Open Access (OA) journal, and articles are distributed under the terms of the [Creative Commons Attribution-NonCommercial-ShareAlike 4.0 License](https://creativecommons.org/licenses/by-nc-sa/4.0/), which allows others to remix, tweak, and build upon the work non-commercially, as long as appropriate credit is given and the new creations are licensed under the identical terms.

For reprints contact: reprint@ipinnovative.com

1. Introduction

The morphology of primary teeth in comparison to permanent is different in its enamel, dentin thickness, more accentuated pulp horns which lead to early spread of infection to the pulp once caries starts. Pediatric endodontics is the method to remove infection from the coronal and radicular pulp followed by chemico-mechanical cleaning and obturating with suitable material. Generally mandibular molars (primary or permanent dentition) have two roots that is mesial and distal with three canals and sometimes four canals also which is very rare. Two canals in the mesial root being mesiobuccal and mesiolingual canals and one canal in distal root.³

Sometimes two canals are also present in distal canal which often creates a rare chance of presence of extra root also termed as “Radix entomolaris” or “Paramolaris”.⁴ The

prevalence of dental anomalies is less in the deciduous dentition than in permanent dentition. The occurrence of an extra distal root in these mandibular molars is considered as a racial characteristic of certain native Indian and Mongoloid populations.

This extra root should also be endodontically treated and obturated with suitable obturating material to prevent premature extraction.

2. Case Report

2.1. Case 1

A 5 years old male patient came in the Department of pedodontics and preventive dentistry in Vananchal Dental College and Hospital Garhwa with a chief complain of pain and swelling in lower right back tooth region since 4 to 5 days. Access opening was done followed by working length determination with No.10K file and RVG was taken.

* Corresponding author.

E-mail address: nilkash9365@gmail.com (N. Kashyap).

On Radiographic evaluation this extra root was detected (Figure 1). Chemico-mechanical preparation was done and then patient was recalled after 2 days.

After two days also the pain and swelling did not subside so the tooth was planned for extraction. The primary molar was extracted.

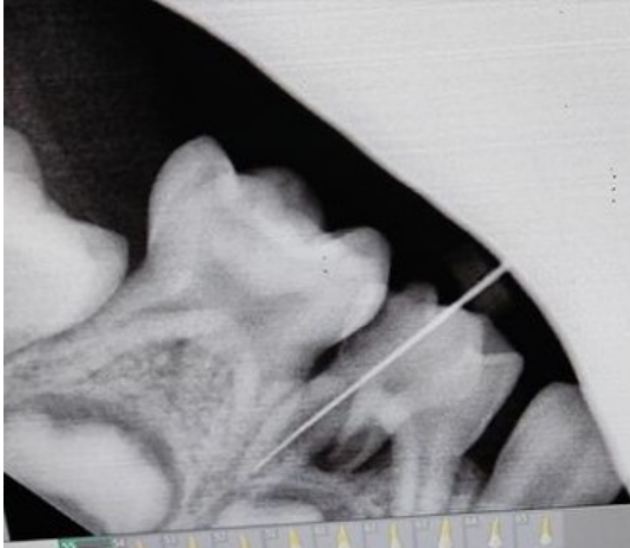


Fig. 1:

2.2. Case 2

A 10 years old male patient came in the department with a chief complain of pain, swelling and mobility in lower right back tooth region, medication was given and patient was recalled after 3 days for extraction as on the radiographic evaluation roots were resorbed more than half and interradicular radiolucency was also present. After extraction, it was observed that the mandibular primary molar had three roots Figure 2.

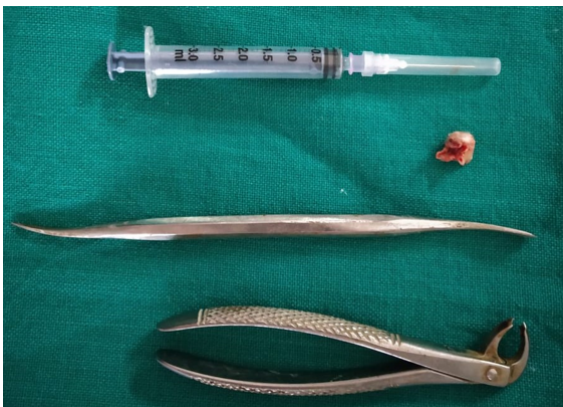

Fig. 2:

3. Discussion

The success of pediatric endodontics is determined by thorough clinical examination, diagnosis, adequate chemo-mechanical preparation, and three-dimensional obturation with suitable obturating material.⁵

The first stage of endodontic triad, i.e., correct diagnosis is one of the most important steps towards the success of the endodontic procedure. One of the main reasons for the failure of root canal treatment is incomplete removal of pulpal tissue and microbes from all the pulp canals. Hence, proper radiographic diagnosis plays a very important role in the successful treatment of endodontic therapy to rule out any extra canals.⁶

So, radiographs must be taken at different angulations to decrease the chances of “missed canals”. The prevalence rate of Radix entomolaris is less than 5% in the Indian population and such cases are not seen commonly during dental treatment. The exact etiology of radix entomolaris is still idiopathic but according to some authors it may be due to disturbance during odontogenesis or may be due to the high degree of genetic penetrance.⁷

To avoid the failure of endodontic therapy, minimum two different angulated diagnostic radiographs must be taken with the careful clinical examination. If radix entomolaris is diagnosed in the radiograph before commencing the endodontic treatment, the access cavity design should be modified trapezoidal so that the additional canal orifice can be easily accessed.^{8,9}

Through knowledge of the law of symmetry, various methods like visualization of the dentinal map and bleeding points in the canal orifice using magnification, ultrasonic tips, staining the pulp chamber floor with 1% methylene blue dye, performing champagne bubble test, and cone beam computed tomography imaging will help identify the missed canal.

According to De Moor et al.^{10,11} the morphology of radix entomolaris canals in the majority of cases, were curved. Hence, after initial root canal exploration with small files (size 10 or less) together with radiographic working length and curvature determination, the creation of straight-line access and preparation of glide path has to be emphasized to avoid procedural errors.

4. Conclusion

The presence of extra root and its complex anatomical morphology creates a challenge for endodontic therapy. Prognosis of endodontic therapy is determined by the identification of radix entomolaris and para molaris. At 30° mesial and distal angulations preoperative radiographs and their proper interpretation are mandatory to prevent any misdiagnosis of RE. So accurate radiographic diagnosis, thorough knowledge about the variation in root canal morphology, prevalence and canal configuration of radix

entomolaris are the major factors for the success of endodontic treatment.

5. Source of Funding

None.

6. Conflict of Interest

None.

References

1. Radix Entomolaris: Case Report with Clinical Implication Int. *J Clin Pediatr Dent*. 2018;11(6):536–8.
2. Vertucci FJ. Root canal anatomy of the human permanent teeth. *Oral Surg Oral Med Oral Pathol*. 1984;58(5):589–99.
3. Barker BC, Parsons KC, Mills PR, Williams GL. Anatomy of root canals. III. Permanent mandibular molars. *Aust Dent J*. 1974;19(6):408–13.
4. Calberson FL, DeMoor RJ, Deroose CA. The radix entomolaris and paramolaris: clinical approach in endodontics. *J Endod*. 2007;33(1):58–63.
5. Tratman EK. Three-rooted lower molars in man and their racial distribution. *Br Dent J*. 1938;64:264–74.
6. Curzon ME, Curzon JA. Three-rooted mandibular molars in the Keewatin Eskimo. *J Can Dent Assoc (Tor)*. 1971;37(2):71–2.
7. Turner CG. Three-rooted mandibular first permanent molars and the question of American Indian origins. *Am J Phys Anthropol*. 1971;34(2):229–41.
8. Yew SC, Chan K. A retrospective study of endodontically treated mandibular first molars in a Chinese population. *J Endod*. 1993;19(9):471–3.
9. Abella F, Patel S, Duran-Sindreu F, Mercadé M, Roig M. Mandibular first molars with disto-lingual roots: review and clinical management. *Int Endod J*. 2012;45(11):963–78.
10. DeMoor RJG, Deroose C, Calberson FLG. The radix entomolaris in mandibular first molars: an endodontic challenge. *Int Endod J*. 2004;37(11):789–99.
11. Calberson FL, DeMoor RJ, Deroose CA. The radix entomolaris and paramolaris: clinical approach in endodontics. *J Endod*. 2007;33(1):58–63.

Author biography

Nilotpol Kashyap, Professor & HOD

Soni Patel, PG Second Year Student

Shreya Rani, PG Second Year Student

Nishi Singh, PG Student

Chitra Ranjan Singh, Final Year BDS Student

Cite this article: Kashyap N, Patel S, Rani S, Singh N, Singh CR. Presence of radix entomolaris and paramolaris in primary teeth in children of Garhwa district: A report on two cases. *Indian J Clin Anat Physiol* 2022;9(3):226–228.