

Content available at: <https://www.ipinnovative.com/open-access-journals>

Indian Journal of Clinical Anatomy and Physiology

Journal homepage: <https://www.ijcap.org/>

## Original Research Article

## Study of suprascapular notch converted into a foramen in adult human scapulae in Karnataka region

Ravikumar V<sup>1,\*</sup>, Siri AM<sup>1</sup><sup>1</sup>Dept. of Anatomy,, Subbaiah Institute of Medical Science, Shimoga, Karnataka, India

## ARTICLE INFO

## Article history:

Received 03-03-2022

Accepted 21-03-2022

Available online 15-07-2022

## Keywords:

Suprascapular nerve

Suprascapular notch

Scapula bone

Transverse scapular ligament

## ABSTRACT

Scapula is a triangular bone present in the back, which articulates with the humerus and clavicle forming the shoulder girdle. In the superior border of the scapula there is a notch called the suprascapular notch, through which the suprascapular nerve pass. The suprascapular nerve can be compressed by the ossified part of the transverse scapular ligament a cause for neuropathies.

The present study was done on adult scapulae in department of Anatomy SUIIMS & R.C. Shimoga, where the transverse scapular ligament [TSL] was ossified in 10 scapulae out of 127 adult dry scapulae [7.87%] studied of unknown sex. It was also noted that 6 out of 10 scapulae belonged to the right side & 4 to left side showing a slight preponderance to the right side. Incidence of the complete suprascapular foramen varies from one geographical region to other region, work nature of individuals and is variable with the samples collected by different workers for the study.

The compression of the suprascapular nerve is an acquired neuropathy leading to neuromuscular deficits and decrease in the range of motion of the shoulder. Suprascapular nerve blocks are given in this region. The knowledge of this type of nerve compression is helpful for evaluation of patients with neurovascular deficits to orthopedicians, radiologists, anaesthetists and surgeons in their clinical practice.

This is an Open Access (OA) journal, and articles are distributed under the terms of the [Creative Commons Attribution-NonCommercial-ShareAlike 4.0 License](https://creativecommons.org/licenses/by-nc-sa/4.0/), which allows others to remix, tweak, and build upon the work non-commercially, as long as appropriate credit is given and the new creations are licensed under the identical terms.

For reprints contact: [reprint@ipinnovative.com](mailto:reprint@ipinnovative.com)

## 1. Introduction

Scapula is a large triangular flat bone in the posterolateral aspect of upper part of thorax extending from 2<sup>nd</sup> to the 7<sup>th</sup> rib. It has 3 borders, lateral medial & superior borders. Superior border is the thinnest & shortest of all and begins from the superior angle and passing horizontally lateral wards, it ends into a notch, the suprascapular notch, which separates it from the root of the corocoid process.<sup>1</sup>

The inferior belly of omohyoid muscle takes origin from the medial end of the notch. A transverse scapular ligament [TSL] bridges across the notch to form a suprascapular foramen which transmits the suprascapular nerve to the suprascapular fossa. The suprascapular vessels, however

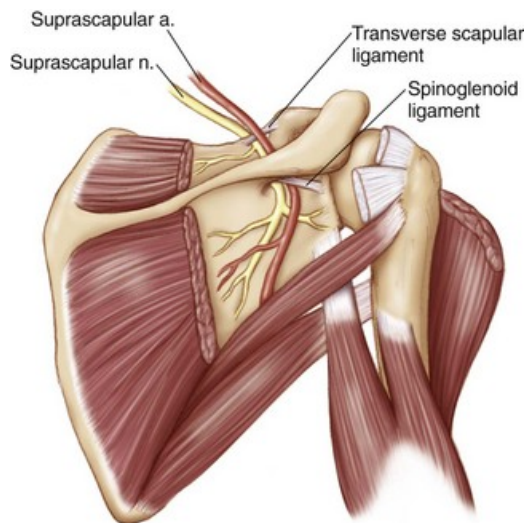
reach the fossa above the foramen & its ligament.<sup>2</sup> The notch is bridged by the superior transverse ligament or transverse scapular ligament which is attached to the root of the corocoid process & medially to the summit of the notch. The ligament is sometimes ossified, the foramen thus completed, transmits the suprascapular nerve, whereas the suprascapular vessels pass backwards above the ligament.<sup>3</sup>

Later to this course, the suprascapular nerve & suprascapular artery together pass through the spinoglenoidal notch being covered by spinoglenoidal ligament as shown in the Figure 1. The compression of the suprascapular nerve can be due to the ossified transverse scapular ligament, congenital abnormalities or fracture of the scapula.<sup>4</sup>

The ossified suprascapular ligament may be of various patterns, it can be a partial or completely ossified, the

\* Corresponding author.

E-mail address: [drravikumar.rk79@gmail.com](mailto:drravikumar.rk79@gmail.com) (Ravikumar V).



**Fig. 1:** Showing the course of suprascapular nerve & artery in superior border of scapula

ligament could be a trifurcated or can have anomalous bands of it. A thorough imaging and knowledge of anatomy of the course of the nerve is helpful in surgeries of decompression of the suprascapular nerve.<sup>5</sup> Hence the aim of the present study is to know the course and variations in the suprascapular nerve which can be compressed by ossified transverse scapular ligament [TSL] leading to the nerve entrapment and other neurovascular deficits.

Similar studies on the ossified transverse scapular ligament have been done. In a study by Shiksha Jangde<sup>6</sup>(2015) incidence of complete ossification was 4.1% of the bones studied. In a study by Sachin Patil<sup>7</sup> (2019) the suprascapular ligament was ossified completely in 3.54% bones studied. Marcos Rassi et al<sup>8</sup> (2012) showed in their study that suprascapular block is an effective therapeutic method used by anaesthesiologists both for regional anaesthesia & post operative analgesia of the surgeries on shoulder. They concluded that the suprascapular nerve block is an extremely effective procedure in the shoulder pain therapy.<sup>8</sup>

All the data indicate that a thorough knowledge of the course of suprascapular nerve and nature of the notch whether partially or completely ossified is to be evaluated before the surgical decompression and release of the nerve in case of neuropathies and compression of the suprascapular nerve by the ossified suprascapular ligament.

## 2. Materials and Methods

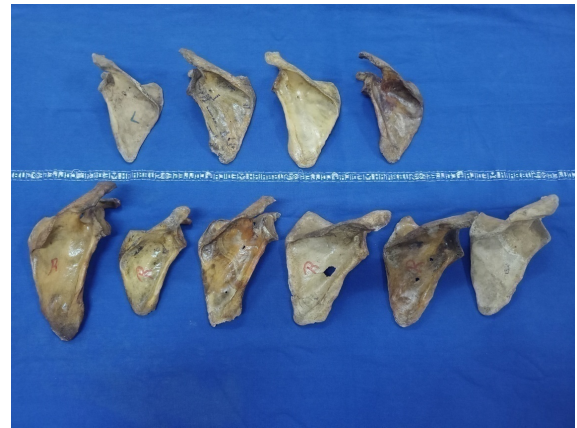The study was a gross anatomy – bone study done on the dry scapula bones collected from dept of Anatomy which was there for undergraduate students study.

The study was done between 2019 – 2021 over 3years, the study included 127 scapula bones,81 right scapulae

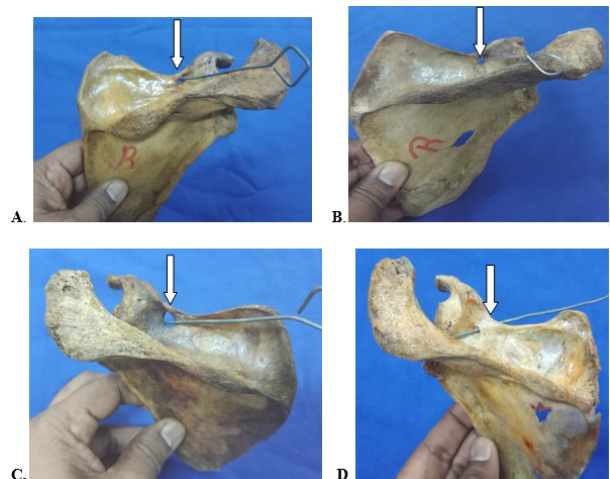
and 46 left sided scapulae of unknown sex. The broken & malformed scapulae were excluded from the study. The superior border of the scapula was carefully studied for the presence of the ossified transverse scapular ligament[TSL], presence of any other foramen in the suprascapular fossa, the findings were recorded accordingly and tabulated.

## 3. Results

Following are the results of the study done.



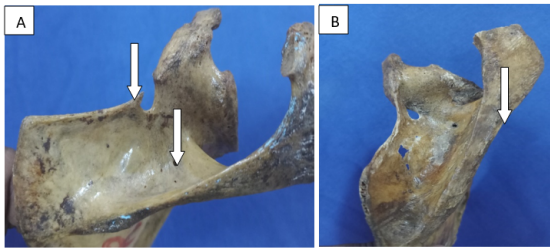
**Fig. 2:** Showing the scapulae with the ossified transverse scapular ligament [TSL] in them



**Fig. 3:** A. & B.: Show the ossified Suprascapular ligament on RIGHT side; C.& D: Show the ossified Suprascapular ligament on LEFT side

The number of specimens studied – 127 scapulae, out of which right sided scapulae were 81[n – 81] and left sided scapulae were 46 [n – 46].

1. Ossified transverse scapular ligament [TSL] was seen in 6 out of 81 right sided scapulae studied.(Figure 3)



**Fig. 4:** A & B) Showing the Accessory foramen in the supraspinous fossa. Also in fig (a) there is a small bony spike depicting the partially ossified transverse scapular ligament.[TSL]

2. In the left sided scapulae 4 out of 46 scapulae had ossified TSL.(Figure 3)
3. The results were tabulated and 10 out of 127 dried scapulae had ossified transverse scapular ligament ie 7.87% which was closely corresponding with the studies of other Indian workers on scapulae, as depicted in Table 2.
4. Accessory foramen were seen in supraspinous fossa in 3 out of 127 scapulae studied, partially ossified TSL was seen in 1 scapula. (Figure 4a)

A comparison was made regarding correlating the works of various authors on the ossification of TSL over the years. The list is tabulated in Table 2, which showed variation in the occurrence of the ossification of TSL based geographical differences, sample size and most of the studies had taken bones of unknown sex only the sides of the scapulae was taken into account which showed slight preponderance to right side, considering right handedness is common.

#### 4. Discussion

The study of the ossified transverse scapular ligament [TSL] has been studied by various workers and the results also are varied depending on the sample size as well as the propensity of occurrence of the variations in the samples collected in different areas. We shall go through the observations of various authors.

Various authors have classified the shape of suprascapular foramen based on its appearance into U shape, V shape & J shaped notches of scapula. Natsis et al<sup>13</sup> [2007] have described the V shaped suprascapular notch based on vertical and transverse diameters measured by them.

Rengachary & workers<sup>14</sup> [1979] have described 6 different types of suprascapular notches and opined that the suprascapular nerve entrapment is an acquired neuropathy secondary to the nature of work and occupation.

Type 1: lacks a discrete notch.

Type 2: is a wide Vshaped notch.

Type 3: is a wide Ushaped notch

Type 4: is a narrow Vshaped notch with partial ossification.

Type 5: is a narrow Ushaped notch with partial ossification.

Type 6: is a completely ossified suprascapular ligament converting the suprascapular notch into foramen.[ as seen in our study]

Knowing the course of the suprascapular nerve where its passing beneath the TSL at the superior border of the scapula, common cause of the nerve compression is by ossification of TSL, other reasons being direct trauma, fracture of scapula, ganglion cysts, lipomas of the back, occupation related straining as in manual labourers, stretch injuries & tumours as described by Paolo & workers.<sup>15</sup>

In a study by Thompson & workers<sup>16</sup> on peripheral entrapments neuropathies in upper extremity describes the variation in the ligament bridging the suprascapular notch may irritate the suprascapular nerve & give rise to pain which is deep & poorly localised, which is the reason why the cause of pain & tenderness is difficult study to discover in any individual and muscle atrophy starts. In one of the study by Natsis and workers<sup>13</sup> found narrowing of the suprascapular notch may be due to partial or complete calcification of TSL, presence of the bony ridge irritates or compresses the nerve giving rise to suprascapular nerve entrapment syndrome.

As described by Marcos Rassi and workers<sup>8</sup> in their study on suprascapular nerve block stated that the suprascapular block is an effective therapeutic method used by anaesthesiologists both for regional anaesthesia & postoperative analgesia of the surgeries on shoulder. They concluded that the suprascapular nerve block is an extremely effective procedure in the shoulder pain therapy, after arthroscopic procedures on the shoulder.

#### 5. Conclusion

The occurrences like ossification of TSL have different results in different studies done which is again varied depending on the samples collected in that particular area of the study. In our study the occurrence of ossification of TSL in adult scapulae was seen in accordance with earlier studies. The compression of suprascapular nerve by the ossified TSL can be one of the causes of neuropathy in the region of back.

Partial or complete ossification of the TSL should be kept in mind while evaluating the case of long standing poorly localised pain around the shoulder which could be associated with slight muscle atrophy. But the knowledge of such types of variations is essential to the anatomists while dissection as the findings are of academic significance. These facts are helpful for the surgeons, orthopaedicians who are operating in this area. Also the understanding of the course of the suprascapular nerve is necessary to the anaesthetists to give the nerve block as post operative

**Table 1:** Showing presence of Ossified Transverse scapular ligament [TSL]

Side of bone	Completely ossified TSL	Partially ossified TSL	Accessory foramen in supraspinous fossa
Right scapulae [n – 81]	06	01	02
Left scapulae [n – 46]	04	00	01
Total : 127 scapulae [Percentage]	10 [7.87%]	01	03

**Table 2:** Comparison of ossified suprascapular notch in other studies

S. No	Name of authors :	No of bones studied	Incidence of ossification of notch in scapula bone
1.	Ticker et al <sup>4</sup> [1998]	79	5%
2.	Dunkelgrun et al. <sup>9</sup> [2003]	623 623	7.3%
3.	Silva et al. <sup>10</sup> [2007]	221	30.76 %
4.	Sinkeet et al. <sup>11</sup> [2010]	138	2.9%
5.	Polguy et al <sup>12</sup> [2011]	86	7%
6.	Shiksha Jangde et al <sup>6</sup> [2015]	7 73	4.1%
7.	Sachin Patil et al <sup>7</sup> [2019]	118	3.54%
8.	Present study[2022]	12 127	7.87%

analgesia after the arthroscopic procedures on shoulder. It's useful for the radiologists to not confusing the ossified ligament for atypical bone growths or the tumour. A thorough knowledge of the nerve course and variations will help in the management of the neuropathies associated with it.

## 6. Source of Funding

Self.

## 7. Conflict of Interest

None.

## 8. Acknowledgement

I would like to thank Dr. Siri A.M. Professor of Anatomy for her help in preparing this article. I would like to thank Dr. Nagendra S. & our Dean for their support and guidance in doing this work. I would also thank the body donors who form the basis of the study.

## References

- Sahana SN. Human Anatomy (Descriptiv and Applied). vol. Vol 1. The National Book Depot; 1990. p. 351–7.
- Dutta AK. Essentials of Human Anatomy. vol. Vol 1. 3rd ed. Kolkata, India: Current Books International; 2004. p. 5–9.
- Standing S. The anatomical basis of Clinical Practice, Pectoral girdle, shoulder region and axilla. In: Gray's Anatomy. Churchill Livingstone; 2005. p. 819–22.
- Shishido H, Kikuchi S. Injury to the suprascapular nerve during shoulder joint surgery: an anatomical study. *J Shoulder Elbow Surg.* 2001;10(4):372–6.
- Ticker JB, Djurasovic M, Strautch RJ, April EW. The incidence of ganglion cysts and variations in anatomy along the course of suprascapular nerve. *J Shoulder Elbow Surg.* 1998;7(5):472–6.
- Jangde S, Arya RS, Paikra S, Basan K. Bony suprascapular foramen, a potential site for suprascapular nerve entrapment: a morphological study on dried human scapulae. *Intl J Anat Res.* 2015;3(3):1316–20.

- Patil S, Saluja S, Vasudeva N. Morphology of suprascapular notch and its clinical significance. *Intl J Anat Res.* 2019;7(2.1):6420–3.
- Fernandes MR, Barbosa MA, Sousa ALL, Ramos GC. Suprascapular nerve block: important procedure in clinical practice. *Rev Bras Anesthesiol.* 2012;62(1):96–104.
- Dunkelgrun M, Lesaka K, Park SS, Kummer FJ, Zuckerman JD. Interobserver reliability and intraobserver reproducibility in suprascapular notch typing. *Bull Hosp Jt Dis.* 2003;61(3-4):118–22.
- Silva JG, Abidu-Figueiredo M, Fernandes RMP, Rafael F, Sgrott EA, Silva SF, et al. High incidence of complete ossification of Superior transverse scapular ligament in Brazilians and its clinical implications. *Intl JMorphol.* 2007;25(4):855–9.
- Sinkeet SR, Awori KO, Odula PO, Ogengo JA, Mwachaka PM. The suprascapular notch: its morphology and distance from the glenoidal cavity in Kenyan population. *Folia Morphol (Warsz).* 2010;69(4):241–5.
- Polguy M, Jedrzejewski K, Podgórski M, Topol M. Morphometric study of suprascapular notch proposal of classification. *Surg Radiol Anat.* 2011;33(9):781–7.
- Natsis K, Trifon, Ioannis G, Konstantinos V, Efthymia P, Prokopios T. A bony bridge within the suprascapular notch. *Aristotle Univ Med J.* 2008;35(1):204–11.
- Rengachary SS, Burr D, Lucas S, Hassanien KM, Mohn MP, Matzke H. Suprascapular entrapment neuropathy: A clinical, anatomical and comparative study. *Part 2 Neurosurg.* 1979;5:447–51.
- Albino P, Carbone S, Candela V, Arceri V, Vestri AR, Gumina S. Morphometry of the suprascapular notch: Correlation with the scapular dimensions and clinical relevance. *BMC Musculoskelet Disord.* 2013;24(14):172.
- Thompson W, Koppell HP. Peripheral entrapment Neuropathies of the upper extremities. *N Engl J Med.* 1959;260:1261–5.

## Author biography

**Ravikumar V**, Professor and HOD

**Siri AM**, Professor

**Cite this article:** Ravikumar V, Siri AM. Study of suprascapular notch converted into a foramen in adult human scapulae in Karnataka region. *Indian J Clin Anat Physiol* 2022;9(2):137-140.