

Content available at: <https://www.ipinnovative.com/open-access-journals>

Indian Journal of Clinical Anatomy and Physiology

Journal homepage: <https://www.ijcap.org/>

Original Research Article

Morphometric analysis of infraorbital foramen in human dry skull of south Indian population and its clinical implications

Akshaya S^{1,*}, KR Dakshayani¹¹Dept. of Anatomy, Mysore Medical College and Research Institute, Mysore, Karnataka, India

ARTICLE INFO

Article history:

Received 02-12-2021

Accepted 03-02-2022

Available online 01-03-2022

Keywords:

Anterior nasal spine (ANS)

Infraorbital foramen (IOF)

Infraorbital margin (IOM)

Infraorbital nerve (ION)

Pyriform aperture (PA)

ABSTRACT

Background: Infraorbital foramen, an important anatomical landmark in anaesthetic and surgical interventions of the maxillary region, transmits the infra orbital vessels and nerve. Infraorbital nerve block is commonly used in regional anaesthesia for the midface and paranasal surgeries. The purpose of our study to obtain detailed knowledge of the anatomical location and variations of IOF which is imminent for successful regional anaesthesia and endoscopic surgeries of the maxillary region.

Materials and Methods: The study was conducted on 50 Human skull bones of unknown gender from the Department of Anatomy, Mysore Medical College and Research Institute, Mysore. Both side of skulls were visually observed for shape, direction of the infraorbital foramen and presence of accessory infraorbital foramina. 1. Sagittal Distance between the infraorbital margin to upper margin of infraorbital foramen were measured. 2. Transverse diameter from lateral margin of pyriform aperture to medial margin of IOF were measured. 3. Oblique distance from anterior nasal spine to inferior margin of IOF, were measured. 4. Vertical and transverse diameter of the IOF were measured.

Results: 50 skulls (100 sides – both right and left) were studied.

Most commonly observed shape of IOF is semilunar 36% on right side, 40% on left side, transversely oval 20% on right side, 28% on left side, vertically oval 18% on right side, 12% on left side, circular 18% on right side, 8% on left side, triangular 8% on right side 12% on left side. Direction of IOF is 88% medially downwards, 12% downwards.

The mean distance between IOM and IOF is 6.58±0.28 mm on the right side, 6.78 +0.233 mm on the left side. The mean distance between pyriform aperture to of IOF 16.88+3.7mm on the right side 16.46 +2.7 on the left side. The mean distance between ANS to inferior margin IOF on the 34.77+0.55 mm on right side 34.22+0.3 mm on the left side.

Mean vertical diameter of IOF 3.76 mm on right side & 3.94 mm on left side. Mean transverse diameter of IOF 4.18 mm on right side & 4.32+15 mm on left side.

Accessory IOF were present in 6% of skulls bilaterally.

Conclusion: Our study results will be of immense help to the surgeons and anaesthetists, handling this region for operative procedures.

This is an Open Access (OA) journal, and articles are distributed under the terms of the [Creative Commons Attribution-NonCommercial-ShareAlike 4.0 License](https://creativecommons.org/licenses/by-nc-sa/4.0/), which allows others to remix, tweak, and build upon the work non-commercially, as long as appropriate credit is given and the new creations are licensed under the identical terms.

For reprints contact: reprint@ipinnovative.com

1. Introduction

Infraorbital foramen is located in the maxilla of the skull bone. The skull is the most complex bony structure in the

body. It consists of cranium, facial skeleton, mandible. The visero cranium (facial skeleton) hangs down from the front of neurocranium (calvaria and basi cranium) and houses the organ of sight, smell, taste as well as openings to the respiratory and digestive systems via nose and mouth respectively. The Upper part of the face is occupied by

* Corresponding author.

E-mail address: drkannanfiles@gmail.com (Akshaya S).

the orbit and the bridge of the nose. Each orbital opening is roughly quadrangular in shape. The, upper, supraorbital margin is formed entirely by the frontal bone.

Infraorbital margin is formed by zygomatic bone laterally and maxilla medially. Infraorbital margins are sharp and palpable. The anterior nasal aperture is pyriform in shape, wider below than the above. The upper boundary of aperture is formed by nasal bone while the remainder is formed by maxillae. The anterior nasal spine marks the upper limit of the inter maxillary suture at the lower margin of anterior nasal aperture and is palpable in the nasal septum.

The infraorbital foramen transmits the infra orbital vessels and nerve, and lies about 1cm below the middle of the infraorbital margin in maxillary bone. It commonly aligns with a vertical axis passing through maxillary tooth 5 and sits an average of 2.5 cm from the midline face with difference noted between genders and side. The infra orbital nerve, the continuation of maxillary division of trigeminal nerve, is a sensory nerve. It supplies skin of the lower eye lid, skin of the side of nose, movable part of nasal septum, skin of anterior part of cheek and upper lip. The branches of the infraorbital nerve joined from the branches of the facial nerve to form the infraorbital plexus. The infraorbital nerve is commonly implicated in trigeminal neuralgia and amenable to cryotherapy when medical therapy fails.¹

IOF is an important anatomical landmark in anaesthetic and surgical interventions of the maxillary region. Infraorbital nerve block is commonly used in regional anaesthesia for the midface and paranasal surgeries. The infraorbital nerve is the nerve of choice for regional nerve block when performing surgeries in the, buccal and nasal and orbital areas. The infraorbital nerve block is performed by reaching the nerve through an intra oral or an extraoral route.² When the site of infraorbital foramen is found, the needle can be advanced either through the skin directly toward the infraorbital foramen or through the mouth at the level of incisor at alveolar buccal margin in the subulcal plane. This implies the clinical importance of surgical location and anatomical variations of this region. The surgeries performed around infraorbital foramen that is orbital floor and midface surgeries, involves like orthognathic surgeries for correction of maxillary arch discrepancies and management of Le fort-II fractures and cald well -luc operation done for begin diseases that affects maxillary sinus such as chronic sinusitis, fungal sinusitis, polyposis, biopsy, internal maxillary artery ligation for epistaxis, oroantral fistulas and dental procedures.³ Hence, the detailed knowledge of the anatomical location and variations of Infra orbital foramen are necessary for the successful regional anaesthesia and for the conventional and endoscopic surgeries of the maxillary region.

2. Materials and Methods

The study was conducted on 50 Human skull bones of unknown gender from the Department of Anatomy Mysore Medical College and Research Institute, Mysore. Human adult skull bones without any deformity were included in the study. The study was approved by institutional ethics committee, Mysore Medical college and research institute, Mysore(number EC REG:ECR/134/Inst/KA/2013/RR-19). Foetal skulls and skulls with facial fractures were excluded from the study. Both side of skulls were visually observed for shape, direction of the infraorbital foramen and presence of accessory infraorbital foramina.⁴ The study was conducted in the months of August, September, October, November(4 months), year 2021.

1. Sagittal Distance between the infraorbital margin to upper margin of infraorbital foramen were measured.
2. Transverse diameter from lateral margin of pyriform aperture to medial margin of IOF were measured. {Fig no 4}
3. Oblique distance from anterior nasal spine to inferior margin of IOF, were measured.(Figure 3)
4. Vertical and transverse diameter of the IOF were measured.⁵

All the measurements were done on both side of the skull by using sliding vernier calliper{lab world} with the accuracy of 0.1 mm. Software used is SPSS (Trial Version)-23.

3. Results

50 skulls (100 sides – both right and left were studied).

Most commonly observed shape of IOF is semilunar 36% on right side, 40% on left side, transversely oval 20% on right side, 28% on left side, vertically oval 18% on right side, 12% on left side, circular 18 on right side, 8% on left side, triangular 8% on right side 12% on left side.(Figures 2, 5, 6 and 8) Direction of IOF is 88% medially downwards, 12% downwards.(Figures 1 and 8)

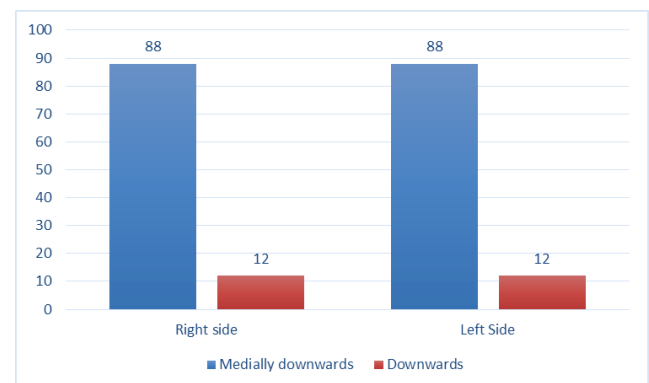


Fig. 1: Direction of infraorbital foramen

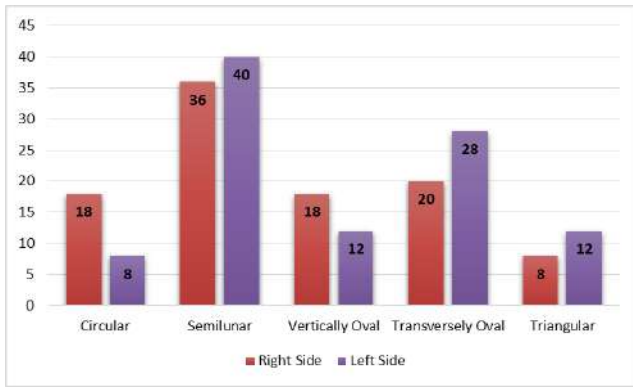


Fig. 2: Shape of infraorbital foramen

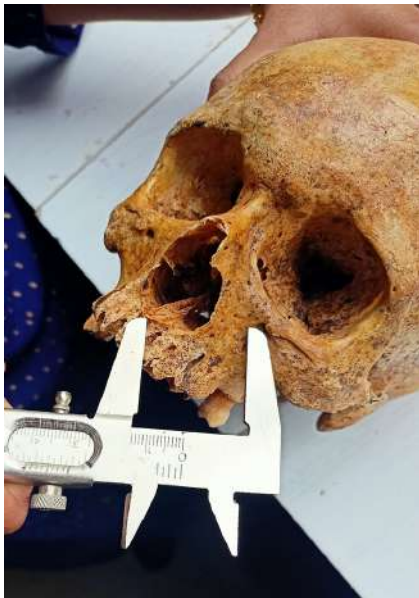

Fig. 3: Measurement of distance from anterior nasal spine to infraorbital foramen using vernier caliper

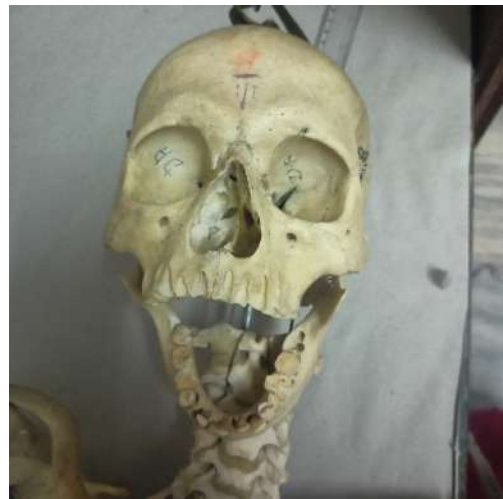

Fig. 5: Shape of IOF : Right – Triangular, Left - Semilunar

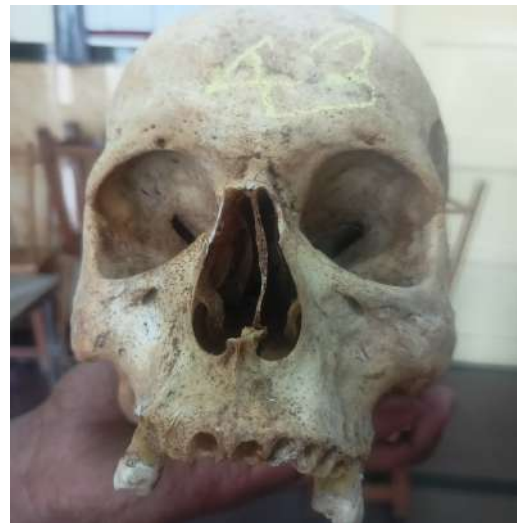

Fig. 6: Right side – Vertically oval, Left side – Transversely oval

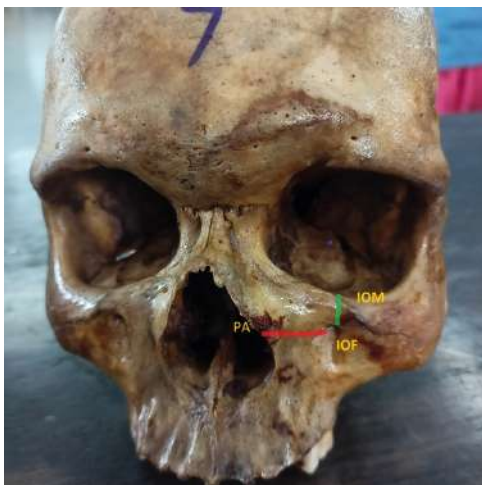

Fig. 4: Measurement of distance from Pyriform aperture (PA) and infraorbital margin to infraorbital foramen

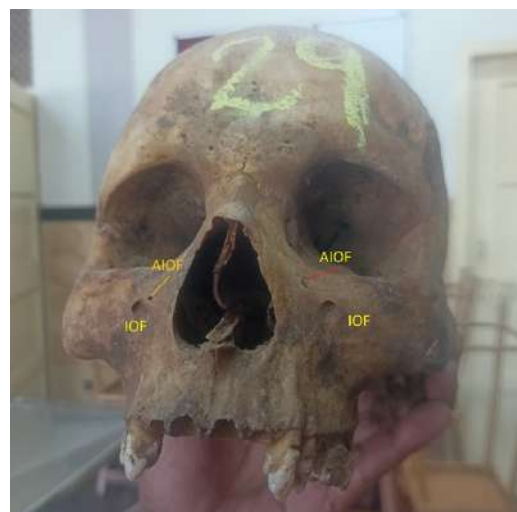

Fig. 7: Bilateral accessory foramen

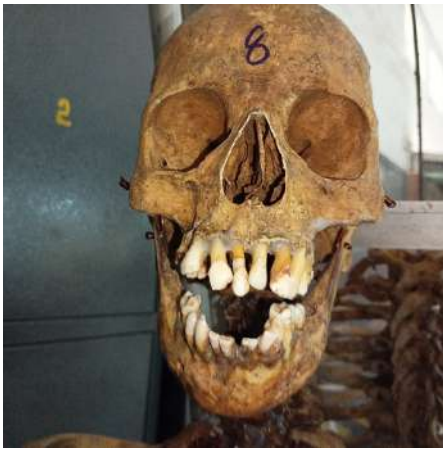

Fig. 8: Right side IOF direction – Medially downwards, Left side IOF shape - Triangular

The mean distance between superior margin of IOM and IOF is 6.58 ± 0.28 mm on the right side & 6.78 ± 0.233 mm on the left side. Maximum distance between superior margin of IOM to IOF 1.8 mm on the right side 1.8 mm on the left side (both on same skull). Minimum distance between IOM TO IOF 3 mm on the right side & 3 mm on the left side (on different skull).

The mean distance between pyriform aperture to medial margin of IOF 16.88 ± 3.7 mm on the right side & 16.46 ± 2.7 mm on the left side. The maximum distance between pyriform aperture to medial margin of IOF 27 mm on the right side & 23 mm on the left side. The minimum distance between pyriform aperture to medial margin of IOF 13 mm on the right side & 12 mm on the left side.

The mean distance between ANS to inferior margin of IOF 34.22 ± 0.55 mm on right side & 34.77 ± 0.3 mm on left side.

Mean vertical diameter of IOF 3.76 mm on right side & 3.94 mm on left side. Minimum vertical diameter of IOF is 2 mm on both sides. Maximum vertical diameter of IOF is 7 mm on both sides.

Mean transverse diameter of IOF 4.18 mm on right side & 4.32 ± 15 mm on the left side. Minimum transverse diameter on right side is 3 mm & 2 mm on left side. Maximum transverse diameter 5 mm on right side & 7 mm on left side.

Accessory IOF were present in 6% of skulls bilaterally. They lie medial to the IOF with mean distance between them as 5 mm on right side & 3 mm on left side. (Figure 7), (Tables 1 and 2)

4. Discussion

Infraorbital nerve (ION) is one of the important nerves of facial skeleton which is commonly used for local anaesthetic block during maxillofacial surgeries, dental procedures, maxillary sinus exploration and endoscopic surgeries involving zygomatic-maxillary region. Any inadvertent

injury to the Infra orbital nerve will result in neurological disturbances involving lower lid, lateral side of nose, upper lip affecting the day-to-day activities of the patients. Because of its utmost importance plastic and ENT surgeons try to preserve this nerve during maxillofacial surgeries for which knowledge of the exact location of IOF with reference to the nearby anatomical landmarks is mandatory for the expert surgeons & anaesthetists.

Our study tried to explore the exact location and anatomical variations of IOF with reference to the nearby anatomical landmarks by measuring the distance between Infraorbital foramen, and Infraorbital margin, Pyriform aperture, Anterior nasal spine.

Vertical diameter and transverse diameter of IOF were also measured. Because larger or smaller dimensions may indicate the size of infraorbital nerve and vessels may need increase or decrease the dose of local anaesthetic drugs. Shape and direction of IOF were also recorded to give a clear vision to the surgeons.

Regarding the distance between the IOM & IOF mean distance of 6.58 mm on R side, 6.78 mm on left side is similar to Zuberi et al.⁴ Rajeshwari et al⁷ and Bahath et al¹⁰ found the lesser dimensions than us. Maoori⁹ and Veeramuthu⁸ found larger dimensions than us. Nayanakara et al⁶ found that IOF is located closer to the IOM on the right compared to the left. Furthermore, the left side IOF had larger dimensions than the right IOF. This right n left side differences are observed in our study too. A similar statistically significant difference was observed in the distance from the infraorbital foramen to infraorbital margin that infraorbital foramen is located closer to infraorbital margin in right than left side implying accurate measurements were taken in our study. (Table 3)

Regarding distance between IOF and pyriform aperture our study measurements are similar with Veeramuthu et al⁸ and Masoori et al.⁹ Rajeshwari et al found lesser values than us. (Table 5)

Distance between ANS and IOF, previous all studies showed mean distance of 33 to 34 mm on both sides, goes same measurements with our study too with mean of 34.7 mm right side, 34.2 mm left side help in exact identification of location of IOF during clinical procedures. (Table 4)

Mean Vertical diameter of IOF observed mean of 3.76 mm on right side 3.94 mm on left side, another proof of larger dimensions on left side goes similar with Zuberi et al⁵ and Nayanakara⁶ et al. (Table 6)

Transverse diameter OF IOF 4.18 mm on right side 4.320 mm on left side, indicating larger measurements on left side. (Table 7)

Accessory foramen is present in 6% of skulls. All were bilaterally present. (Table 1). Previous studies results show different percentage of presence of AIOF in various ethnic groups.

Table 1: Number of accessory infraorbital foramen

	Right	Left
Single Infraorbital Foramen	50	50
Accessory Infraorbital Foramen	3	3
	50	50

Table 2: Mean distance between accessory infraorbital foramen and nearby anatomical landmarks

Infra orbital accessory foramen Mean	foramen-infraorbital	Infraorbital margin – Accessory infraorbital foramen Mean		Pyriform aperture – Accessory infraorbital foramen Mean		Anterior nasal spine – Accessory infraorbital foramen Mean	
		Right side	Left side	Right side	Left side	Right side	Left side
5 mm	3 mm	3 mm	3mm	18 mm	19 mm	35mm	34 mm

Table 3: Distance between infraorbital margin to infraorbital foramen

Study	No of specimen (bones) studied	Infraorbital Margin – Infraorbital Foramen						Mean standard deviation
		Right side			Left side			
Author, Place and year of the study		Minimum	Maximum	Mean standard deviation	Minimum	Maximum		
Nayanakara et al, ⁶ Sri lanka , 2016	50	3.28 mm	15.47 mm	6.52 ± 2.03 mm	3.mm	11.53mm	7.30 ± 1.57mm	
Zuberi et al ⁵ , Maharashtra, 2016	43	-	-	6.75+1.76mm	-	-	6.95*+1.68mm	
Rajeshwari et al, ⁷ Coimbatore, Tamil Nadu 2016.	52	2.5mm	6mm	3.62mm			3.8 mm	
Veeramurthu et al ⁸ , Tamil nadu 2016	105	5mm	13mm	7.22+1.64mm	4mm	11mm	6.78+1.64mm	
Masooma Begam Shiny Vinila ⁹ Telungana 2019	52	-	-	7.31+1.54 mm	-	-	7.27+1.43mm	
Bahath ¹⁰ , Mysore, Karnataka 2019	14	3.29mm	7.59mm	5.49+1.1mm	4.51mm	8.56mm	5.85+1.06mm	
Ananya et al, ¹¹ Chennai, Tamil nadu 2019	50	-	-	9.704 mm	-	-	1.0004 mm	
Present Study, Myore, Karnataka 2021	50	3mm	1.8mm	6.58+ 2.8mm	4mm	1.8mm	6.78 +2.33mm	

Table 4: Distance between pyriform aperture to infraorbital foramen

Author, Place, Year of the study	No of specimen studied	Anterior Nasal Spine To Infraorbital Foramen					
		Right side			Left side		
		Minimum	Maximum	Mean standard deviation	Minimum	Maximum	Mean standard deviation
Nayanakara et al, Sri lanka, 2016	50	25.35mm	40.47 mm	33.81 ± 2.68 Mm	23.99mm	39.75mm	34.23 ± 2.56mm
Zuberi et al, ⁴ Maharashtra, 2016	43	-	-	33.35+3.25 Mm	-	-	33.23+3.75mm
Veeramurthu et al, ⁸ Tamil nadu 2016	105	26mm	40mm	32.62+3.4mm	27mm	38mm	33.52+3.37mm
Bagath et al, ¹⁰ Mysore, 2019	14	28.47mm	37.99 mm	33.62+2.22 Mm	29.18 Mm	35.92 Mm	33.13+2.30mm
Masooma Shiny vinila et al, ⁹ Mysore, 2019	52	-	-	32.46+2.55	-	-	31.70+2.36mm
Present Study, Mysore 2021	50	30mm	40mm	30.422+5.5mm	20.7 mm	40mm	30.47 +3 mm

Table 5: Distance between pyriform aperture to infraorbital foramen

Author, place, Year of the study	No of specimen (bones)studied	Pyriform aperture to infraorbital foramen					
		Right Side			Left side		
		Minimum	Maximum	Mean with Standard Deviation	Minimum	Maximum	MEAN with Standard deviation
Zubeir et al, ⁴ Maharashtra, 2016	43	-	-	18.50+2.52mm	-	-	18.30+2.35mm
Rajeshwari et al, ⁷ Tamil nadu, 2016	52	11mm	16mm	7.451 mm	-	-	7.865 mm
Veeramurthu et al, ⁸ Tamil nadu 2016	105	13mm	23mm	17.8+2.94mm	11mm	23mm	17.2+2.75mm
Masooma et al, ⁹ Mysore, 2019	52	-	-	16.57 +1.90mm	-	-	16.13 mm
Present Study, Mysore 2021	50	1.3mm	2.7mm	1.688+0.37mm	1.2mm	2.3mm	1.646+0.27

Berry and Berry¹² documented 4.7% in Egyptians, 6.4% in Nigerians, 6.4% in Palestinians, 6.7% in Indians, 6% in North Americans, 13.2% in South Americans.

Accessory branch of infraorbital nerve passes via the AIOF implies exact site of AIOF to be known to take the adequate precautions prior to any surgical intervention of this region to preserve the accessory infraorbital nerve. The knowledge of anatomical location and number of accessory foramen is mandatory, to give adequate dosage anaesthetic agents to block the accessory branches of infraorbital nerve, during of midfacies, maxillary and or orbital floor surgical procedures.⁴

In our study AIOF is 6% close proximity with Indian values as reported by Beri and Beri. In our study AIOF is Circular in shape, lies medial to IOF, and distance between them with mean of 4mm on the right side, 3 mm on the left side in all skulls. (Table 2) Tezer et al¹³ observed in their study 93.3% of AIOF lies superomedial to IOF and 6.7% lies inferomedial to IOF.

5. Conclusion

Here we are concluding with, observations obtained by our study showing morphometry of various shape, size

Table 6: Vertical diameter of infraorbital foramen

Study		Vertical diameter					
		Right			Left		
		MIN	MAX	MEAN SD	MIN	MAX	MEAN SD
Nayanakara et al, Sri Lanka, 2016	50	1.46 mm	3.78mm	3.11±0.61mm	2.42mm	4.16mm	3.31±0.55mm
Masooma, Vinila et al, ⁹ Mysore, 2019	52	NA	NA	3.57+0.85mm	NA	NA	3.18+0.83mm
Veeramurthu et al, ⁸ Tamil nadu 2016	105	2mm	8mm	3.88+1.17mm	2mm	6mm	3.68+0.89mm
Bagath et Al, ¹⁰ Mysore, 2019	14	2.23mm	5.02mm	3.95+0.86mm	2.08mm	5.39mm	3.82+0.83mm
Ananya et al ¹¹ Chennai, 2019	50	NA	NA	4.1 +0.52mm	NA	NA	NA
Present Study, Mysore, Karnataka, 2021	50	2mm	7mm	3.76,+0.13	2mm	7mm	3.94 +0.13

Table 7: Transverse diameter of infraorbital foramen

Author, place and year of the study	Number of specimen studied	Transverse Diameter					
		Right side			Left side		
		MIN	MAX	MEAN SD	MIN	MAX	MEAN SD
Nayanakara et al, Sri Lanka, 2016	50	2.10mm	4.17mm	3.27 ± 0.58mm	2.55mm	4.47mm	3.33±0.59mm
Masooma et al, Mysore, 2019	52	NA	NA	2.88+0.62mm	NA	NA	2.98+0.59mm
Veeramurthu et al, ⁸ Tamil nadu 2016	105	2mm	10mm	3.82+1.58mm	2mm	10mm	3.92+1.46mm
Bagath et al, ¹⁰ Mysore, 2019	14	0.8mm	5.02mm	3.70mm	2.11mm	6.91mm	3.70+1.20mm
Ananya et al, ¹¹ Chennai, 2019	50	-	-	4.9+0.56	-	-	-
Present Study, Mysore, Karnataka 2021	50	3mm	5mm	4.18,+1.2	2mm	7mm	4.32 +1.5mm

direction and exact location of IOF with nearby anatomical landmarks are at close proximity with the results obtained by various authors studied the infraorbital region in same and different geographical population. Minor differences in results noted were may due to ethnic and racial variations. So, the results of our study are another strong evidence of presence of anatomical variations (like accessory infraorbital foramen) in this region that will surely a great guide for general surgeons, ENT professionals, Plastic surgeons, Anaesthetists and dentists operating this region.

6. Source of Funding

None.

7. Conflict of Interest

None.

References

1. Standring S. Gray S anatomy. The anatomical basis of clinical practice. 41st ed. London, United Kingdom: Elsevier Churchill Livingstone; 2015. p. 414–6.
2. Mohammad A, Fatah A. Computed tomographic localisation of infraorbital foramen position and correlation with age and gender of Iraq subjects. *J Baghdad Coll Dent.* 2013;25(Special Issue 1):30–5.
3. Fabiano B, Maria M, Jose A, Roberto J, Salomao P, Richardo F. The Foramen and Infraorbital nerve related to the surgery for external access to the maxillary sinus(caldwell-luc). *Int Arch Otorhinolaryngol.* 2018;12(3):342–6.
4. Nanayakkara D, Peiris R, Mannapperuma N, Vadysinghe A. Morphometric Analysis of the Infraorbital Foramen: The Clinical Relevance. *Anat Res Int.* 2016;2016:7917343. doi:10.1155/2016/7917343.
5. Riyaz ZH, Moizuddin K, Siddiqui A. Morphometric analysis of Infraorbital foramen in human skulls. *Indian J Anat Surg Head Neck Brain.* 2016;2(2):45–8.
6. Nayanakara D, Peiris R, Navini M, Vadysinghe A. Morphometric analysis of the Infraorbital foramen: The clinical relevance. *Anat Res Int.* 2016;2016(11):7917343.
7. Rajeshwari K, Rohinidevi M, Vimala V, Megala D. Morphometric analysis of Infraorbital foramen in human dry skulls. *Int J Anat Res.*

- 2016;4(3):2725–9.
8. Veeramuthu M, Varman R, Shalini, Manoranjitham. Morphometric analysis of infraorbital foramen and incidence of Accessory foramen and its clinical implications in dry adult human skull. *Int J Anat Res.* 2016;4(4):2993–3000.
 9. Begum M, Vinila BHS. Morphometric Analysis of Infraorbital Foramen in the Telangana Population. *Acad Anatomica Int.* 2019;5(2):90–4.
 10. Potu BK, Srungvarapu GC, Pulakunta T. Morphometric evaluation of the infraorbital foramen in human dry skulls of south Indian population. *Ital J Anat Embryol.* 2019;124(3):382–91.
 11. Ananya B, Sangeetha S, Premavathy D. Morphometric study of infraorbital foramen in local anesthesia. *Drug Invention Today.* 2019;12(6):1247–9.
 12. Berry AC, Berry RJ. Epigenetic variations in the human cranium. *J Anat.* 1967;101(Pt 2):361–79.
 13. Tezer M, Ozturk A, Akgul M, Gayretlio O, Kale A. Anatomic and morphometric features of the accessory infraorbital foramen. *J Morphol Sci.* 2011;28(2):95–7.

Author biography

Akshaya S, Senior Resident

KR Dakshayani, Professor and Head

Cite this article: Akshaya S, KR Dakshayani. Morphometric analysis of infraorbital foramen in human dry skull of south Indian population and its clinical implications. *Indian J Clin Anat Physiol* 2022;9(1):54-61.