

Content available at: <https://www.ipinnovative.com/open-access-journals>

Indian Journal of Clinical Anatomy and Physiology

Journal homepage: <https://www.ijcap.org/>

## Original Research Article

# Morphological variation in the insertion of the brachialis and its relations to the neurovascular structures of the arm

Suganitha Balasundaram <sup>1,\*</sup>

<sup>1</sup>Dept. of Anatomy, Bangalore Medical College & Research Institute, Bengaluru, Karnataka, India



### ARTICLE INFO

#### Article history:

Received 28-01-2022

Accepted 02-02-2022

Available online 01-03-2022

#### Keywords:

Anatomical variations

Brachialis tunnel

Entrapment syndrome

Median nerve

### ABSTRACT

Variations in origin and insertion of muscles are common in the upper limb. They may or may not be associated with neuromuscular abnormalities. The Brachialis muscle is inserted into the anterior aspect of the coronoid process and the tuberosity of ulna. The median & the Brachial artery passes vertically downward between biceps brachii (above) & brachialis (below) in the lower part of the arm and enter the cubital fossa. This study was conducted in 40 embalmed adult upper limbs of both sexes of age group between 50-80 years from the Department of Anatomy, Kilpauk Medical College, Chennai. In this study, an Intramuscular tunnel is formed by brachialis muscle was observed in 2.5% of the specimen in which entrapment of brachial artery & median nerve was present. The Abnormality reported in the present study may lead to neurovascular compression syndrome in the upper limb. knowledge of anatomical variations in the muscular structure and its neurovascular entrapment is important surgically for orthopaedic surgeons, cardiovascular surgeons, plastic surgeons and also physiotherapist clinically.

This is an Open Access (OA) journal, and articles are distributed under the terms of the [Creative Commons Attribution-NonCommercial-ShareAlike 4.0 License](https://creativecommons.org/licenses/by-nc-sa/4.0/), which allows others to remix, tweak, and build upon the work non-commercially, as long as appropriate credit is given and the new creations are licensed under the identical terms.

For reprints contact: [reprint@ipinnovative.com](mailto:reprint@ipinnovative.com)

## 1. Introduction

The Brachialis muscle shows several interesting morphological & anatomical characteristics. It arises from the front and lower half of the shaft of humerus. The Brachialis muscle is inserted into the anterior aspect of the coronoid process and the tuberosity of ulna. The median nerve and brachial artery related superficial to the brachialis and then enters the cubital fossa.<sup>1,2</sup>

The brachial artery is a continuation of the axillary artery and it is superficial throughout its course in the arm along with the median nerve. The median nerve is formed by its medial and lateral root coming from medial and lateral cords of brachial plexus respectively. It descends laterally till the middle of the arm. Then it crosses the brachial artery from lateral to medial near the insertion of coracobrachialis and enters the cubital fossa by passing between the Brachialis

below and the biceps brachii above.

Knowledge of anatomical variations in the muscular structure and its related neurovascular entrapment is important surgically for orthopaedic surgeons, plastic surgeons and also physiotherapist clinically, hence the present study was done to observe the insertion of brachialis and course of the Median nerve and the Brachial artery related to it.

## 2. Materials and Methods

The study was conducted on 40 upper limbs from embalmed cadavers from the Department of Anatomy, KMC, Chennai. A longitudinal incision was made in the anterior surface of brachial fascia from the level of pectoralis major to the elbow. The limbs were routinely dissected for observing the insertion of Brachialis and its relation to the neurovascular structures in the arm. The course of the median nerve and brachial artery were observed. The photograph of the

\* Corresponding author.

E-mail address: [nithakeyan@gmail.com](mailto:nithakeyan@gmail.com) (S. Balasundaram).

variations is taken for proper documentation and ready reference.

### 3. Results

In 39 specimens (97.5%), the Brachialis muscle is inserted into the anterior aspect of the coronoid process and the tuberosity of ulna. The Median nerve and the Brachial artery passes superficial to the brachialis muscles and the relationship was normal.

In one specimen (2.5%) a tunnel was formed by brachialis muscles in the lower 1/3 of right upper limbs. The length of the tunnel was measured about 2.5 cm. It was unilateral whereas in the left arm of the same cadaver, it was normal. Entrapment of the Brachial artery and the Median was observed in this case with in the tunnel of the brachialis.

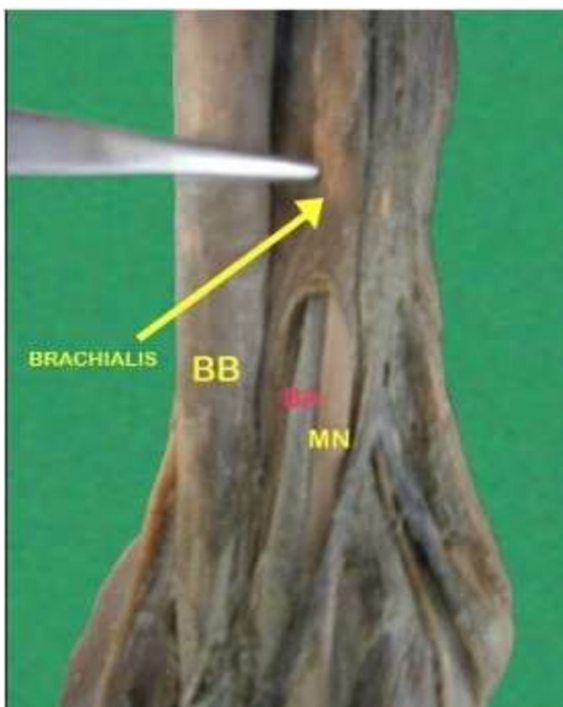


Fig. 1:

### 4. Discussion

Many authors have quoted that the brachialis muscle fibre/slips have been seen as superficial to the neurovascular bundle in the arm. A recent study quoted that the brachialis muscle is formed a 2.5 cm length tunnel for the passage of neurovascular bundle in the arm which is very unusual.<sup>2-4</sup>

There are three well-defined entrapment syndromes involving the median nerve its branches namely carpal tunnel syndrome, Pronator teres syndrome and anterior interosseous syndrome. A few case report were found in the literature revealed that the possible Median nerve

entrapment due to third head of biceps brachii.<sup>5,6</sup> Even though anatomy literature hardly mentions that the Median nerve compression is due to bicipital aponeurosis, a few researches says that it could be a case of high median nerve compression along with the brachial artery.<sup>6</sup>

Few types of researches stated that, a rare sub-brachialis course of the Median nerve & Brachial artery in the arm, whereas, the entire course of the Median nerve and the Brachial artery was deep to the brachialis muscle. But near the cubital fossa it returned to its normal course and appeared as the most medial content of the cubital fossa.<sup>7,8</sup>

This variation has all possibilities by entrapment neuropathy since the Median nerve and the Brachial artery were found compressed under the Musculo-fascial structure which had an unyielding nature. Hence, we assume that the clinical indications possibly presented in such entrapment might be similar to that pronator syndrome. But in advance stages compression could lead to endothelial damage & Thrombotic occlusion of the Brachial artery. Clinically these kinds of tunnel will produce symptoms in the forearm & hand also.<sup>9</sup>

In the present study, the tunnel was formed by the Brachialis muscle which arose from the superficial fibre with its aponeurosis 2.5cm in length, extending downward and overlapping the median nerve and brachial artery to get inserted into the medial intermuscular septum. The clinical implications of the slips of brachialis is that it has the potential to cause the Median nerve entrapment & Brachial artery compression.

The Brachialis muscle is reported in this case may be explained on the basis of the embryogenesis of the muscles of the arm. During development of the limb bud, the Brachialis muscle develops from the fusion of two muscular primordial. Most of it is formed from the ventral or flexor pre muscular mass (which is supplied by the ventral rami of spinal nerves) and a part of it is formed from dorsal or extensor pre muscular mass (which is supplied by the dorsal rami of spinal nerves). Some authors state that Brachialis arises only from the ventral pre muscular mass and the branch of Radial nerve which supplies it, is derived from anterior division of Brachial plexus which uses Radial nerve only as route to Brachialis muscle by unknown mechanisms. However this view has no reliable evidence. The extensor pre muscular mass in the forearm differentiates into three parts.<sup>10</sup> Thereafter, some muscle primordia will disappear through cell death called apoptosis. The variation in the present study may be due to failure of muscle primordia to disappear during embryological development.<sup>11</sup>

Therefore, the knowledge about this kind of rare variations are important for surgeons to avoid mislead diagnosis and treatment.

### 5. Source of Funding

None.

## 6. Conflict of Interest

The authors declare no conflict of interest.

## Acknowledgments

My sincere thanks to Dr. Preeti Ramya, Dr. Saradha Kadhiresan, my friend Dr. J. Latha for their valuable help and support.

## References

1. Gray H. Textbook of Anatomy; 1858.
2. Woodburne, Russell T, (Author). Essentials of Human Anatomy. 2nd ed. United Kingdom: Oxford U Press; 1961.
3. Jayakumar VR, Bajpe R, Shubha R. Variation in the Insertion of Brachialis Muscle- A Case Report. *Int J Sci Res*. 2013;3(2):172–5.
4. Mehta V, Suri RK, Arora J, Kumar H, Yadav Y, Rath G. Crucial neurovascular structure entrapped in a brachial intramuscular tunnel. *Rom J Morphol Embryol*. 2010;51(1):199–201.
5. Dharap AS. An anomalous muscle in the distal half of the arm. *Surg Radiol Anat*. 1994;16(1):97–9.
6. El-Nagger M, Al-Saggaf S. Variant of the coracobrachialis muscle and its relationships with the musculocutaneous nerve. *Folia Morphol (Warsz)*. 2001;60:217–24.
7. Melanie RD, Anitha G, Naveen K, Satheesha BN. Sub-Brachialis Course of the Median Nerve in the Arm and its Possible Clinical Complications: A Case Report. *J Surg Acad*. 2012;2:52–5.
8. Kumar N, Padur AA, Prabhu G, Shanthakumar SR, Bhaskar R. Rare case of median nerve and brachial artery entrapment by an abnormal musculofascial tunnel in the arm: A possible cause of neurovascular compression syndrome. *Anat Cell Biol*. 2019;52(1):84.
9. Meda N, Verma H, Tripathi RK. Ischemic brachial artery entrapment syndrome by supracondylar humeral bony spur. *J Vasc Surg Cases*. 2015;1(2):116–9.
10. Tan ST, Smith PJ. Anomalous extensor muscles of the hand: a review. *J Hand Surg Am*. 1999;24(3):449–55.
11. Lewis WH. vol. Vol 2. Keibel F, Mall FP, editors. Philadelphia: JB Lippincott; 1910. p. 455–522.

## Author biography

**Suganitha Balasundaram**, Tutor  <https://orcid.org/0000-0003-3604-493X>

**Cite this article:** Balasundaram S. Morphological variation in the insertion of the brachialis and its relations to the neurovascular structures of the arm. *Indian J Clin Anat Physiol* 2022;9(1):13-15.