

Content available at: <https://www.ipinnovative.com/open-access-journals>

Indian Journal of Clinical Anatomy and Physiology

Journal homepage: <https://www.ijcap.org/>

## Original Research Article

# Topography of the location of mental foramen in dried edentulous human mandible and its clinical implication

Boski Gupta<sup>1</sup>, Bhadreshkumar P Vaghela<sup>2,\*</sup>, Sudarshan Gupta<sup>3</sup><sup>1</sup>Dept. of Prosthodontics, Daswani Dental College and Research Centre, Kota, Rajasthan, India<sup>2</sup>Dept. of Anatomy, NAMO Medical Education & Research Institute, Silvassa, Dadra Nagar Haveli, India<sup>3</sup>Dept. of Anatomy, GMERS Medical College, Gandhinagar, Gujarat, India

## ARTICLE INFO

## Article history:

Received 01-12-2021

Accepted 12-10-2021

Available online 07-12-2021

## Keywords:

Dental implants

Mandible

Mental foramen

Mental nerves

## ABSTRACT

**Introduction:** The mental foramen is an oval or round opening on external surface of mandible and transmits mental nerve and vessels. Mostly located at apex of second mandibular premolar or between the apices of premolars.

**Materials and Methods:** The study was commenced on 60 dried edentulous mandibles with the aim to determine location of mental foramen(MF) with reference to surrounding anatomical landmarks. By measuring its distance from midline (symphysis menti), posterior border of ramus of mandible, lower border of mandible. Length of lower border (Base) of mandible was also measured.

**Results:** In present study most common shape of mental foramen was round (70%). The mean distances of MF from midline are 24.36mm on right side and 24.15mm left side. From posterior border of ramus are 64.45mm on right side and 64.15mm on left side. From base of mandible are 12.29mm on right side and 12.48mm on left side. Length of base mandible (midline to angle of mandible) is 83.27mm right side and 83.12mm left side. Ratio of distance from symphysis menti to MF and length of base of mandible are same on both sides that are 0.29. There is statistically significant positive correlation between distance from symphysis menti to MF and length of base of mandible.

**Conclusions:** The MF plays a very important role in treatment planning and its location needs to be considered prior to placement of dental-implants, regional anesthesia, osteotomy-surgeries and during complete denture-fabrication in order to avoid MN injury and related complications.

This is an Open Access (OA) journal, and articles are distributed under the terms of the [Creative Commons Attribution-NonCommercial-ShareAlike 4.0 License](https://creativecommons.org/licenses/by-nc-sa/4.0/), which allows others to remix, tweak, and build upon the work non-commercially, as long as appropriate credit is given and the new creations are licensed under the identical terms.

For reprints contact: [reprint@ipinnovative.com](mailto:reprint@ipinnovative.com)

## 1. Introduction

The mandible bone is the strongest and largest bone of the human face that develops from the first pharyngeal arch. Mandible bone is a U- shaped bone consists of horizontal part body and vertical part ramus. Horizontal part has alveolar process that supports mandibular teeth. Mental foramen is present on the outer surface of mandible inferior to second premolar teeth through which mental nerve and

mental vessels emerge.<sup>1</sup>

About 6<sup>th</sup> week in utero one center of ossification appear in each half of mandible near mental foramen in the mesenchymal sheath of Meckel's cartilage near the future mental foramen. In neonate body of mandible is mere a shell, each half enclosing deciduous teeth. At this stage mandibular canal is near lower border of body and mental foramen located below the first deciduous molar and directed forward. With the development of chin and eruption of teeth direction of mental foramen alters and it is directed backwards. Elongation of the body of mandible occurs mainly on the posterior to the mental foramen and

\* Corresponding author.

E-mail address: [bhadreshpvaghela1985@gmail.com](mailto:bhadreshpvaghela1985@gmail.com) (B. P. Vaghela).

increase in the height of mandible is achieved by formation of alveolar bone and deposition of bone on the lower border. So with development the foramen and canal gradually shift upwards. In adults, the mental foramen lie mid way between the upper and lower borders of the body. In edentulous mandible the alveolar border is resorbed so the mental foramen and the mandibular canal are close to the alveolar border or sometimes inferior alveolar nerve lies beneath the oral mucosa.<sup>1,2</sup>

The mental foramen transmits mental nerve, artery and vein. Mental nerve is a terminal sensory branch of the inferior alveolar nerve which receives sensation from lower lip, buccal vestibule and gingiva mesial to the first mandibular molar.

Mental foramen is an important anatomical landmark. Knowledge of the orientation and position of it facilitate local anesthetic, surgical and other invasive procedures for oral and maxillofacial surgeries.<sup>3</sup>

During radiographic examination the foramen may be misdiagnosed as a radiolucent lesion in the apical area of the mandibular premolar teeth. So identification of accurate anatomical position of mental foramen is very important in periodontal surgery especially during flap surgery in lower teeth, retrograde amalgam fillings, apical curettage of mandibular premolars.

Accurate location of mental foramen will facilitate the administration of local anesthesia of the terminal incisive branches of the inferior alveolar and mental nerves. Many studies and textbooks describe the location of the mental foramen as being below the apex of the second premolar or between the apices of the first and second premolar but in edentulous mandible it become difficult to locate the position of mental foramen.

## 2. Material and Methods

Present study 60 dried edentulous mandibles of unknown sex were selected for the study. Damaged and broken and congenitally malformed mandible were excluded. Shape of mental foramina were macroscopically observed and noted. Various measurements were taken on both side using digital vernier caliper.

1. Distance between anterior margin of mental foramen and mid line (symphysis menti) (D1)
2. Distance between lower margin of mental foramen and lower border of base of mandible (D2)
3. Distance between anterior margin of mental foramen and posterior border of ramus of mandible (D3)
4. Length of lower border of mandible from symphysis menti to angle of mandible (L)
5. Ratio (R) of Distance between anterior margin of mental foramen and mid line (symphysis menti) and Length of lower border of mandible from symphysis menti to angle of mandible was calculated on both

sides.

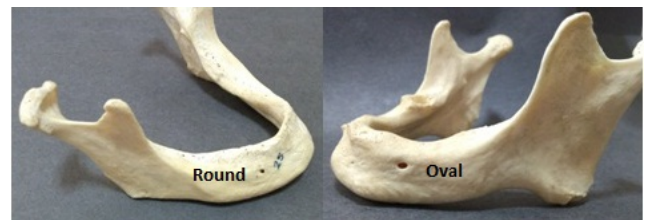


Fig. 1:

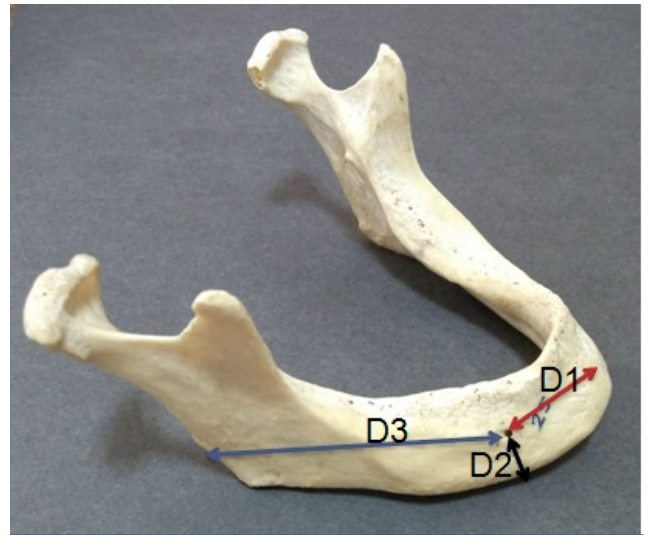


Fig. 2:

## 3. Results

Out of 60 mandible 18 mental foramina on right and 18 on left side were oval in shape rest were round. Most common shape of mental foramen was round (70%).

Correlation between distance of MF from symphysis menti and length of mandible and its analysis shows significant positive correlation.

The mental foramen usually found on the anterolateral surface of the mandible which is a single circular or oval opening lies 13-15 mm superior to the inferior border of the body of mandible.<sup>4</sup> In most cases mental foramen is the interval between the two premolars and the apex of second premolar is the another most common site.<sup>5</sup> In our study, the distance from inferior margin of mental foramen and the lower border of mandible is 12.28 mm on right side and 12.49 mm on left side in edentulous human mandibles comparatively less than the study done by Srinivas Moogala et al.<sup>6</sup> The study done in Korean population by Chung et al.<sup>7</sup> reported that the average distance between the inferior border of the mandible and the center of mental foramen was 15.5 mm in males and 14.0 mm in females.

**Table 1:** Shows no significant difference in various measurements on right and left side

S. No.	Parameters	Side	Mean (mm)	SD	P value	T test
1.	Distance between MF and symphysis menti	Right	24.35	1.82	0.05	0.560
		Left	24.14	2.17		
2.	Distance between MF and base of mandible	Right	12.28	1.82	> 0.05	0.567
		Left	12.49	1.84		
3.	Distance between MF and posterior border of ramus of mandible	Right	64.44	5.23	0.05	0.374
		Left	64.26	4.58		
4.	Base length of mandible	Right	83.25	5.38	> 0.05	0.156
		Left	83.13	4.94		

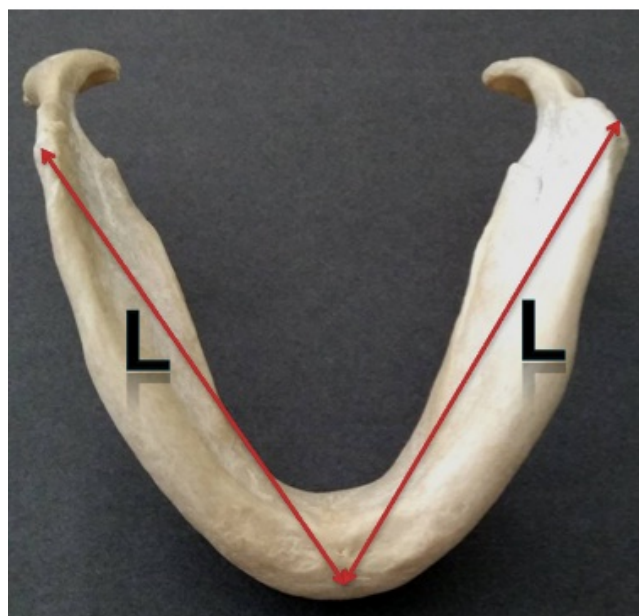
**Table 2:** Ratio of distance between anterior margin of mental foramen from mid line and length of lower border of mandible from symphysis menti to angle of mandible

Observation	Right	Left
Mean	0.29	0.29
SD	0.021	0.022
P value		0.05
t test value		0.555

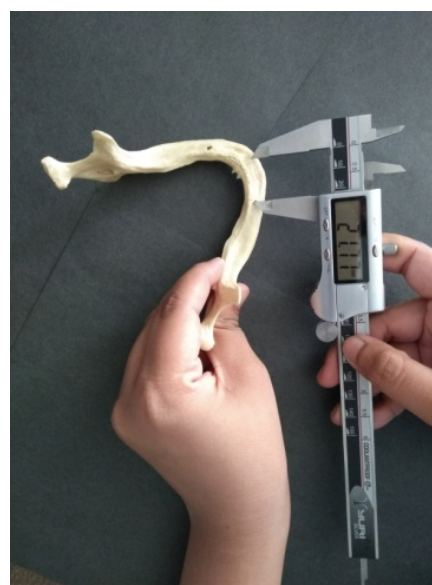Mean value on both side are same 0.29.

**Table 3:** Comparison of measurements with previous studies

Researchers	D1 Right	D1 left	D2 Right	D2 left	D3 Right	D3 Left
Srinivas Moogala et al.	28.51±4.53	27.99±4.50	13.56±4.04	13.40±4.00	68.39±6.42	68.81±6.55
V Budhiraja et al. Dentulous mandible <sup>8</sup>	25.39	25.29			65.76	66.13
Qiufei Xie et al.			15.3 male 13.2 female			
Teen Meei Wang et al. dentulous mandible	28.12±1.86	27.99±1.86	14.68±1.78	14.71±1.77		
Present study	24.36	24.15	12.29	12.48	64.45	64.25



**Fig. 3:**



**Fig. 4:**

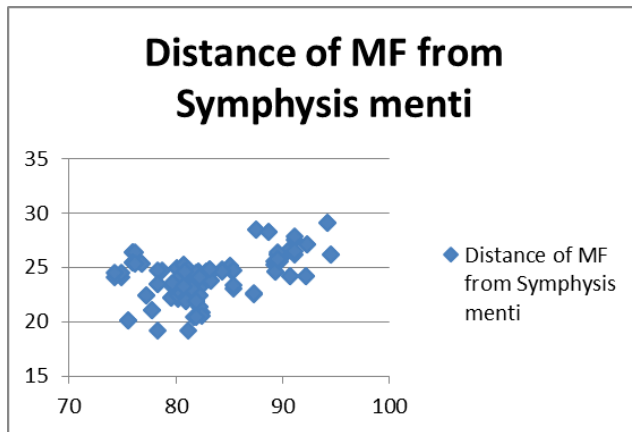


Fig. 5:

In edentulous human mandible location of mental foramina will depend upon the degree of bone resorption. The position of mental foramen moves towards the upper border of mandible and in severe cases alveolar nerves and vessels exposed out of the bone and it lies just deep to the oral mucosa that sometimes causes pain to who wears denture.<sup>9</sup>

Commonly there is single mental foramen on right and left side. In our study, any accessory mental foramen was not found. In most studies accessory mental foramen is a rare anatomical variation.<sup>6,9–14</sup> Having a knowledge of accessory mental foramen for clinicians is important to prevent neurovascular complications, while doing surgical procedures, during dental implant surgery and any other surgical procedure involving the molar and premolar region.

In our study, the distance from most anterior margin of mental foramen to posterior border of ramus of the mandible (D3) on right side it is  $64.44 \pm 5.23$  mm and left side it is  $64.26 \pm 4.58$  mm which found less than the studies conducted by Srinivas Moogala et al.<sup>6</sup> and Shankar et al.<sup>14</sup>

In study done by Mraiwa et al.<sup>15</sup> showed that in dentate mandibles the MF was commonly located at a half way distance from the alveolar crest to the inferior border of mandible. The alveolar bone resorption after teeth loss, transposes the MF closer to the alveolar crest and in extreme situations the foramen might be found on the crest of the alveolar ridge. Study done by Srinivas Moogala et al.<sup>6</sup> conclude that in dentate and edentulous human mandibles the distance from symphysis menti to the most anterior margin of mental foramen nearly same. While study by Qiufei Xie et al.<sup>16</sup> summarizes no significant reduction in the average distance between the lower most point of the mandibular canal and the lower border of mandible in the edentulous human.

In our study, we found significant positive correlation in distance between mental foramen and symphysis menti, and between length of mandible. Obtained data can be used to locate the vertical plane of possible location of mental

foramen.

In clinics dental surgeons should be aware of the possibility of variation found in abnormal location of MF in the mental area in order to prevent the injury to the MN and adjacent blood vessels and the resulting postoperative sensory complication of the teeth and surrounding skin and mucosa during various dental surgery like genioplasty, vestibuloplasty and dental implantation. To have a safety zone of 2mm must be there between coronal aspect of nerve and implant to avoid mental nerve injury in surgery nearby mental foramina.

#### 4. Conclusion

The location of the mental foramen needs to be considered before any surgical procedures in this region to avoid mental nerve injury during surgery. The position of the foramen is altered in edentulous mandibles compared with the dentate ones. The MF location is directly affected by dental status. Evaluation of the status of the alveolar ridge in edentulous mandibles is very important during the process of construction of removable dentures and dental implants placement. The morphology of edentulous mandibles increases the risk of intraoperative complications at the anterior mandible.

#### 5. Limitation of the Study

Small sample size and gender differences were not studied.

#### 6. Source of Funding

None.

#### 7. Conflicts of Interest

None.


#### References

1. Standring S, Gray. The anatomical basis of clinical practice. In: Gray's Anatomy. USA: Churchill Livingstone: Elsevier Health Sciences; 2008. p. 532–33.
2. Moore KL, Dalley A, Agur A. Moore clinical oriented anatomy. 7th ed. Wolters Kluwer Lippincott Williams & Wilkins; 2014. p. 840–1.
3. Wang TM, Shih C, Liu C, Kuo KJ. A clinical and anatomical study of the location of the mental foramen in adult Chinese mandibles. *Acta Anat (Basel)*. 1986;126:29–33.
4. Haghani S, Rokouei M. Radiographic evaluation of the mental foramen in a selected Iranian population. *Indian J Dent Res*. 2009;20:150–2.
5. Moiseiwitsch JR. Position of the mental foramen in a North American white population. *Oral Sur Oral Med Oral Path Oral Radio Endod*. 1998;85:457–60.
6. Moogala SSS, Boyapati R, Devulapalli NS, Chakrapani S, Kolaparthi L. Anthropometrics of mental foramen in dry dentate and edentulous mandibles in Coastal Andhra population of Andhra Pradesh State. *J Indian Soc Periodontol*. 2014;18(4):497.
7. Chung MS, Kim HJ, Kang HS, Chung IH. Locational relationship of the supraorbital notch or foramen and infra orbital and mental foramina in Koreans. *Acta Anat (Basel)*. 1995;154:162–6.

8. Budhiraja V, Rastogi R, Lalwani R, Goel P, Bose SC. Study of position, shape, and size of mental foramen utilizing various parameters in dry adult human mandibles from north India. *ISRN Anat.* 2012;doi:10.5402/2013/961429.
9. Gershenson A, Nathan H, Luchansky E. Mental foramen and mental nerve: Changes with age. *Acta Anat (Basel)*. 1986;126:21–8.
10. Balcioglu HA, Kocaelli H. Accessory mental foramen. *North Am J Med Sci.* 2009;1:314–5.
11. Singh SK, Gopinathan K, Bhall U, Chhabra S. Variations in the position and number of mental foramen in mandibles of North Indian population. *J Anat Soc India.* 1992;41:47–51.
12. Zagafos J, Mutzuri A. Incidence of double mental foramina in a sample of Greek population. *J Odontostomatol.* 1989;43:521–3.
13. Mbajorgu EE, Mawera G, Asala SA, Zivanovic S. Position of the mental foramen in adult black Zimbabwean mandibles: A clinical anatomical study. *Cent Afr J Med.* 1998;44:24–30.
14. Sankar DK, Bhanu SP, Susan PJ. Morphometrical and morphological study of mental foramen in dry dentulous mandibles of South Andhra population of India. *Indian J Dent Res.* 2011;22:542–6.
15. Mraiwa N, Jacobs R, Steenberghe DV. Clinical assessment and surgical implications of anatomic challenges in the anterior mandible. *Clin Implant Dent Relat Res.* 2003;5(4):219–25.
16. Xie Q, Wolf J, Soikkonen K, Ainamo A. Height of mandibular basal bone in dentate and edentulous subjects. *Acta Odontol Scand.* 1996;54:379–83.

### Author biography

**Boski Gupta**, Consultant

**Bhadreshkumar P Vaghela**, Associate Professor  
 <https://orcid.org/0000-0002-2467-4152>

**Sudarshan Gupta**, Associate Professor

**Cite this article:** Gupta B, Vaghela BP, Gupta S. Topography of the location of mental foramen in dried edentulous human mandible and its clinical implication. *Indian J Clin Anat Physiol* 2021;8(4):320-324.