

Study of surgical landmarks of mandibular foramen for inferior alveolar nerve block: An Osteological study

Qudusia Sultana^{1,*}, Shariff M.H², Ramakrishna Avadhani³

¹Assistant Professor, ³Professor, Dept. of Anatomy, ²Associate Professor, Dept. of Pathology, Yenepoya Medical College, Mangalore – 575018, Karnataka, India.

*Corresponding author:

E-mail: qudsia.shariff@yahoo.co.in

Abstract

Background: Local Anaesthesia to inferior alveolar nerve is one of the most common procedures done by surgeons for various treatments and to make it more effective the anaesthetic agent has to be infiltrated closer to mandibular foramen. Unluckily the success rate of inferior alveolar nerve block is very less due to inaccurate localization of the mandibular foramen leading to improper placement of the needle.

Objective: The present study has been carried out on dry mandibles to determine the accurate position of mandibular foramen from various landmarks of mandible to provide with the suitable data to help the surgeons to locate the Mandibular foramen with more precision for successful Inferior Alveolar Nerve block.

Materials and Methods: This study was carried out in department of anatomy, Yenepoya medical college. A total of 100 dry mandibles were studied on its both sides to locate the mandibular foramen using digital Vernier calipers.

Results: The Mean and standard deviation values on right and left sides of the mandibles to locate the mandibular foramen from its anterior border are 17.69(±2.70), 17.94(±2.73), posterior border 11.39(±1.93), 11.40(±2.01), Mandibular notch 22.90(±3.57), 22.39(±3.18), angle of Mandible 23.87(±4.52), 23.66(±4.36) and 3M-third molar to mandibular foramen 17.9(±3.57), 17.6(±3.77) respectively.

Conclusion: The comprehension of the Mandibular foramen is of a considerable importance for inferior alveolar nerve anesthesia, dento alveolar surgeries, endodontic treatments and lesions diagnosis. Its precise location enables a more effective anesthesia. Incorrect estimations of its location might be the reason for the unsuccessful anesthesia of the inferior alveolar nerve and damage of neurovascular structures passing through it.

Keywords: Local anaesthesia, Inferior alveolar nerve, Mandibular foramen, localization, dentoalveolar surgeries.

Access this article online	
Quick Response Code:	Website: www.innovativepublication.com
	DOI: 10.5958/2394-2126.2016.00011.6

Introduction

The irregular mandibular foramen is seen little above the centre on the medial surface of the ramus of the mandible curving downwards and forward in the body as mandibular canal till it opens as mental foramen.¹ The inferior alveolar vessels and nerves passes through the mandibular foramen and canal to supply mandibular teeth and comes out through the mental foramen as mental vessels and nerves.²

Local Anesthesia to inferior alveolar nerve is one of the frequent procedures done by surgeons for various dental treatments. To make inferior nerve block more effective the anesthetic agent has to be infiltrated closer to the mandibular foramen. ³Unluckily the success rate of inferior alveolar nerve block is very less due to two reasons; firstly inaccurate localization of the mandibular foramen leading to improper placement of the needle⁴ and secondly the Presence of accessory mandibular foramina's other than alveolar sockets,

mandibular, mental and lingual foramina in the mandible⁵ which indicates the presence of additional branches of inferior alveolar nerves or vessels and possibly is responsible for the failure of IAN block sometimes.^{6,7}

There is abundant literature present describing the anatomical structures significant in successful mandibular anesthesia, but failures are repeatedly observed in performing this procedure. Some authors have estimated the failure rate of inferior alveolar nerve blocks to be approximately 20–25. Very scarce literature is available on the exact landmark regarding the location of the mandibular foramen.^{8,9,10}

Hence this study was undertaken to determine the position of the MF from various anatomical landmarks and study the incidence of accessory MF in dry adult mandibles and provide valuable data to the dental students and surgeons dealing with inferior nerve block.

Aims and Objectives

The present study has been carried out on dry mandibles to determine the accurate position of mandibular foramen from various landmarks; anterior border of ramus, posterior border of ramus, mandibular notch, angle of mandible and from Posterior border of the socket for the third molar tooth to endow with the suitable data to help the dentists and surgeons to locate

the Mandibular foramen with more precision for successful Inferior Alveolar Nerve block.

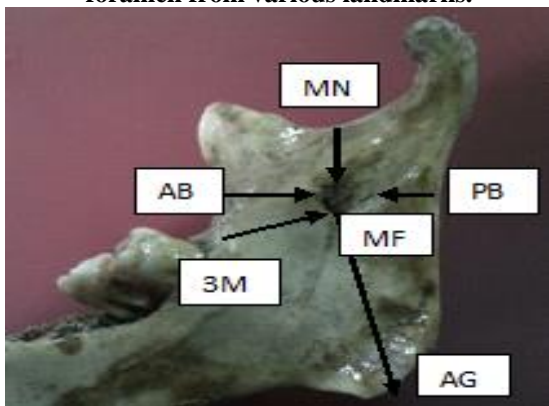
In this study we have also observed for the presence of accessory mandibular foramen on both sides of the mandible.

Materials and Methods

This study was carried out in department of anatomy, Yenepoya medical college. A total number of 100 dry mandibles were studied on its both sides for the location of mandibular foramen. Digital Vernier Calipers of 0.001mm accuracy was used for taking measurements. The measurements were taken by two different people and mean of it was taken to remove observer’s bias. Measurements were recorded to the nearest millimeter.

Inclusion criteria: mandibles with sockets for 3rd molar tooth were selected. The position of the centre of mandibular foramen was measured and recorded from various landmarks like (fig:1)

Figure 1: showing the distance of the mandibular foramen from various landmarks.



AB-MF: Nearest point on the anterior border of the ramus of mandible to the midpoint of the anterior margin of mandibular foramen.

PB-MF: Nearest point on the posterior border of the ramus of the mandible to the midpoint of the posterior margin of mandibular foramen.

MN-MF: Lowest point of the mandibular notch to the midpoint of the upper margin of mandibular foramen.

AG-MF: Farthest point on the angle of the mandible to the midpoint of the inferior margin of mandibular foramen.

3M-MF: Posterior border of the socket for the third molar tooth.

The mandibles were also observed for the presence of accessory mandibular foramen surrounding the mandibular foramen on the medial side of the ramus and noted by naked eye observation.

Observations and Results

The results of the studies are shown in table 1 and table 2. The mean distance of right and left MF from anterior border is 17.69 and 17.9 respectively. The mean distance of right and left MF from posterior border is 11.4 each. The mean distance of right and left MF from mandibular notch is 22.9 and 22.4 respectively. The mean distance of right and left MF from angle of the mandible is 23.9 and 23.7 respectively. The mean distance of right and left MF from 3rd molar is 17.9 and 17.6 respectively. These values tell us that mandibular foramen is situated almost at the same distance on both the sides.

Table 1: Showing the mean, standard deviation, maximum and minimum values of the distance measured between the mandibular foramen and the various landmarks

Measurement	SIDE	MIN(mm)	MAX(mm)	MEAN(mm)	SD
AB-MF	RIGHT	8.3	25.4	17.69	2.70
	LEFT	7.6	25.1	17.94	2.73
PB-MF	RIGHT	7.3	18.2	11.39	1.93
	LEFT	7.9	19.5	11.40	2.01
MN-MF	RIGHT	13.2	38.2	22.90	3.57
	LEFT	14.1	34.5	22.39	3.18
AG-MF	RIGHT	13.2	34.4	23.87	4.52
	LEFT	12.8	34.5	23.66	4.36
3M-MF	RIGHT	11.4	33.4	17.9	3.57
	LEFT	12.2	33.4	17.6	3.77

Table 2 shows out of 100 mandibles studied, accessory mandibular foramina were found bilaterally in 13%, unilaterally on right side in 24% and left side in 23% of bones.

Table 2: showing the accessory mandibular foramina observed.

AMF	Number	Percentage
Bilateral	13	13%
Right	24	24%
Left	23	23%

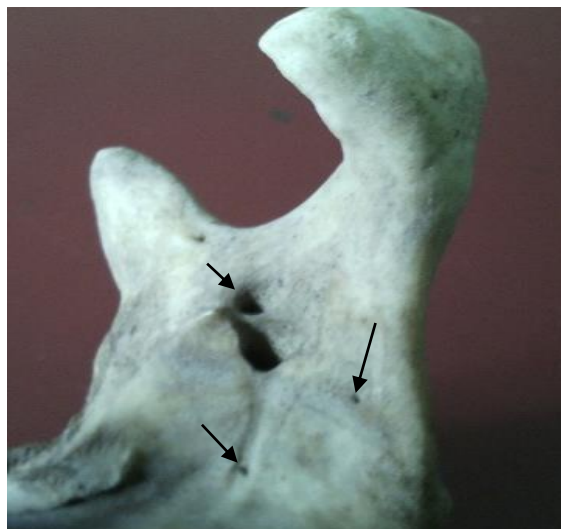


Figure 2: Showing the accessory mandibular foramen.

Discussion

The comprehension of the MF is of a considerable importance for inferior alveolar nerve anesthesia, dento alveolar surgeries, endodontic treatments and lesions diagnosis. Its precise location enables a more effective anesthesia. Incorrect estimations of its location might be the reason for the unsuccessful anesthesia of the inferior alveolar nerve.^{11,12}

One of the most common reason for the failure in the technique of inferior nerve block is due to the lack of the proximity between anaesthetic needle and mandibular foramen and thus the inaccurate localization of the structures of the mandibular foramen.^{4,13}

Post operative complications of implant surgery on mandible can damage the inferior alveolar nerve leading to sensory disturbances causing unintentional biting of tongue, lip or cheek: drooling of saliva; pain during mastication and hemorrhage of inferior alveolar artery and its branches.¹⁴

There are many anonymous accessory foramina present particularly on the lingual side of the mandible, which vary in their distribution and play a significant role in relation to the effectiveness of local anaesthetic drugs administered for dental procedures.¹⁵

The accessory mandibular foramen has gained importance among the radiotherapists while planning radiation therapy as it can give way for the spread of tumour cells following the radiotherapy. Hence the knowledge of the additional foramina is very important.¹⁶

Various parameters have been studied by various authors to locate mandibular foramen. Hayward J in 1977 conducted a study on 45 Asian skulls and 62 mixed skulls of Black and white Americans and reported that the mean size of anterior portion is greater than the posterior portion of the ramus, lingula is present on the ant part of the foramen. The mandibular foramen is located in the third quadrant anteroposteriorly. There was no right- or left-side dominance in the ramus size and position of the mandibular foramen.¹⁷ Nicholson's concluded from his studies on 80 dry bones that the position of the MF was variable which was responsible for the occasional failure in IAN Block.¹³

Some of the studies of other authors are shown in table 3. The studies conducted by authors show different values probably due to regional difference.

Table 3: Comparison of studies done on mandibular foramen by various authors.

Authors	AB-MF(mm)	PB-MF	MN-MF	AG-MF	3M-MF	AMF
Kilarkaje.et.al (2005)	R= 18.5±1.9 L= 18.5±2.0	-	R= 21.6±3.1 L= 21.6±3.4	R= 25.1±4.2 L= 24.7±4.4	25mm	
Prado.et.al (2010)	R= 19.2±3.6 L= 18.8±3.8	R= 14.2±8.4 L= 13.0±2.6	R= 23.6±3.1 L= 23.1±3.0	-		
Padmavathi (2014)	R=16.8 ± 2.8 L=16.9 ± 2.5	R= 11.7±2.0 L=12.1± 2.4	R=22.0± 3.0 L=22.3± 3.4	R=22.6 ± 3.4 L= 22.2 ± 2.9		51.5%
Present study (2015)	R= 17.69±2.7 L= 17.94±2.7	R= 11.39±1.9 L= 11.40±2.0	R= 22.90±3.5 L= 22.39±3.1	R= 23.87±4.5 L= 23.66±4.3	R= 17.9±3.5 L= 17.6±3.7	47%

A - Anterior border of ramus. B - Posterior border of ramus. C- Massetric notch. D- Angle of the mandible. E-Posterior end of socket for third molar tooth

The present study shows that the mean distance of right and left MF from anterior border is 17.69 and 17.9 respectively. The mean distance of right and left MF from posterior border is 11.4 each. The mean distance of right and left MF from mandibular notch is 22.9 and 22.4 respectively. The mean distance of right and left MF from angle of the mandible is 23.9 and 23.7 respectively. The mean distance of right and left MF from 3rd molar is 17.9 and 17.6 respectively. These values tell us that mandibular foramen is situated at bilateral symmetrical distance on both the sides. Similar results have been found with the other authors also.^{16,18,19}

The studies conducted on accessory Mandibular foramina are very few. In 2011 Murlimanju et.al conducted a study on 67 mandibles and concluded the presence of 16.4% of AMF of which 8.9% unilateral and 7.5% bilateral. In 2012 Freire et.al conducted a study on Brazilian population and reported the presence of 27.93% and 43.24% of AMF above and below the mandibular foramen. In 2013 Prajna conducted a study on 60 mandibles and said that 16.66% of the mandibles have AMF.^{20,21,6} In our study we observed 100 mandibles and found accessory mandibular foramen in 47% of the bones out of which 24% on right side, 23% on left side and 13% bilateral. This significant incidence of presence of MF explains the failure of anesthesia of inferior alveolar nerve.

Conclusion

The understanding of the landmarks for location of mandibular foramen and incidence of variations like presence of accessory mandibular foramen is of a considerable importance for the surgeons, oncologists and radiologists to perform successful inferior alveolar nerve anesthesia, dento alveolar surgeries, endodontic treatments and lesions diagnosis and prevent the damage of neurovascular structures passing through it and thus the complications occurred as a result of it.

Conflict of Interest: None

Source of Support: Nil

References:

1. Peter Williams L. et al. Grays Anatomy, 38th edition. Churchill Livingstone, 1995; 567.
2. Dutta A.K. Essentials of Human Anatomy, Head and Neck. 5th Edition, current books international.2009;42.
3. Ashkenazi, M., Taubman, L. and Gavish, A. (2011), Age-Associated Changes of the Mandibular Foramen Position in Anteroposterior Dimension and of the Mandibular Angle in Dry Human Mandibles. *Anat Rec* 2011; 294: 1319–1325.
4. Ennes JP, Medeiros RM, Grant JC. Localization of Mandibular Foramen and Clinical Implications. *Int J Morphol*. 2009; 27:1305–11.
5. Sutton JP. The practical significance of mandibular accessory foramina. *Aust Dent J*, 1974; 19:167-173.
6. Samanta PP, Kharb P. Morphometric analysis of mandibular foramen and incidence of accessory

- mandibular foramina in adult human mandibles of an Indian population. *Rev Arg De Anat Clin*, 2013; 5:60-66.
7. Poonacha K S , Shigli A L, Indushekar K R. Relative position of the mandibular foramen in different age groups of children: A radiographic study. *J Indian Soc Pedod Prev Dent* 2010; 28: 173-8.
8. Barker BC, Davies PL. The applied anatomy of the pterygomandibular space. *Br J Oral Surg*.1972; 10:43–55. [PubMed]
9. Thangavelu K, Kannan R, Kumar NS, Rethish E, Sabitha S, SayeeGanesh N. Significance of localization of mandibular foramen in an inferior alveolar nerve block. *Journal of Natural Science, Biology, and Medicine*. 2012;3(2):156-160.
10. Quinn JH. Inferior alveolar nerve block using the internal oblique ridge. *J Am Dent Assoc*.1998;129: 1147–8. [PubMed]
11. Bremer G. Measurements of special significance in connection with anesthesia of the inferior alveolar nerve. *Oral Surg Oral Med Oral Pathol*. 1952; 5:966–88.
12. Ono E, Medici FE, Moraes LC, Castilho JC, Moraes ME. Anteroposterior location of the mandibular foramen of 7 to 12 year old children in panoramic radiographs. *Braz Dent J*. 2005; 8:6–12.
13. Nicholson ML. A study of the position of the mandibular foramen in adult human mandible. *Anat Rec*.1985; 212:110–2. [PubMed]
14. Pelayo J L , Diago MP , Bowen E M , Diago M P. Intraoperative complications during oral implantology. *Med Oral Patol Oral Cir Bucal*. 2008 Apr;13 (4):E239-43.
15. Sutton RN. The practical significance of mandibular accessory foramina. *Australian Dental Journal* .1974; 19: 167-173.
16. Padmavathi G, Suman Tiwari, Varalakshmi KL, Roopashree R. An Anatomical Study of Mandibular and Accessory Mandibular Foramen in Dry Adult Human. *IOSR-JDMS*. Apr. 2014; 13(4): 83-88.
17. Hayward J, Richardson ER, Malhotra SK. The mandibular foramen: its anteroposterior position. *Oral Surg Oral Med Oral Pathol*. 1977 Dec; 44(6):837-43.
18. Prado, F.B., Groppo, F.C., Volpato, M.C. and Caria, P.H.F. Morphological changes in the position of the mandibular foramen in dentate and edentate Brazilian subjects. *Clin. Anat*.2010; 23: 394–39
19. Kilkarje N, Nayak SR, Narayan P, Prabhu LV. The location of the mandibular foramen maintains absolute bilateral symmetry in mandibles of different age groups. *Hong Kong Dent J*. 2005 :2:35-37.
20. B.V. Murlimanju, Latha V. Prabhu, M.D. Prameela, C. Mohammed Ashraf, Ashwin Krishnamurthy, C. Ganesh Kumar. ACCESSORY MANDIBULAR FORAMINA: PREVALENCE, EMBRYOLOGICAL BASIS AND SURGICAL IMPLICATIONS. *Journal of Clinical and Diagnostic Research*. 2011; 5:1137-1139.
21. Freire AR, Rossi Ac, Prado FB. Incidence of mandibular accessory foramina in Brazilian population. *J Morphol Sci*.2012; 29:171-173.