



Original Research Article

Morphological study of variations in shape of coronoid process of adult human mandible

Chandra Kiran¹, Nimisha Madhu^{1,*}, Rajendra Prasad¹, Praveen Kumar¹, Ramanuj Singh¹, Prabhat Kumar Lal²¹Dept. of Anatomy, Anugrah Narayan Magadh Medical College, Gaya, Bihar, India²Dept. of PSM, Darbhanga Medical College, Darbhanga, Bihar, India

ARTICLE INFO

Article history:

Received 13-05-2021

Accepted 29-03-2021

Available online 06-07-2021

Keywords:

Coronoid process

Cross-sectional study

Mandible

ABSTRACT

Background: Many researchers have studied the morphology of coronoid process and have found varying shapes but such a study is lacking in this area.**Aims:** The present study was conducted to identify different morphological variations in shape of coronoid process of adult human mandible.**Materials and Methods:** The present cross-sectional study was conducted in the department of Anatomy at a Medical College of Bihar upon 46 dry adult human mandibles i.e. 92 coronoid processes. The morphological forms of coronoid process were noted.**Results:** 57.6% of coronoid processes were triangular in shape, 28.3% were rounded and 14.1% were hook shaped. The difference between male and female mandibles was found to be statistically significant ($p=0.004$).**Conclusion:** The proper knowledge on the morphological shapes of coronoid process is useful for maxillofacial surgeons as well as to be used as an anthropological marker to assess different populations and races.© This is an open access article distributed under the terms of the Creative Commons Attribution License (<https://creativecommons.org/licenses/by/4.0/>) which permits unrestricted use, distribution, and reproduction in any medium, provided the original author and source are credited.

1. Introduction

Among the facial bones, mandible is the largest bone. Its body is horizontally curved with forward convexity. The two rami ascend posteriorly and have the coronoid and condyloid processes. The coronoid process of the mandible is a triangular plate of bone which projects upward and slightly forward. The temporalis muscle is attached to its margins and medial surface.¹

Being a membranous bone, it can easily be removed intraorally without any functional deficiency and facial disfigurement. This is needed for reconstruction of orbital floor deformities, alveolar defects, paranasal sinus augmentation, non-union fractures of mandible, osseous defect reconstruction, and other repairing procedures in craniomaxillofacial surgeries.²

* Corresponding author.

E-mail address: nimishamadhu@yahoo.in (N. Madhu).

Many researchers have studied the morphology of coronoid process and have found varying shapes.^{3–13} Similar study has not been done in this area. Hence, this study was conducted which will be useful to maxillofacial surgeons, forensic scientists and anthropologists.

2. Aims & Objectives

The present study was conducted to identify different morphological variations in shape of coronoid process of adult human mandible.

3. Material and Methods

3.1. Study setting

The present cross-sectional study was conducted in the department of Anatomy at a medical college of Bihar.

3.2. Study samples

The present study was conducted upon 46 dry adult human mandibles. Thus, a total of 92 coronoid processes were studied. Intact adult human mandibles available in the department were included. The mandibles which were damaged were excluded from the study.

3.3. Data collection procedure

The morphological analysis of mandibles were done to note the details of coronoid processes of both sides. Metric and nonmetric analysis were used for determination of sex of the mandible. Chin shape, gonial eversion, bigonial and bicondylar width and flexion on the posterior surface of mandible were considered for the same.

The morphological forms of coronoid process were noted. If the apex pointed straight upwards with straight anterior and posterior border, it was considered to be triangular. If the apex was blunt with straight anterior and posterior border, it was rounded. If the tip was pointing in backward direction with convex anterior and convex posterior border, it was taken as hook-shaped.

3.4. Data analysis

Data was entered in Microsoft Excel and analyzed using SPSS v 20. Percentage and proportions were used for summarization of the data. p -value <0.05 was considered as statistically significant.

4. Results

The present study included a total of 92 coronoid processes of both sides from 46 mandibles. 62 of these (67.4%, 31 mandibles) were of males and 30 (32.6%, 15 mandibles) were of females.

Table 1 shows the shapes of coronoid processes. 57.6% of these were triangular in shape, 28.3% were rounded and 14.1% were hook shaped. Among the mandibles of males, 69.4% were triangular in shape, 19.4% were rounded and 11.3% were hook shaped. Among the mandibles of females, 33.3% were triangular in shape, 46.7% were rounded and 20% were hook shaped. The difference between male and female mandibles was found to be statistically significant ($p=0.004$).

5. Discussion

The present study upon 92 coronoid processes of 46 mandibles revealed that 57.6% were triangular in shape, 28.3% were rounded and 14.1% were hook shaped. Rounded shape was more common in females. The difference between male and female mandibles was found to be statistically significant ($p=0.004$).

Quadri et al. (2016) observed that overall triangular type of coronoid process (67%) was more prevalent than

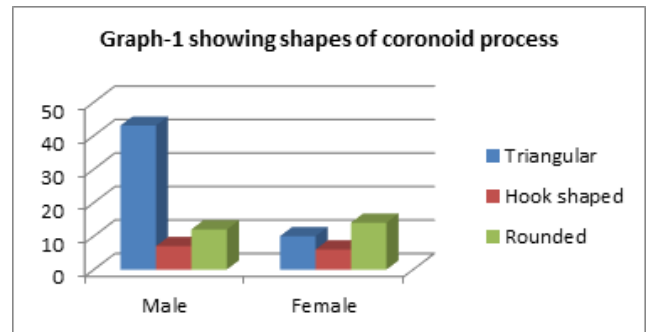


Fig. 1: Showing round shaped coronoid process

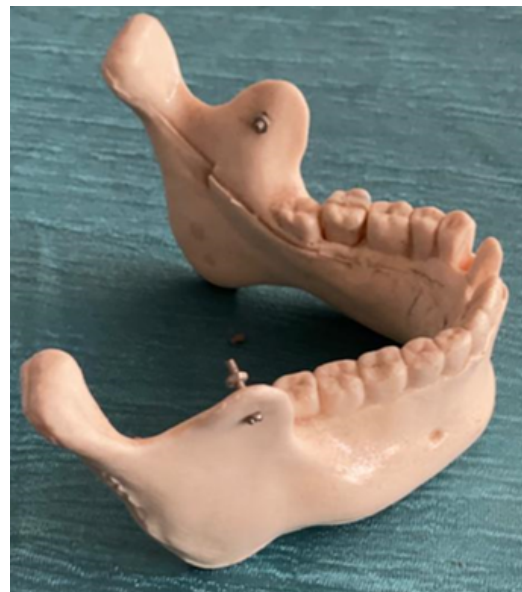

Fig. 2: Showing round shaped coronoid process

hook shape (30%) and rounded (3%). Triangular type was more prevalent in males (72.2%) than females (51.1%), whereas hook shape was more prevalent in females (44.9%) than males (25.2%). Rounded shape was more prevalent in females (4.1%) than males (2.6%).³

Sheela et al. (2015) reported that triangular shape coronoid process was found in 64.97%, hook shape in 21.02% sides and rounded in 14.01% sides of mandibles. Mean intercoronoid distance among males was found to be 9.2000 and 9.100 in females.⁴

Sudha et al. also found that shapes of coronoid process were triangular (60.8%), rounded (14%) and hook (25.6%) in their study. Hook shape was found bilaterally in 28.8%. In edentulous bone, hook type of coronoid process was found in 53.3% and there was no incidence of rounded type bilaterally.⁵

Sahithi et al. conducted a study of 200 digital OPG images, corresponding to 400 sides among which, 84 (168 sides) were of males and 116 (232 sides) were females. The

Table 1: Showing the shapes of coronoid processes

Sex	Triangular	Hook shaped	Rounded	Significance
Male (n=62)	43 (69.4%)	7 (11.3%)	12 (19.4%)	$\chi^2=10.97$ p= 0.004
Female (n=30)	10 (33.3%)	6 (20%)	14 (46.7%)	
Total (n=92)	53 (57.6%)	13 (14.1%)	26 (28.3%)	

most common shape for coronoid process was observed as triangular (215) which was distributed as 105(48.8%) on the right side and 110 (51.2%) on the left side. The next shape was found to be the round (143), of which 75 (52.4%) were on the right side and 68 (47.6%) were on the left side followed by the beak shape (34), of which 16 (47.1%) were on the right side and 18 (52.9%) on the left side. The least common shape observed for the coronoid process was flat (8), which was equally distributed on both sides. The distribution of the shapes of the coronoid process among the right and left sides had shown no statistical significance (p value = 0.90).⁶

6. Conclusion

Morphological variations of anatomic structures result from either due the developmental discrepancies through hereditary determinants or due to the functional variations that arise during the growth process.⁶

The proper knowledge on the morphological shapes of coronoid process is useful for maxillofacial surgeons as it is used in reconstructions of orbital floor deformities, oromaxilla facial defects, and paranasal augmentation. Along with the other features of the skull, these could be used as an anthropological marker to assess different populations and races.

7. Source of Funding

None.

8. Conflict of Interest

The authors declare that there is no conflict of interest.

References

1. Standing S, Collins P, Healy JC, Wigley C, Beale TJ. Mandible: Infratemporal and Pterygopalatine fossae and temporomandibular joint. In: Gray's anatomy: The anatomical basis of clinical Practice. New York; Churchill Livingstone: Elsevier; 2008. p. 530–2.
2. Mintz SM, Ettinger A, Schmackel T, Gleason MJ. Contralateral coronoid process bone grafts for orbital floor reconstruction: An anatomic and clinical study. *J Oral Maxillofac Surg.* 1998;56(10):1140–4. doi:10.1016/s0278-2391(98)90755-8.
3. Quadri A, Ahmed HST. Variations in shape of Mandibular Coronoid Process in 200 South Indian Subjects. *Int J Sci Study.* 2016;4(7):159–61.
4. Kadam SD, Priya P, Roy AMP, Doshi MA. Variation in the shape of coronoid process in dry mandible of Maharashtra population. *Int J Anat Res.* 2015;3(1):895–8.
5. Sudha R, Chandrasekaran S, Aruna N. Study of morphological variations in the shapes of coronoid process of mandible in South Indian population. *IJCRR.* 2013;5:84–92.
6. Sahithi D, Reddy S, Teja DV, Koneru J, Praveen KN. Reveal the concealed – Morphological variations of the coronoid process, condyle and sigmoid notch in personal identification. *Egypt J Forensic Sci.* 2016;6(2):108–13.
7. Nirmale VK, Mane UW, Sukre SB, Diwan CV. Morphological Features of Human Mandible. *Int J Recent Trends Sci Technol.* 2012;3(2):38–43.
8. Prajapati VP, Malukar O, Nagar SK. Variations in the Morphological Appearance of the Coronoid Process of Human Mandible. *Nat J Med Res.* 2011;1(2):64–6.
9. Shakya S, Nagraj SK. Morphology of Coronoid Process and Sigmoid Notch in Orthopantomograms of South Indian Population. *World J Dent.* 2013;4(1):1–3. doi:10.5005/jp-journals-10015-1193.
10. Priya R, Manjunath KY, Balasubramanyam. Thevarying shape of the coronoid process of the mandible. *Indian J Dent Res.* 2004;15(3):96–8.
11. Pradhan S, Bara DP, Patra S, Nayak S, Mohapatra C. Anatomical Study of Various Shapes of Mandibular Coronoid Process in Relation to Gender & Age. *IOSR J Dent Med Sci.* 2014;13(8):09–14. doi:10.9790/0853-13820914.
12. Tapas S. Morphological variations of coronoid process in dry adult humanmandibles. *Indian J Basic Appl Med Res.* 2014;3:401–5.
13. Bhabhor P, Katariya B, Shrimankar P. Variations in the shape of coronoid process in the adul thuman Mandible. *Int J Res Med.* 2015;4(4):87–9.

Author biography

Chandra Kiran, Tutor

Nimisha Madhu, Tutor

Rajendra Prasad, Professor and Head

Praveen Kumar, Tutor

Ramanuj Singh, Assistant Professor

Prabhat Kumar Lal, Associate Professor

Cite this article: Kiran C, Madhu N, Prasad R, Kumar P, Singh R, Lal PK. Morphological study of variations in shape of coronoid process of adult human mandible. *Indian J Clin Anat Physiol* 2021;8(2):116-118.